



# COMPREHENSIVE CASE PRESENTATION

Presented by:

Ibrahim Alzwia

---

***This work was achieved by the student: Ibrahim Alzwia under the supervision of dental teaching staff at Libyan International Medical University:***

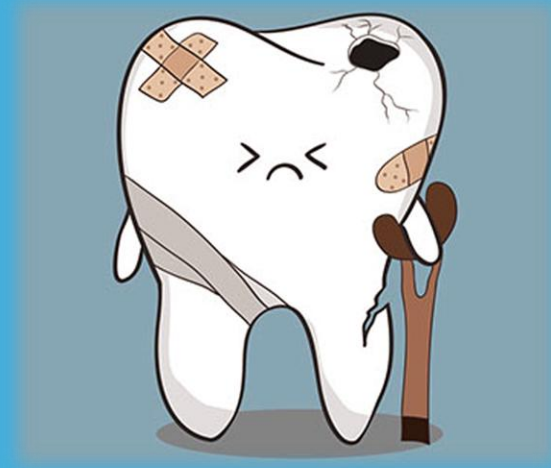- Rafeeq M. Al Kuafi
- Abdelmonem A. Abdelnabi
- Ali Busnaina
- Sara Elkelani
- Marowa Elshreksiy
- Mohammed aljatlawi
- Omar A. Huni
- Nada Kashbor
- Randa Elhasy
- Rabie elhoni
- Abdelsalam Elhadad

## *Patient details*

- Name: F.S.A
- DOB: 3-3-1981
- Occupation: Teacher
- Nationality: Libyan
- Sex: Female
- Address: El waheshe

# Chief complaint

- Pain at upper left area since 1 month



# ***History of chief complaint***

- **Moderate sharp pain stimulated by hot, cold and Sweet, Relived by removal of stimulus “last for moment” No sleep disturbance, no use of analgesics, no associated phenomena, radiated to the full mouth, no history of dental treatment**
- **Patient mentioned that she had swelling in same area from 2 months and lasted for two weeks with use of antibiotic, sudden onset, no pus discharge, No recurrence, no associated phenomena**

---

➤ **Medical history :**

*Hernia*

➤ **Allergic history :**

*NOS*

➤ **Dental history :**

*Last visit 10ys Extraction , scaling , filling without any complication*

➤ **Family history :**

*Parents diabetic*

➤ **Social history :**

*Married and mother to 4 children's*

---

“

# Oral hygiene practice

- **Brushing :**  
*once a week*
- **Brushing method :**  
*Horizontal*
- **Kind of Dentifrice used :**  
*Signal*
- **Any other oro physiotherapeutic Aids :**  
*Non*

---

“

*Clinical Examination*

---



# *Extra-oral examinations*

➤ **Facial symmetry :**

*Symmetrical*

➤ **Skin:**

*Fair skin color*

➤ **TMJ status:**

*Examination reveals no clicking, crepitation, limitation or deviation of mouth opening, with no masticatory muscles tenderness*

➤ **Lymph nodes:**

*not palpable , neither tender .*

# ***Intra Oral Examination***

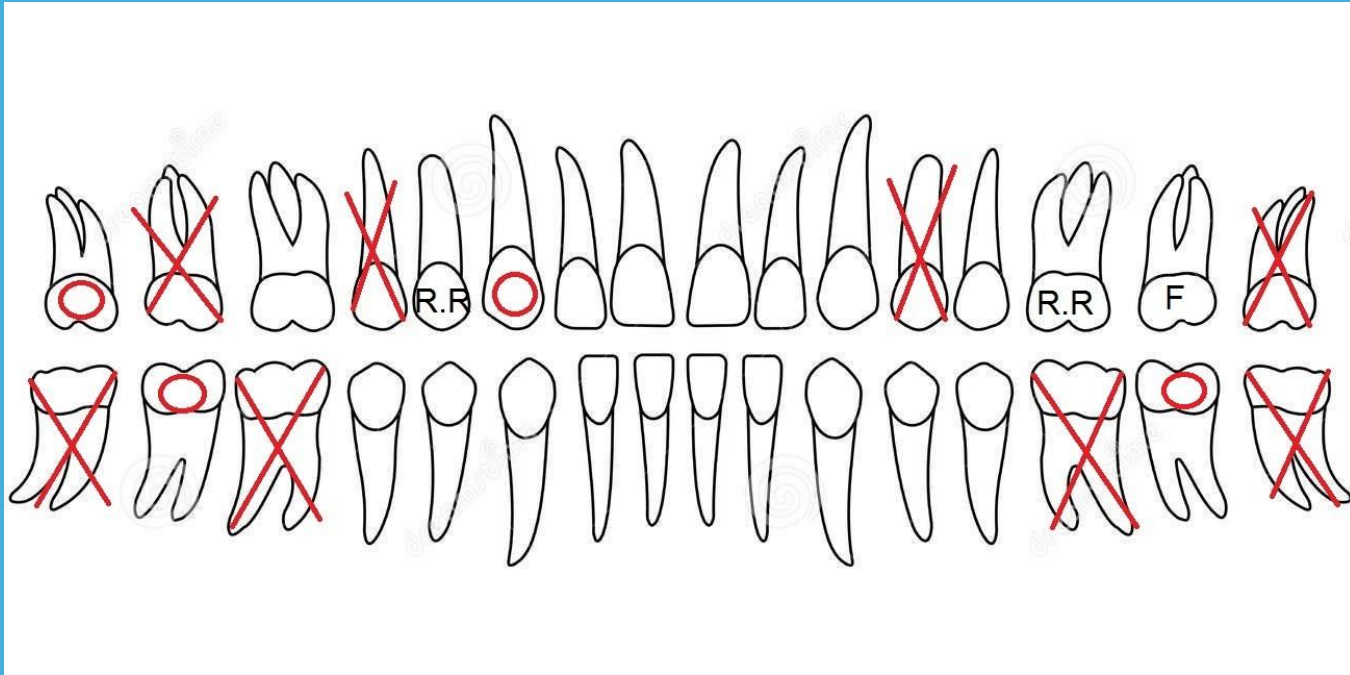
➤ ***Soft tissue:***

***Palate:*** Normal

***Tongue:*** Normal

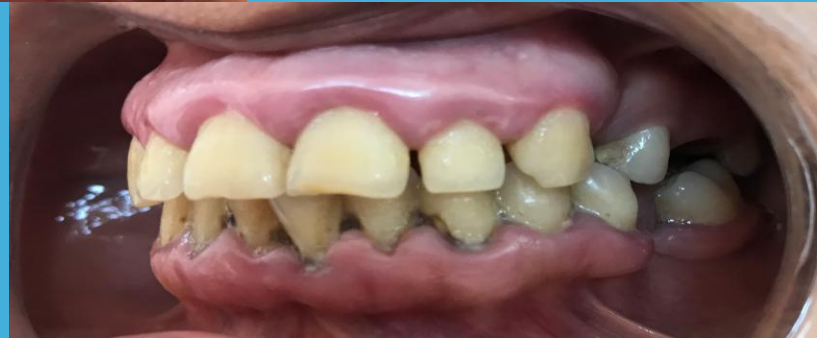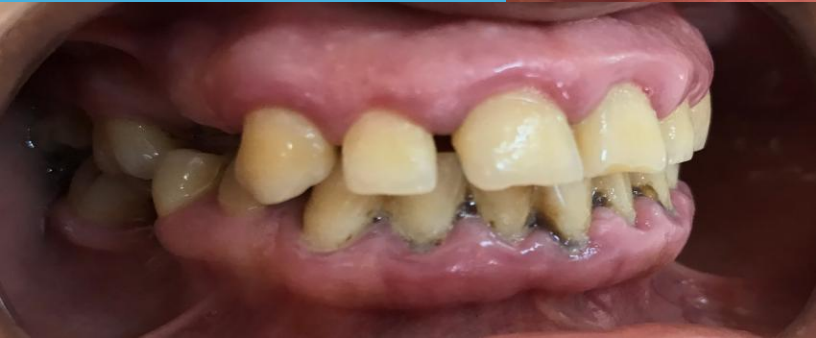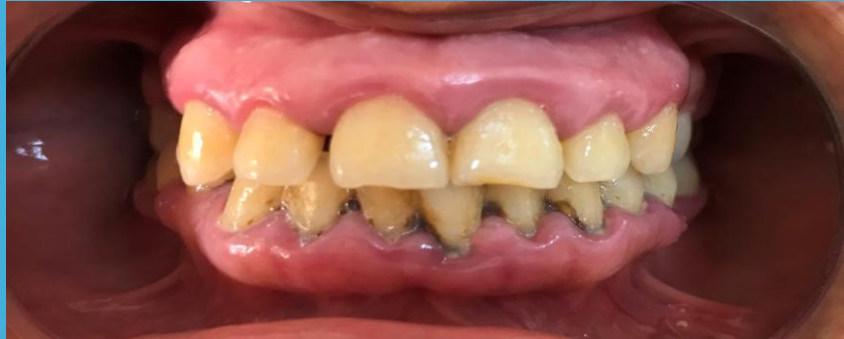***Mucosa :*** Normal

# Dental chart



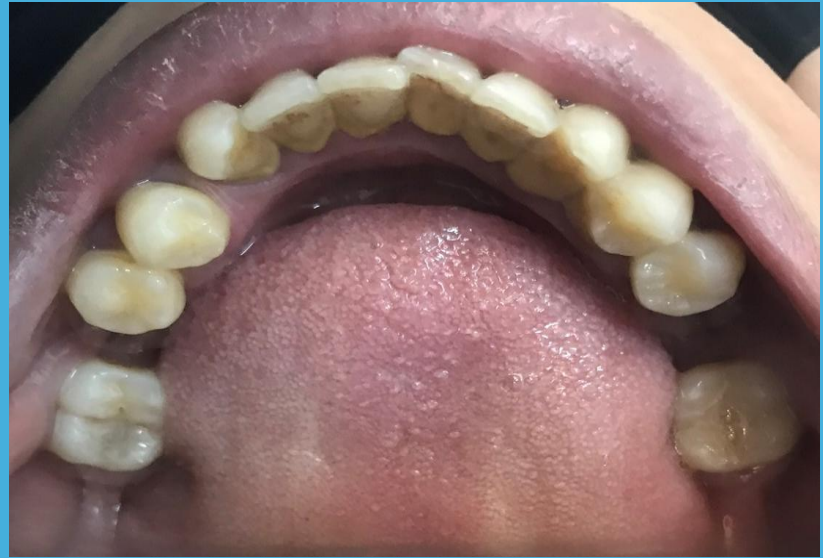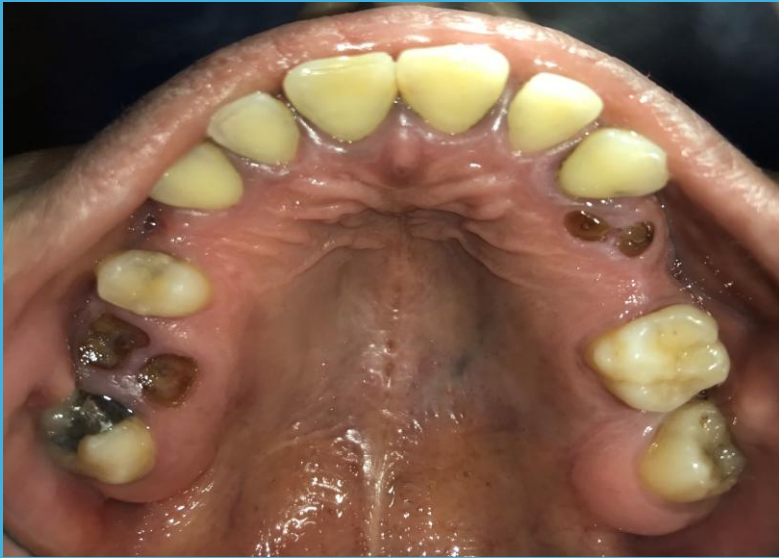# *Intraoral examination*

➤ *Hard tissue examination*



# *Intraoral examination*

➤ *Hard tissue examination*



# *Gingival status*

	Right	Anterior	Left
Color	Reddish pink	Reddish pink	Reddish pink
contour	Scalloped round margin blunt IDP	Scalloped round margin blunt IDP	Scalloped round margin blunt IDP
Size	Enlarged	Enlarged	Enlarged
consistency	Soft + edematous	Soft + edematous	Soft + edematous
Stippling	Present	Absent	Present
Position	Coronal to CEJ in max  <i>Apical to CEJ in man</i>	Coronal to CEJ in max  <i>Apical to CEJ in man</i>	Coronal to CEJ in max  <i>Apical to CEJ in man</i>
Bleeding on probing	<i>Present</i>	<i>Present</i>	<i>Present</i>
Exudation	Absent	Absent	Absent

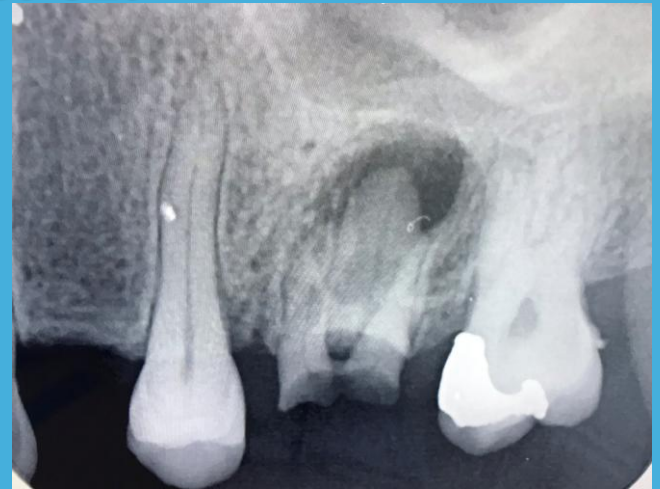# *Periodontal status*

- *There's CAL in upper arch about 3-6mm*
- *And CAL in lower arch about 3-6mm*
- *No mobility*
- *No furcation involvement*
- *OHI-S was fair*

# *Differential diagnosis :*

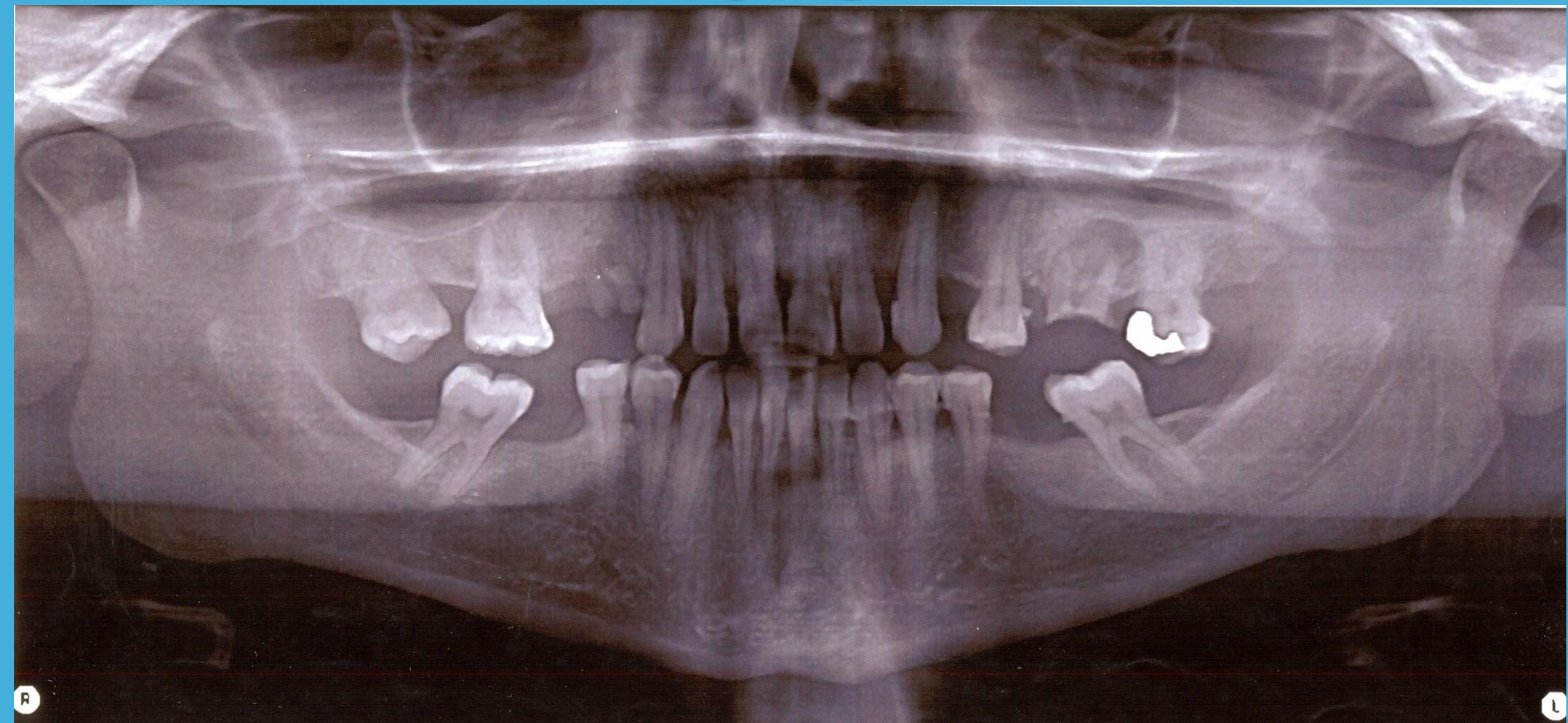
- *1) chronic periapical periodontitis UL6*
- *2) Reversible pulpitis UL6*
- *3) Acute exacerbation of preapical abscess UL6*
- *3) chronic granuloma UL6*

## *Investigation*





# OPG



# ***FINAL DIAGNOSIS***

- 1) Chronic periapical granuloma UL6***
- 2) Reversible pulpitis UL7***
- 3) Dental caries UR3 UR8 LR7 LL7***
- 4) Generalized moderate to severe chronic periodontitis***
- 5) R.R UR4***
- 6) Missed teeth UR5 UR7 UL4 UL8 LR6 LR8 LL6 LL8***
- 7) Kennedy class III modification 2 (Maxillary arch)***
- 8) Kennedy class III modification 1 (Mandibular arch)***

## ***Emergency phase***

- ***Extraction UL6***

## ***Phase 1***

- ***Patient motivation and education***
- ***OHI***
- ***Scaling and root planning***

***Perio maintenance***

***Surgery***

## ***Phase 2***

- ***Extraction UR4***
- ***Gingivectomy***

## ***Phase 3***

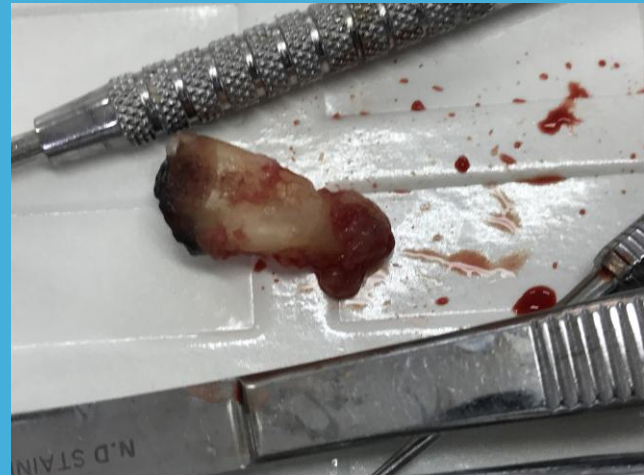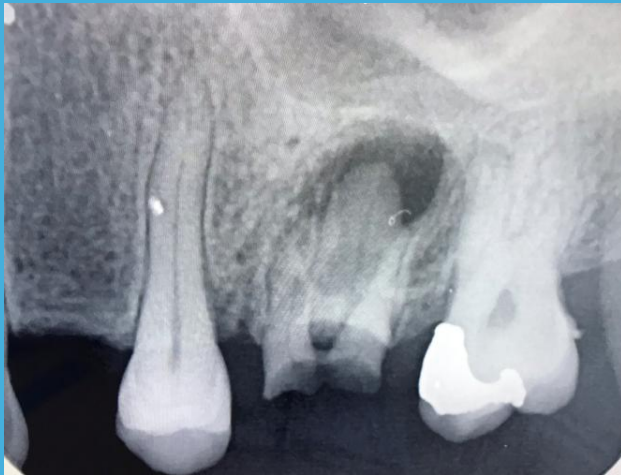- ***Restoration of UR3 UR8 LR7 LL7***
- ***RCT UL7 post core crown***
- ***Composite veneer for anterior teeth***
- ***Prosthetic replacement for UR4 UR5 UR7  
UL4 UL6 LR6***

## ***Phase 4***

***Follow up***

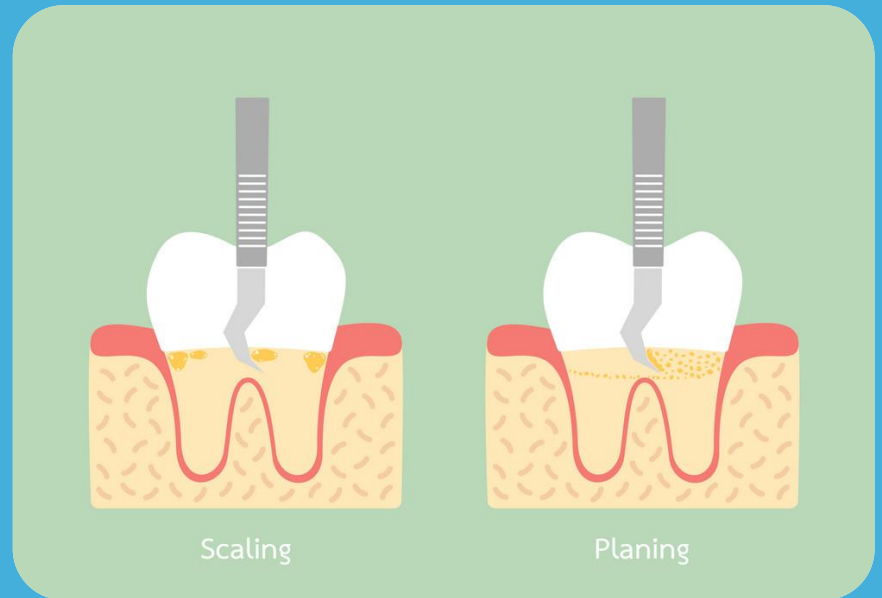
# Emergency phase

## ➤ Extraction UL6



# Phase 1

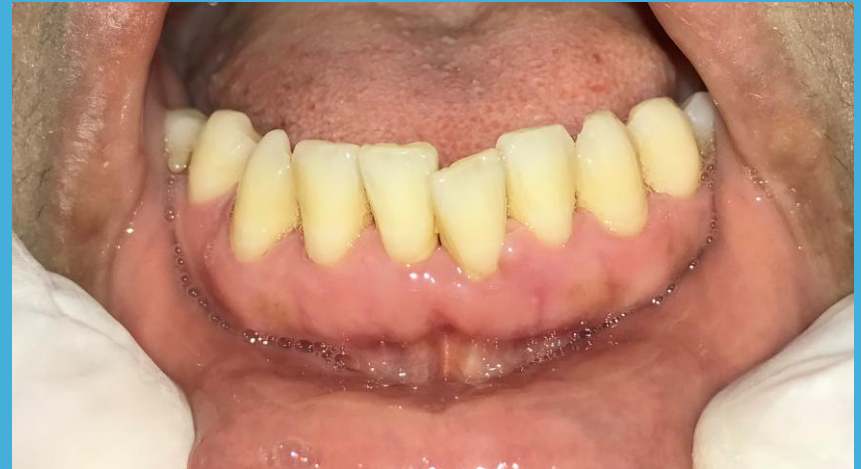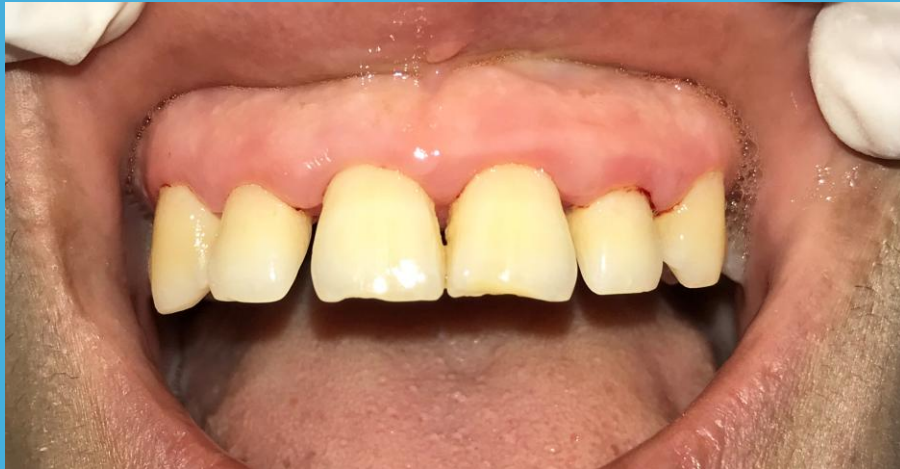- *Patient motivation and education*
- *OHI*
- *Scaling & root planning*
- *Diet advice*





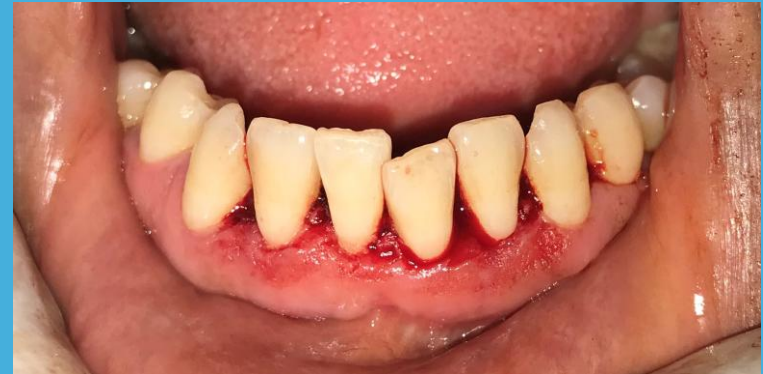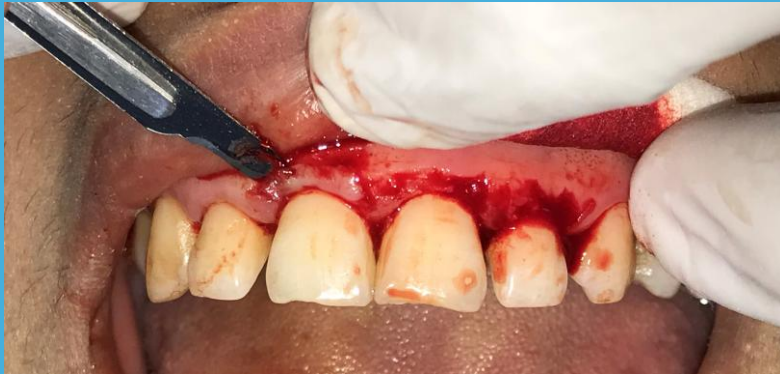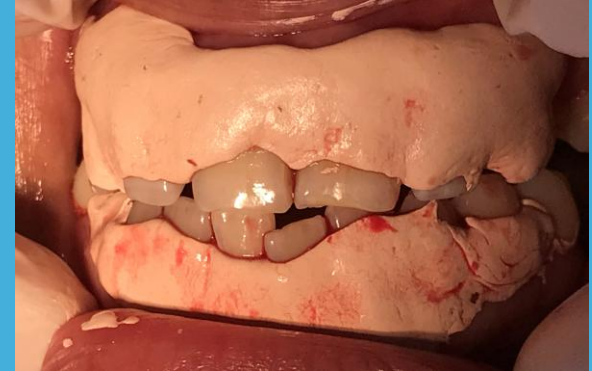# Re-evaluation

- *Improvement of patient hygiene*
- *Slight reduction of CAL (average 1mm)*



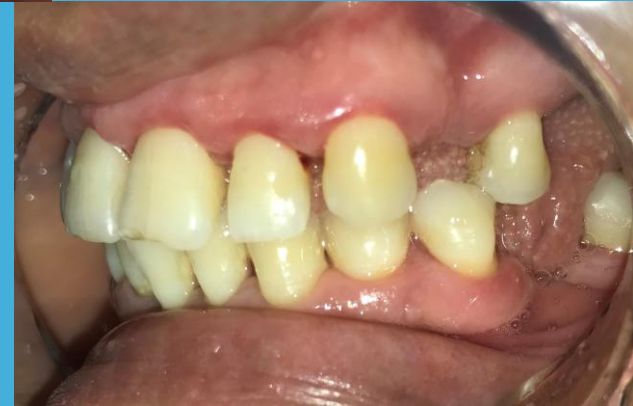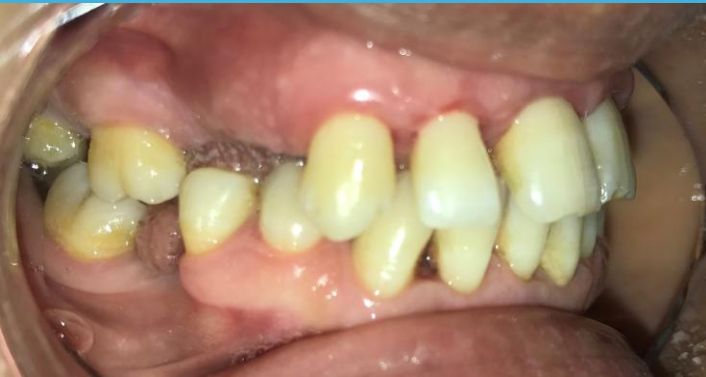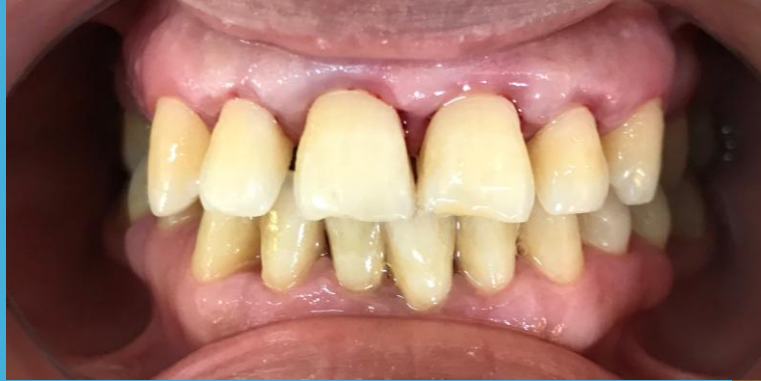## Phase 2

- *Gingivectomy*
- *Extraction UR4*



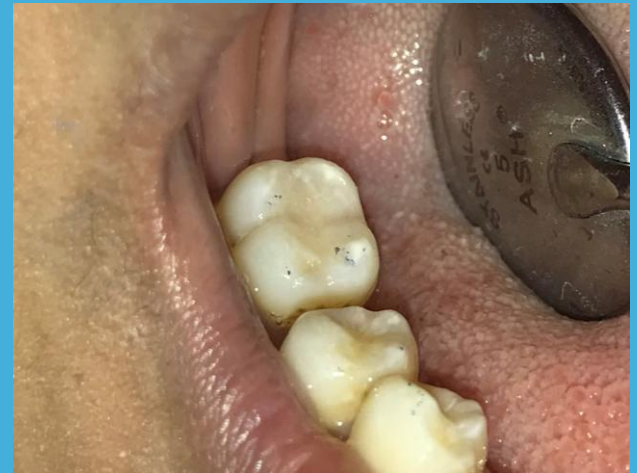
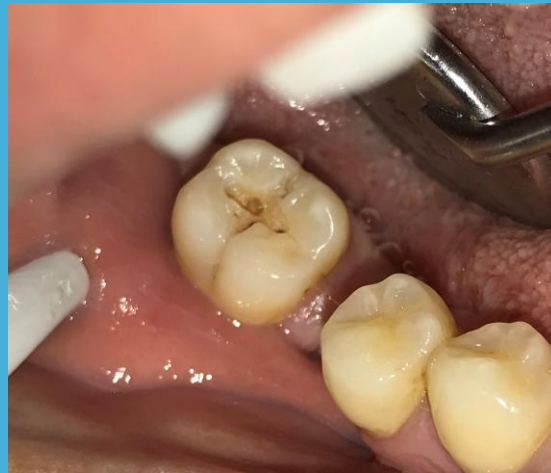
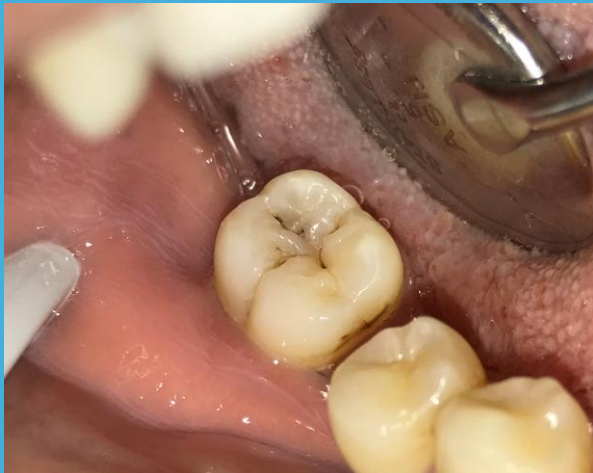# *Two weeks after surgery*



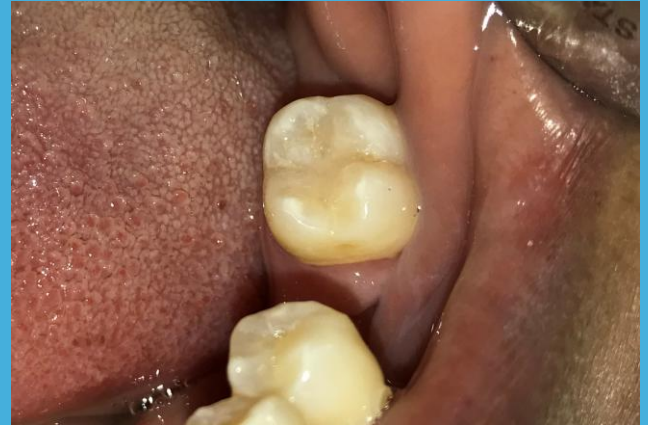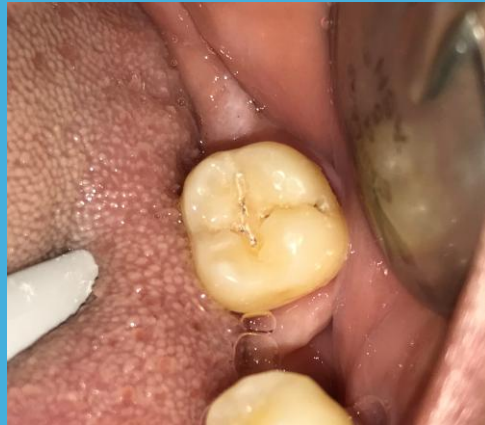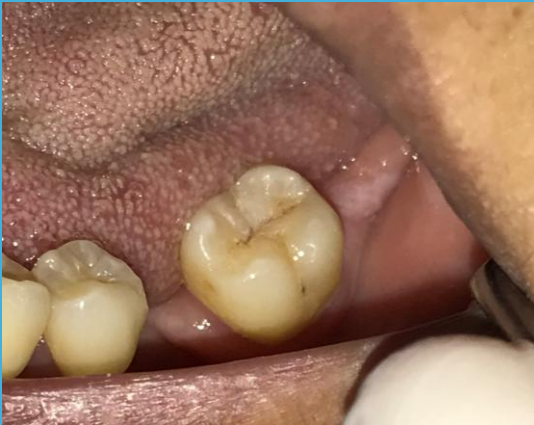## Phase 3

- *Class I Composite restoration of LL7*
- *Shade A2*



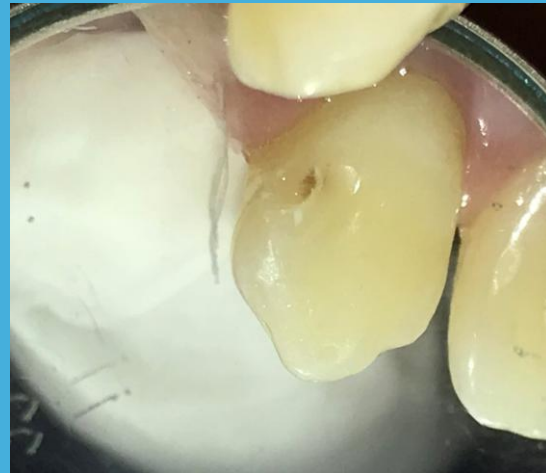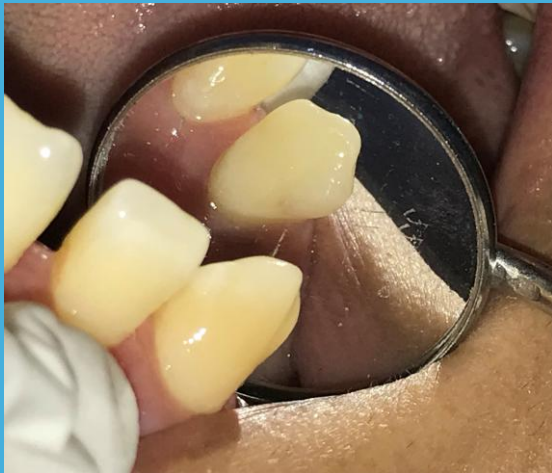## Phase 3

- *Class I Composite restoration of LR7*
- *Shade A2*



## Phase 3

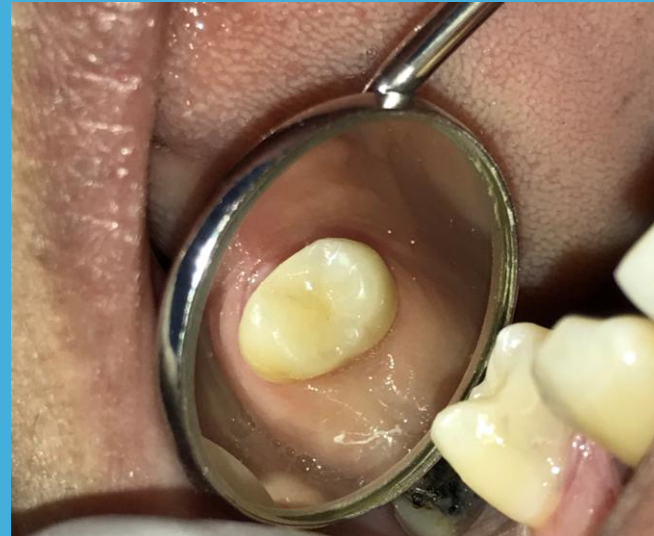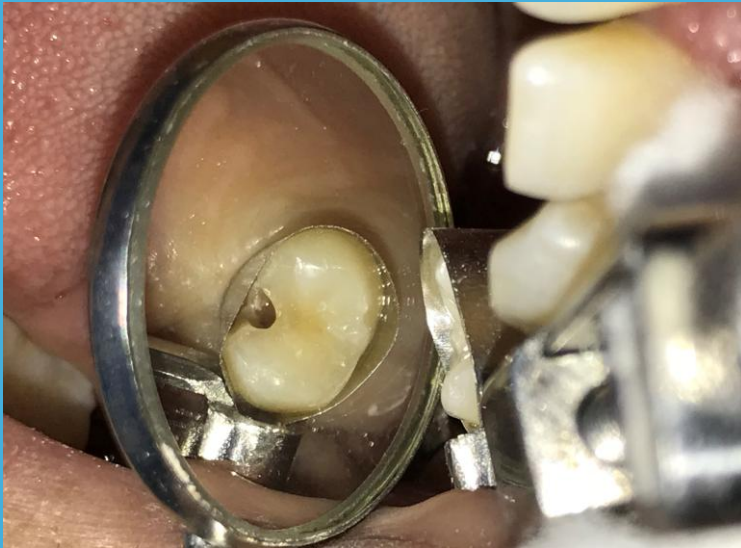- *Class III composite restoration of UR3*
- *Shade A2*





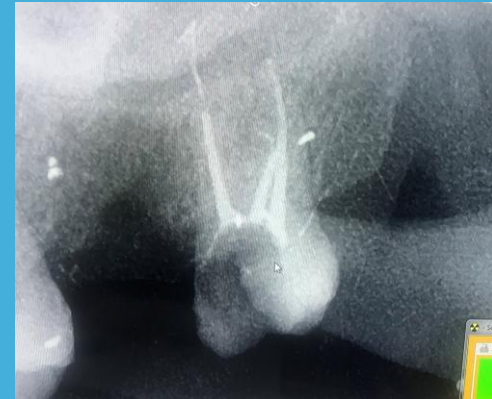
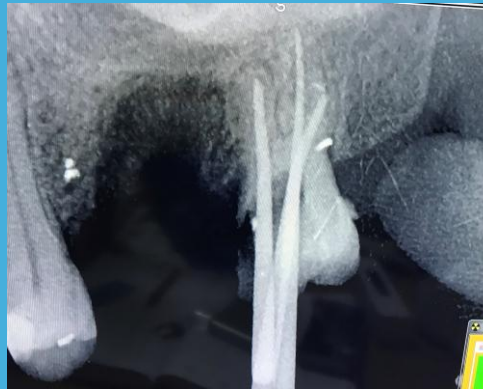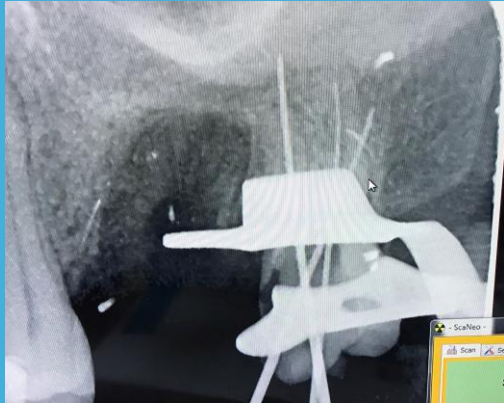
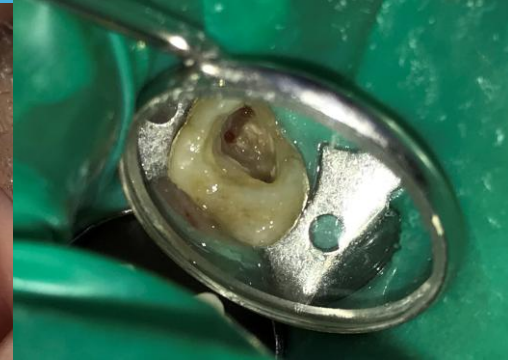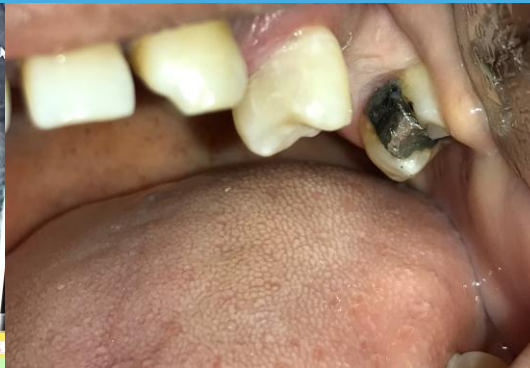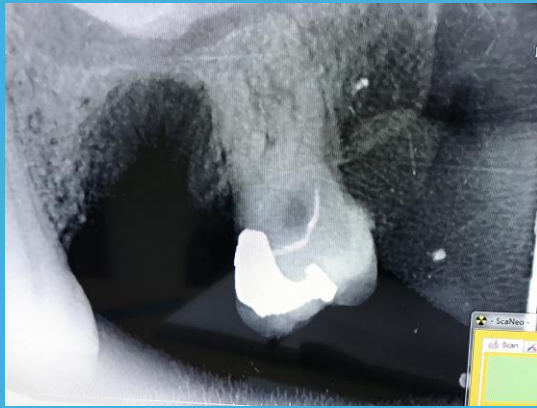
## Phase 3

- *Class II Composite restoration of UL5*
- *Shade A2*

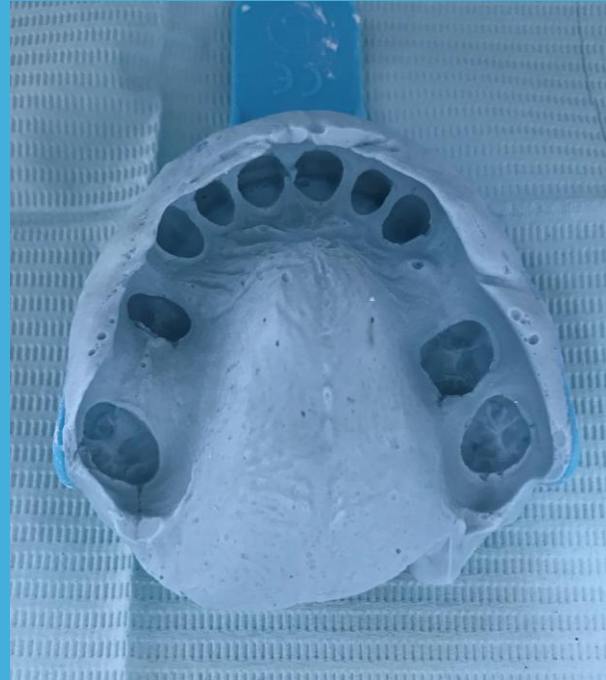
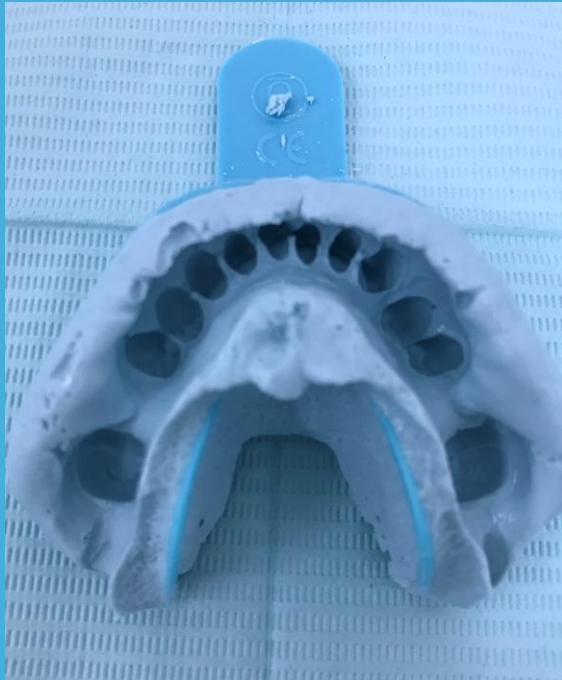
➤ *RCT using Pro Taper Rotary system for UL7*

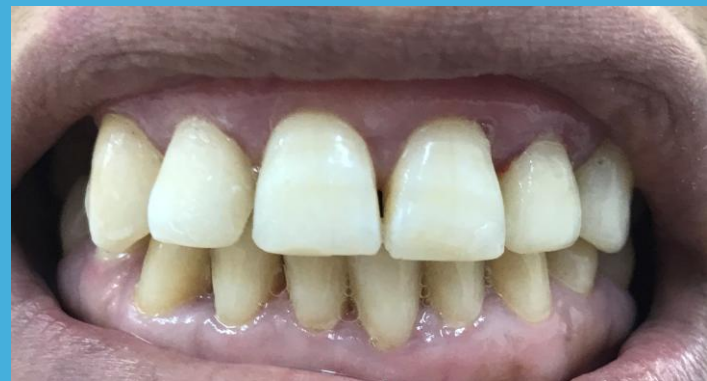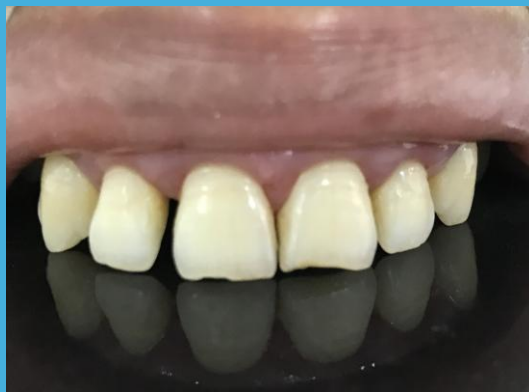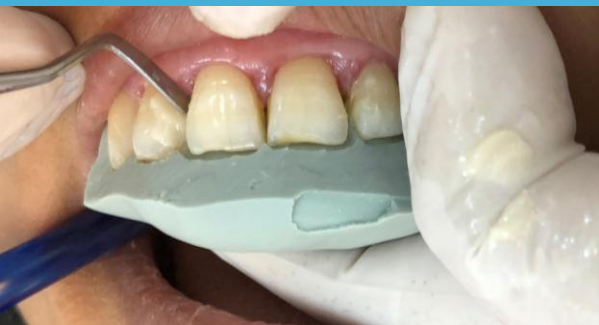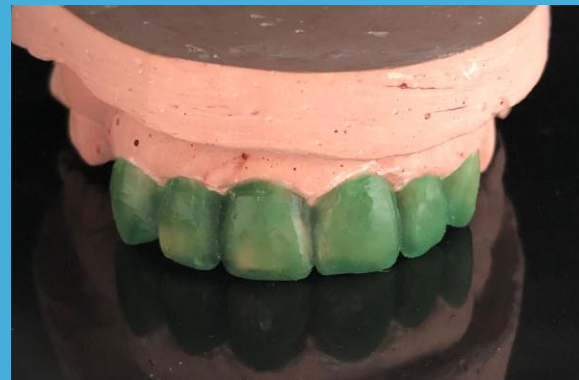➤ *Crown down technique*



# *Primary impression for wax up upper anterior teeth*

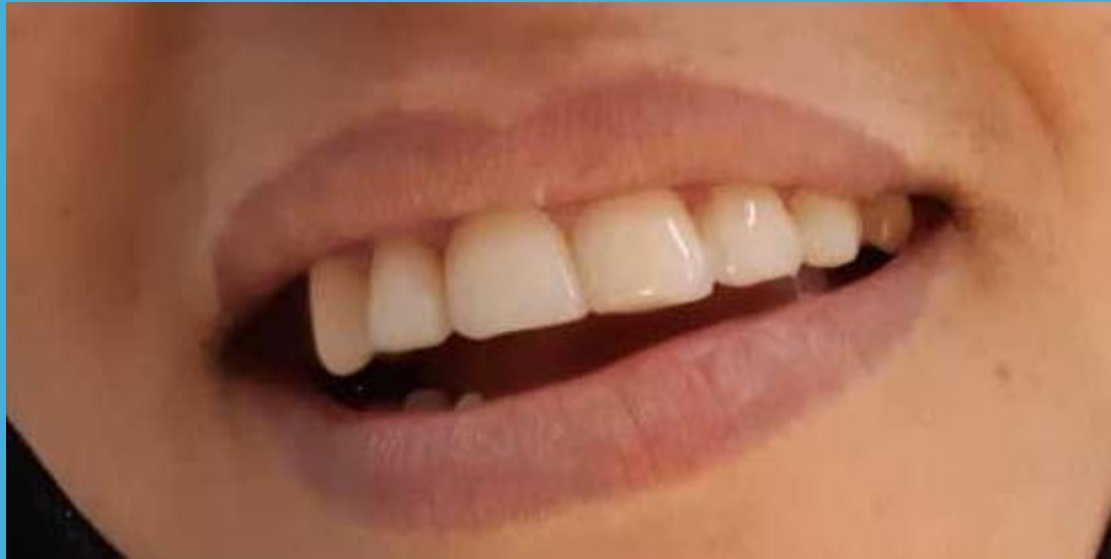

# Mock up



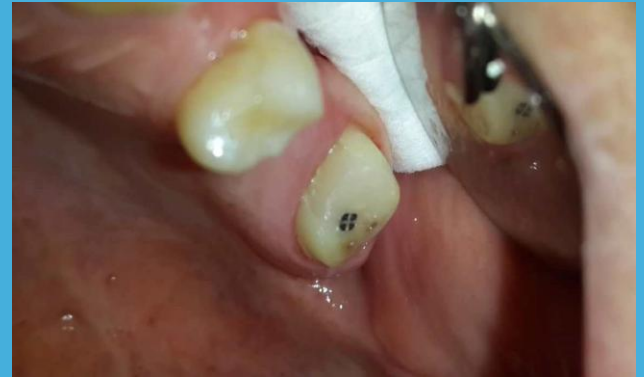
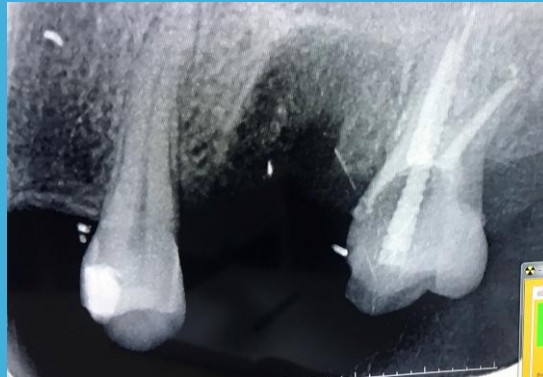
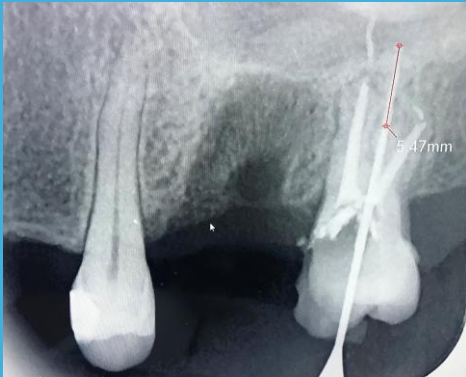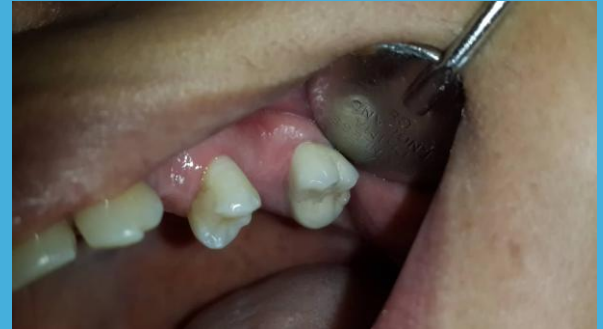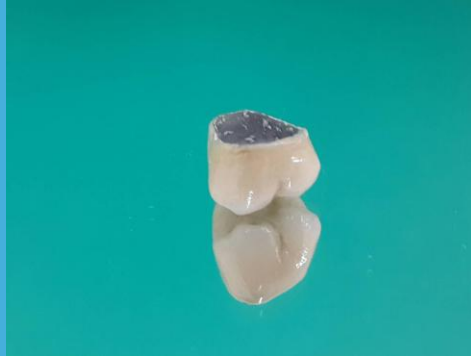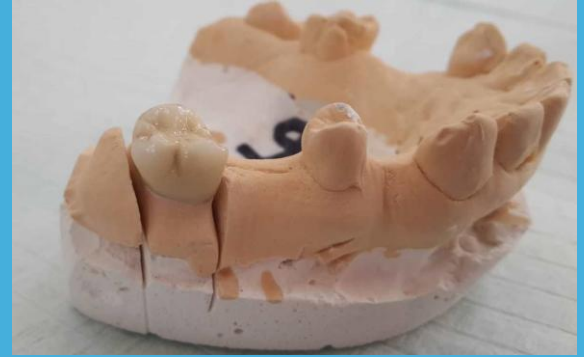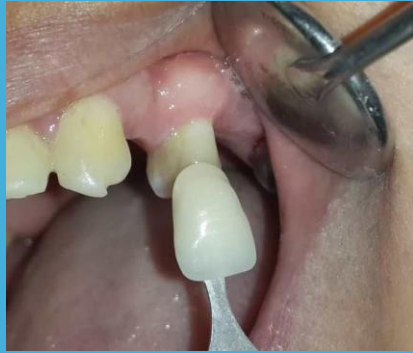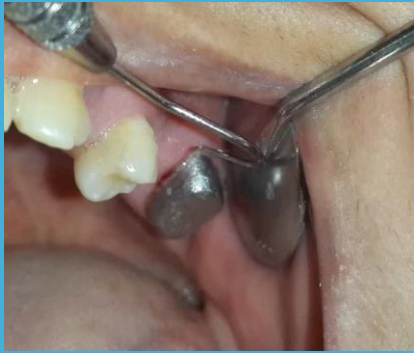# ■ *Composite veneer of Upper anterior teeth*



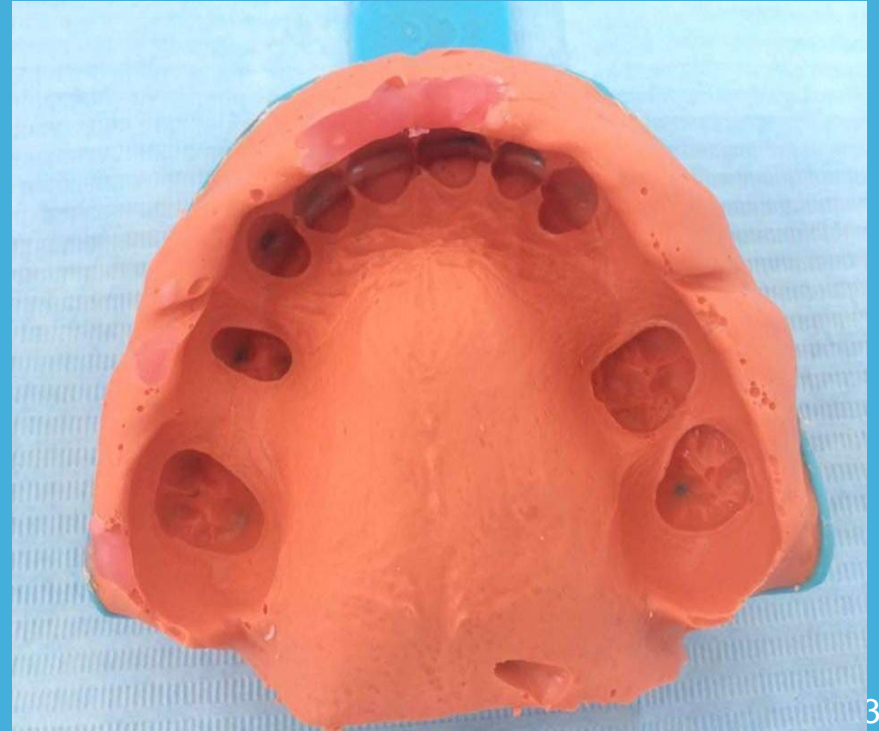
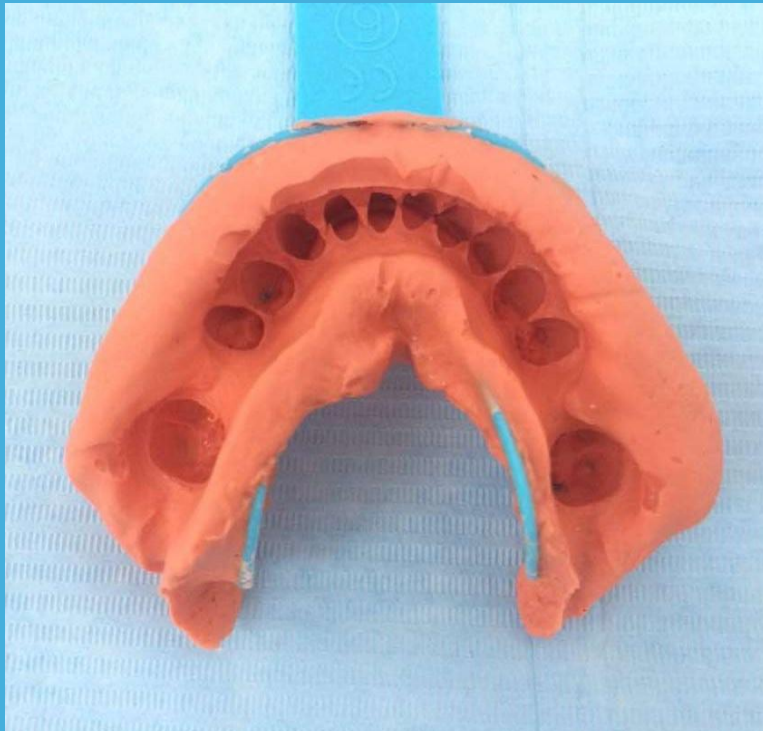
## Phase 3

- *Ready made metal post and composite core UL7*
- *PFM crown*

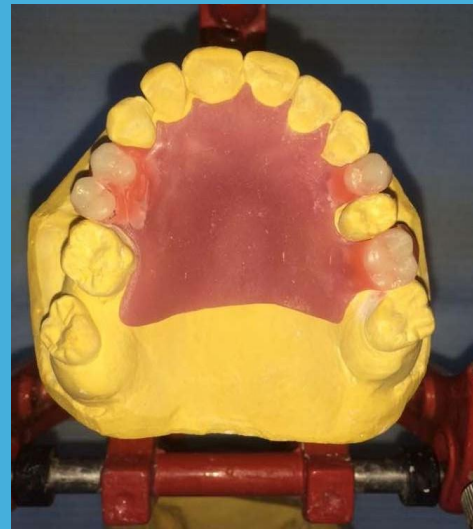
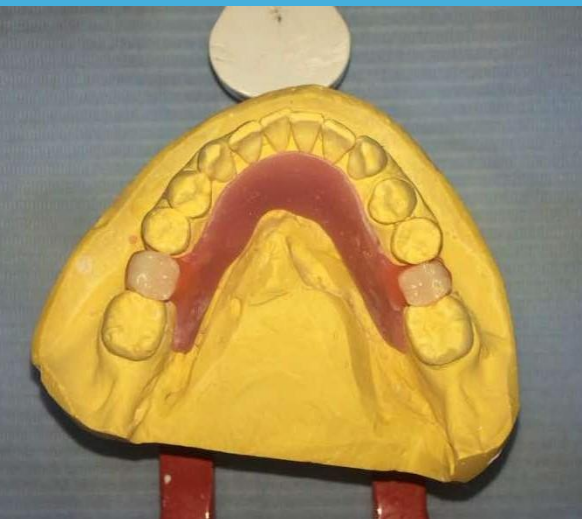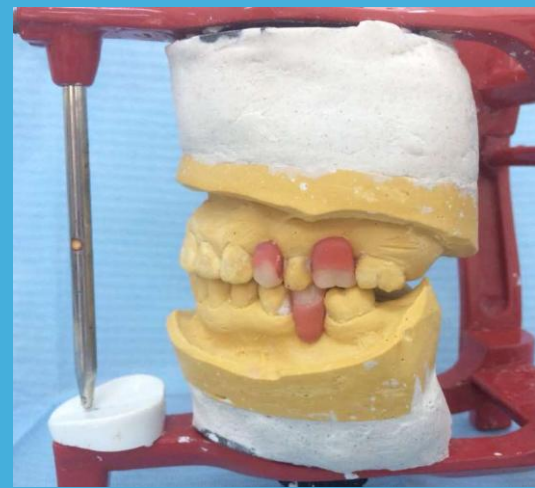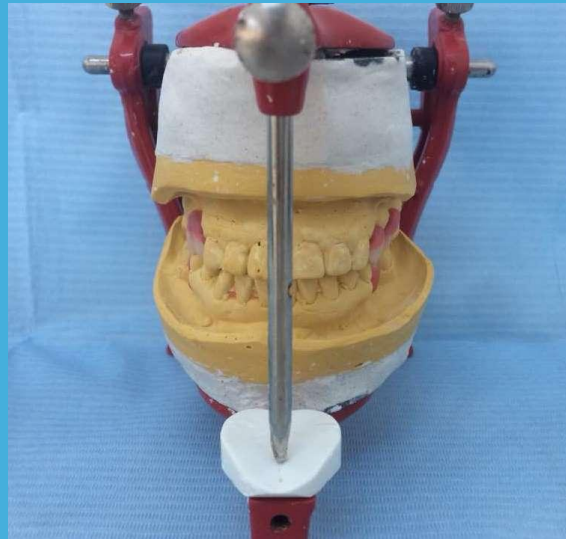


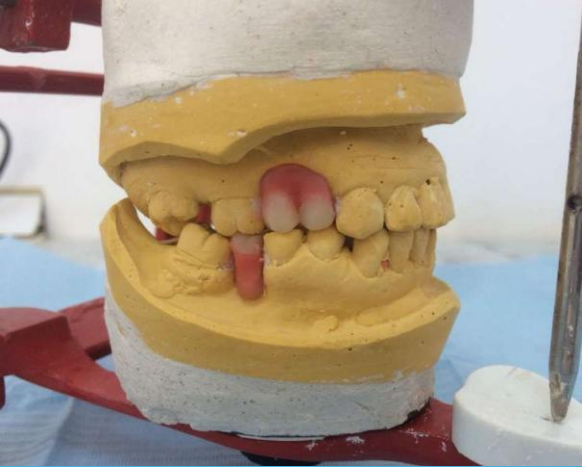

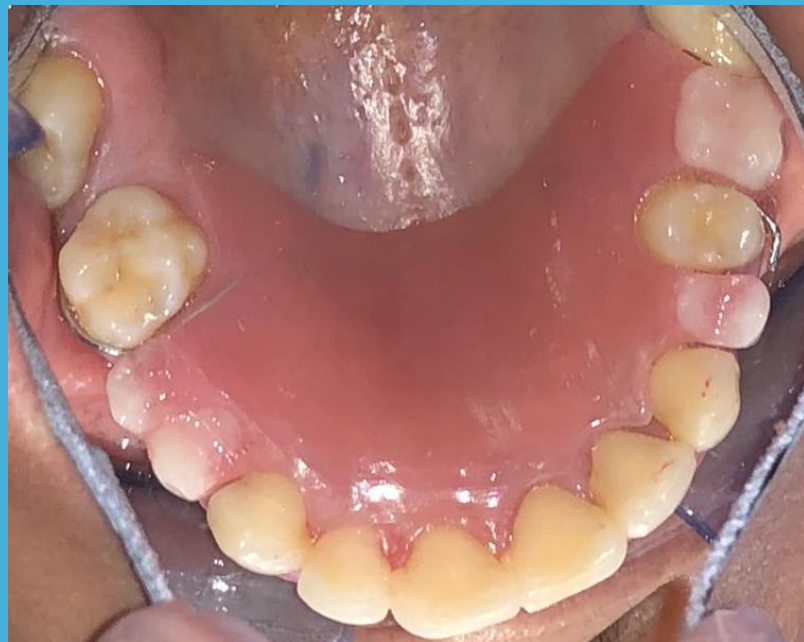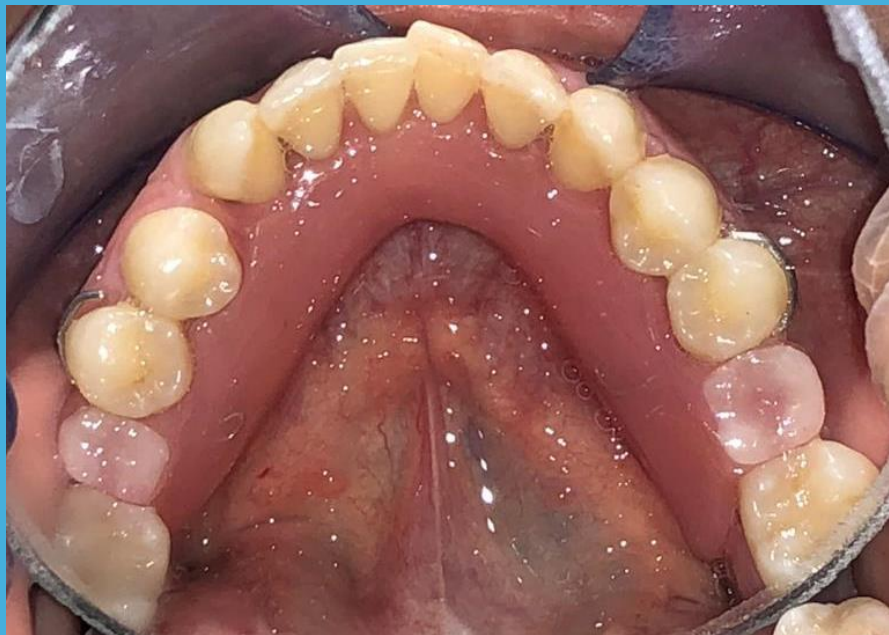# *Primary impression*







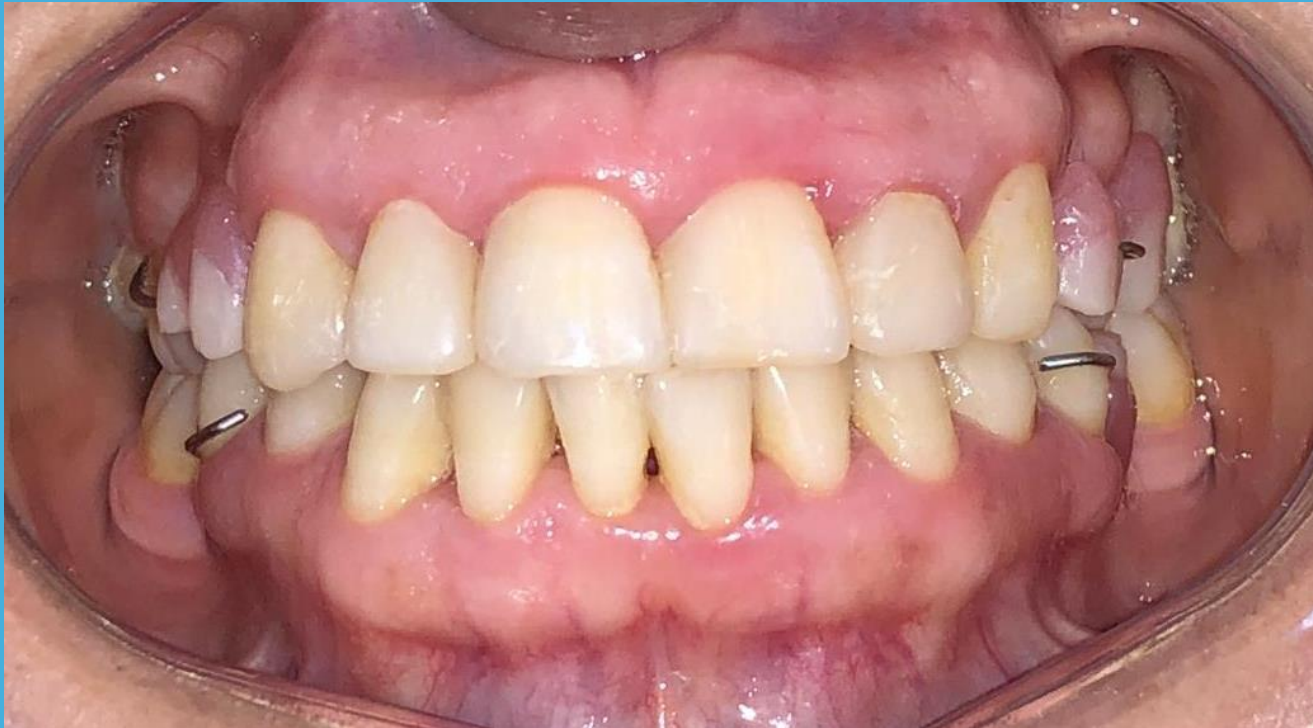## *Insertion of RPD*



## *Phase 4*

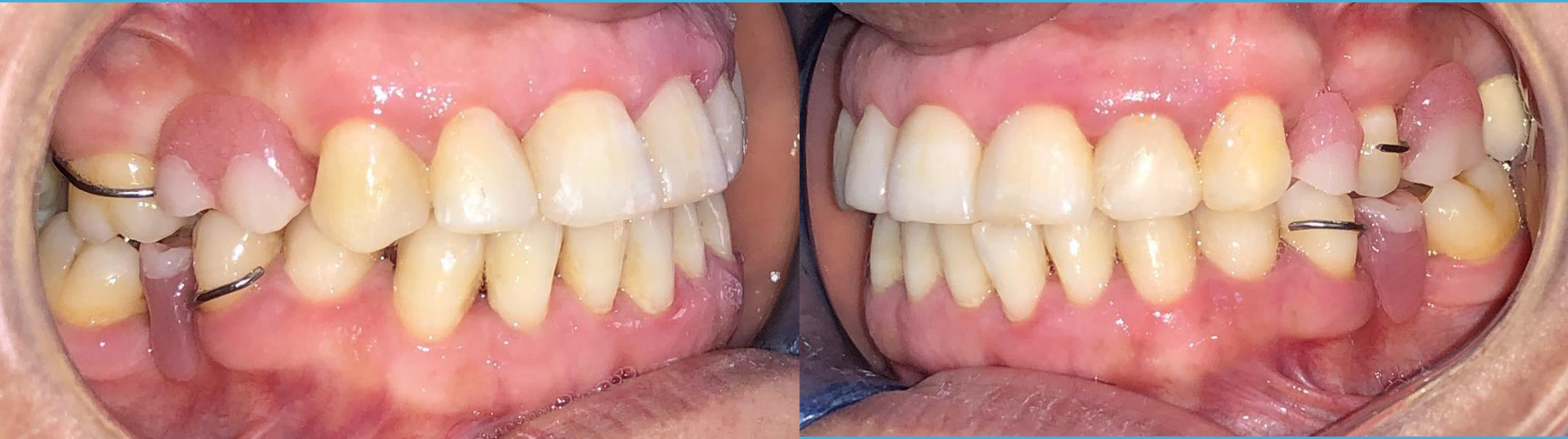- *Patient was satisfied*
- *Mucosa was checked for any pressure or damage areas*
- *Enforcement of OHI*

# *Post-operative Photographs*

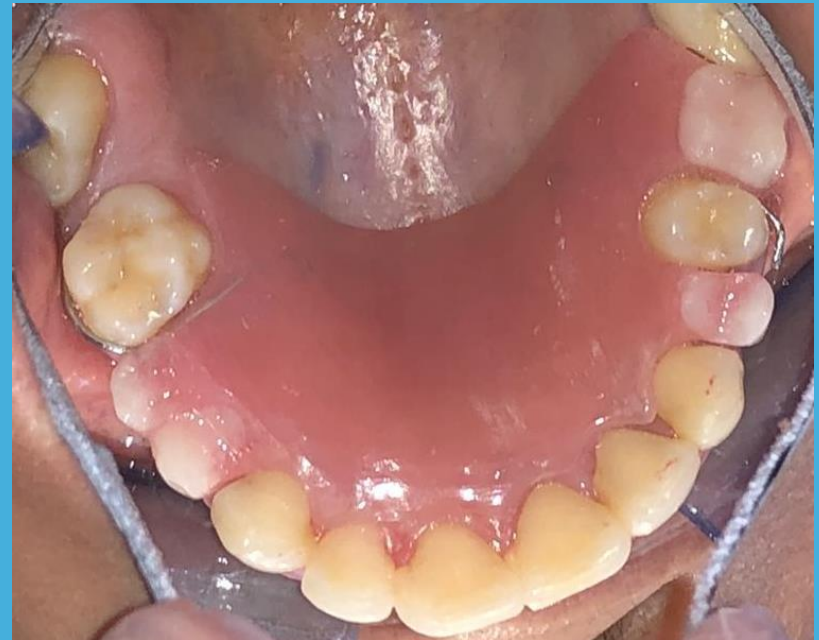
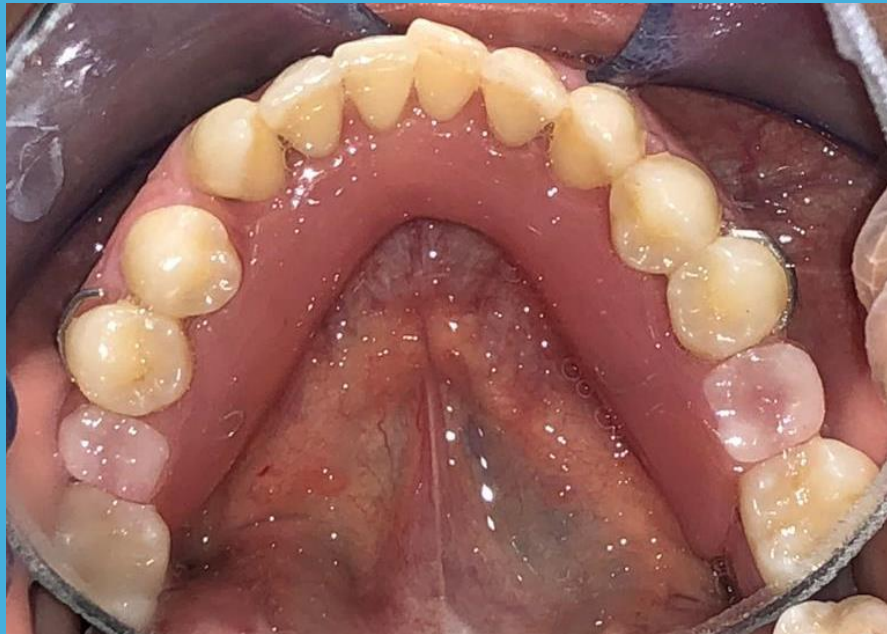


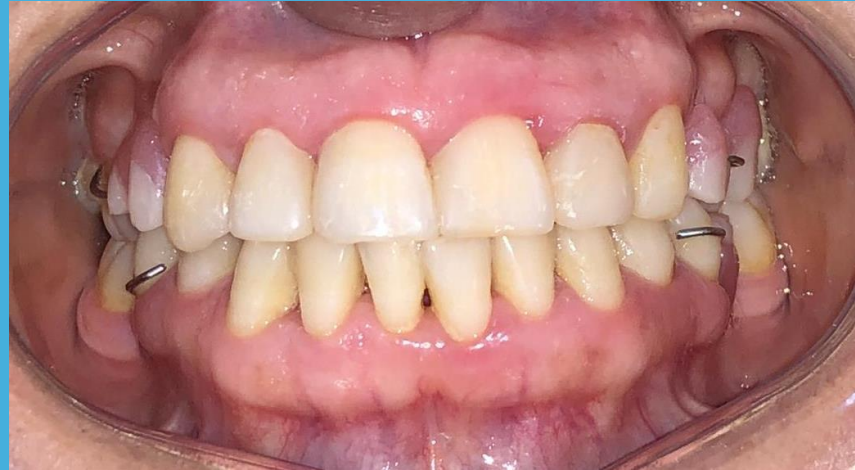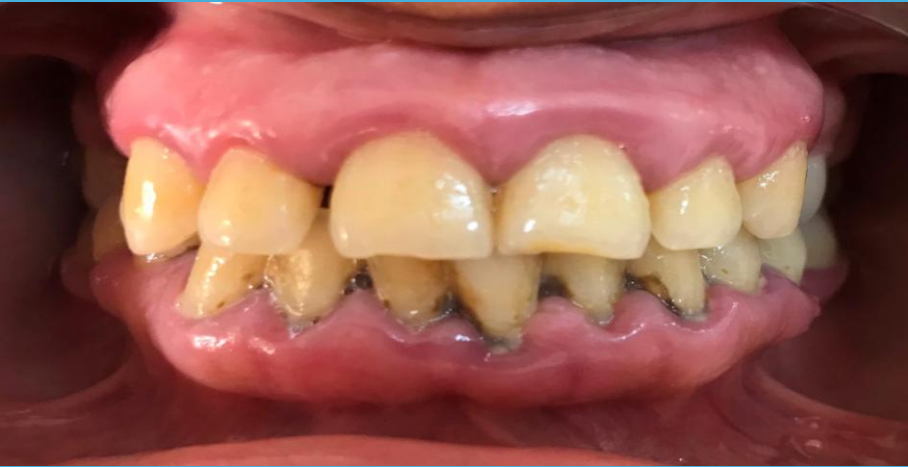# *Post-operative Photographs*



# *Post-operative Photographs*



# *Before & After*



# THANKS!

Any questions?

---