




C.T.DS

COLLAGEN-VASCULAR
DISORDERS

AMAL ALEREBI



- *The collagen–vascular disorders (connective tissue disorders) are a group of multisystem illnesses of unknown etiology.*
- *They have no typical pattern of onset, duration, or organ involvement.*

- 
- *This variability makes classification and diagnosis difficult; therefore a list of clinical diagnostic criteria has been established for each entity*
 - All feature arthritis or arthralgias, and most have prominent skin involvement.

Classifications of C.T.Ds

1) LUPUS ERYTHEMATOSUS:

- *Subacute cutaneous lupus erythematosus.*
- *Systemic lupus erythematosus(Acute LE).*
- *Chronic lupus erythematosus(Discoid LE).*
- *Drug-induced lupus erythematosus.*
- *Antiphospholipid syndrome.*

2) Dermatomyositis and polymyositis.

3) Scleroderma:


A) Localized

- *Morphea.*
- *Linear scleroderma.*
- *Disabling pansclerotic morphea.*

B) Systemic sclerosis.

4) Pseudoscleroderma.

5) Mixed collagen–vascular disorders and other overlap syndromes.




LUPUS
ERYTHEMATOSUS

The combination of history, clinical findings, and laboratory values can be used to classify LE as follows:

- Systemic LE (SLE): Primarily systemic involvement.
- Subacute cutaneous LE (SCLE): Predominantly skin findings, mild systemic involvement.
- Chronic cutaneous LE: Almost exclusively skin findings:
 - Discoid LE (DLE).

Pathogenesis:

- *LE is a multifactorial disease with genetic and immunopathologic abnormalities.*
- *Genetic predisposition: HLA-B8, -DR2, -DR3,ect.*
- *Complement defects: C1q, C1r, C1s, C4, C2 (skin and renal disease).*

- 
- *Exogenous factors: UV radiation and medications.*
 - *Transplacental transfer of maternal autoantibodies (anti-SSA, anti-SSB) can lead to neonatal LE*
 - *Individual factors: Hormone status, altered immune status*

Chronic Cutaneous lupus Erythematosus

(DLE) :

- *Chronic scarring erythema to sun-exposed skin.*
- *Less severe than acute SLE, but is also often associated with systemic disease.*
- *More common in women (2–3 :1); usually appears (15–60years)of age.*

Clinical features

- *Erythematous well-circumscribed persistent plaques with follicular hyperkeratoses.*
- *Telangiectases.*
- *Heal with scarring.*
- *peripheral hyperpigmentation and central hypopigmentation.*

Site of predilection:


- *Chronic sun exposed areas like scalp ,forehead ,cheeks, ears, nose,upper lip, and chin.*
- *Common causing of scarring alopecia especially in blacks.*
- *Small percentage of patients go on to develop SLE. (5%)*
- *ANA is +ve in 35 %*

Differential diagnosis:

- *Tinea faciei* (KOH examination).
- *Granuloma faciale* (brown color, no scarring).
- *Psoriasis* (silvery scale).
- *Lupus vulgaris* (diascopy).
- *Sarcoidosis* (diascopy, no prominent follicles).
- *Rosacea* (pustules, ears spared).
- *In each case, histology is most helpful.*

Therapy:

- *Sun avoidance and high-potency sunscreens (UVA, UVB).*
- *Short-term high-potency topical corticosteroids.*
- *Topical immunomodulators (pimecrolimus, tacrolimus) worth trying.*

- 
- *Cryotherapy or intralesional corticosteroids for stubborn lesions.*
 - *Systemic therapy for widespread, recalcitrant disease.*
 - *Dapsone 50–100mg daily.*

Antimalarials:

- *Hydroxychloroquine 200–400mg daily or chloroquine 250mg daily.*
- *monitoring by ophthalmologist required every (6–12months).*

Thalidomide 50–200mg daily; special cases, contraception, watch for neuropathy.

Subacute cutaneous lupus erythematosus

- *This is less severe than acute SLE, but is also often associated with systemic disease.*
- *photosensitivity.*
- *The skin lesions are sharply scaling psoriasiform plaques.*
- *annular.*
- *symmetrical*
lying on the forehead, nose, cheeks, chest, hands and extensor surfaces of the arms.

- Children born to mothers who have this condition are liable to neonatal LE with transient annular skin lesions and permanent heart block.

Differential diagnosis:

- Psoriasis or widespread discoid LE.
- Tinea corporis or figurate erythemas

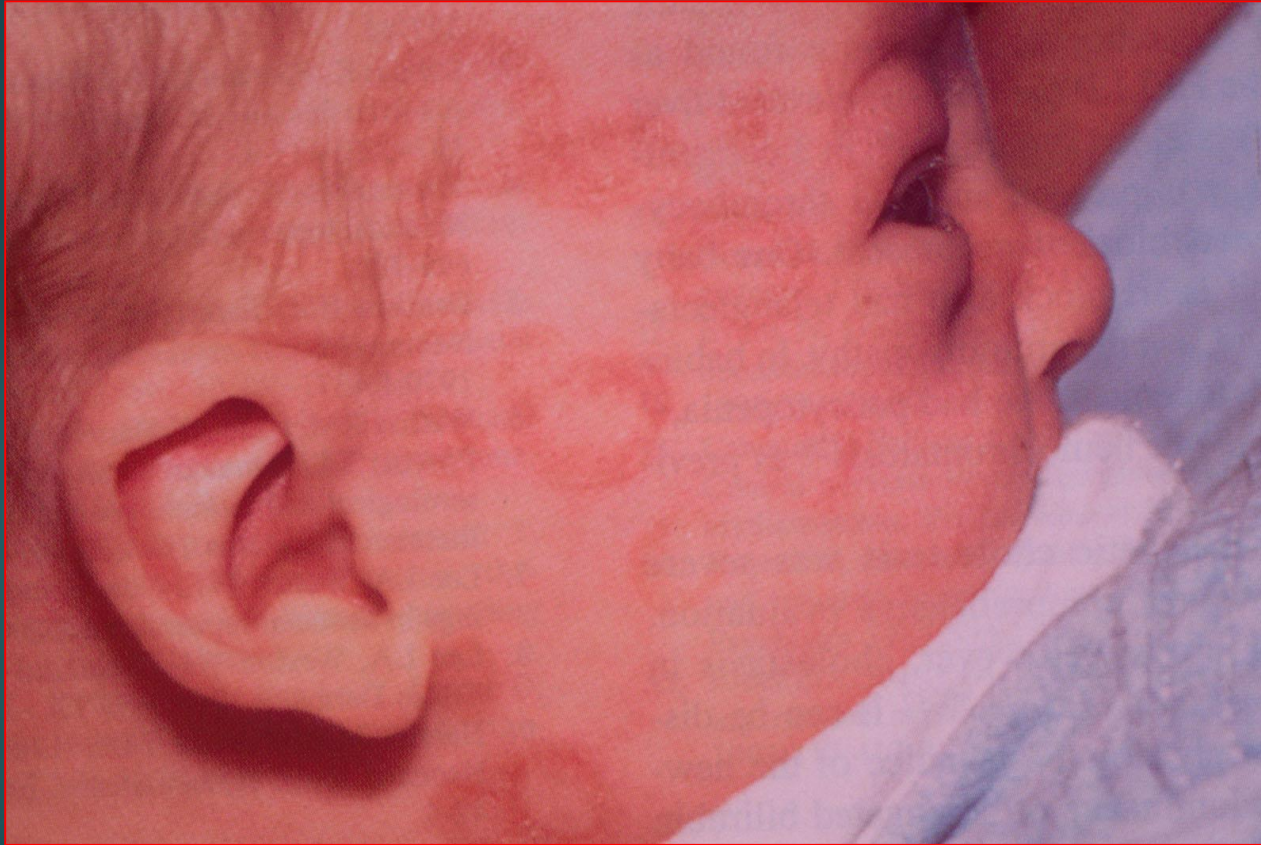- Many have anti Ro(SS-A) anti Laa (SS- B).

Treatment:

- Subacute cutaneous LE does better with antimalarials, such as hydroxychloroquine than acute SLE.

- Oral retinoids are also effective in some cases. Systemic steroids may be needed too.

Neonatal SLE



SLE



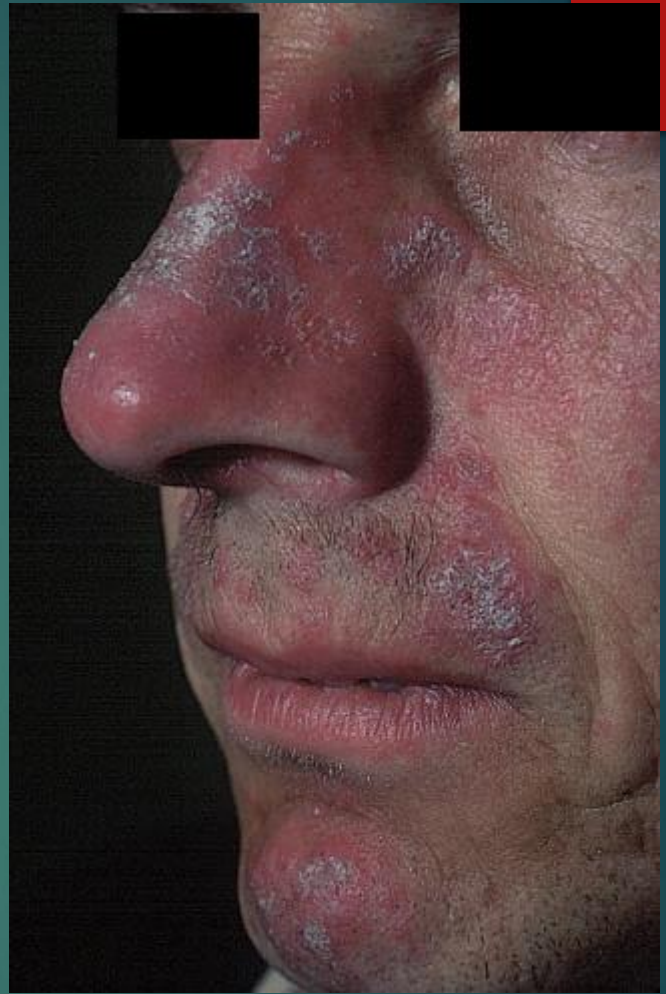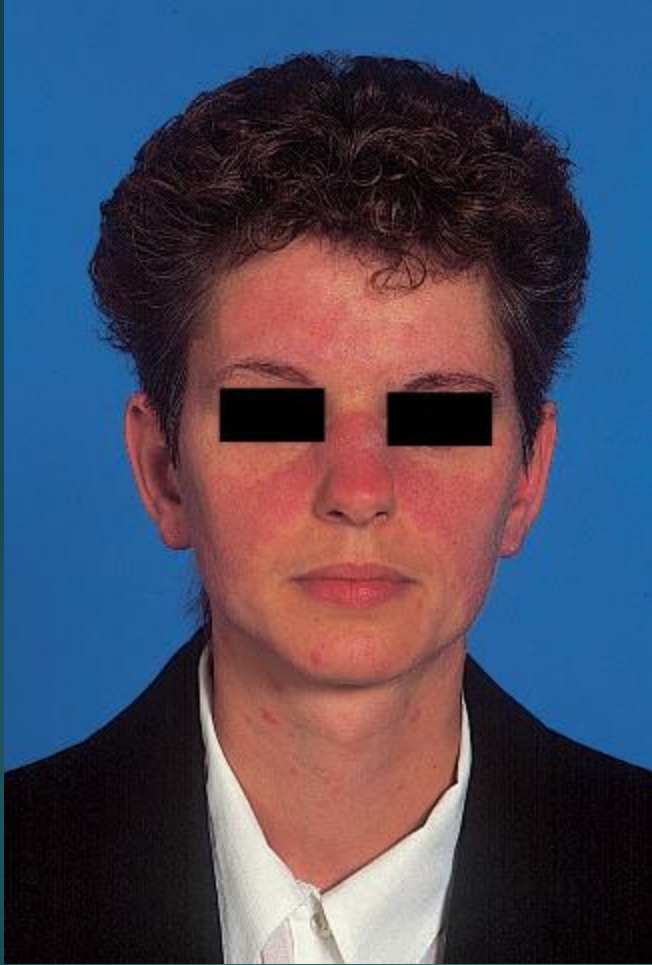Criteria for the diagnosis of SLE

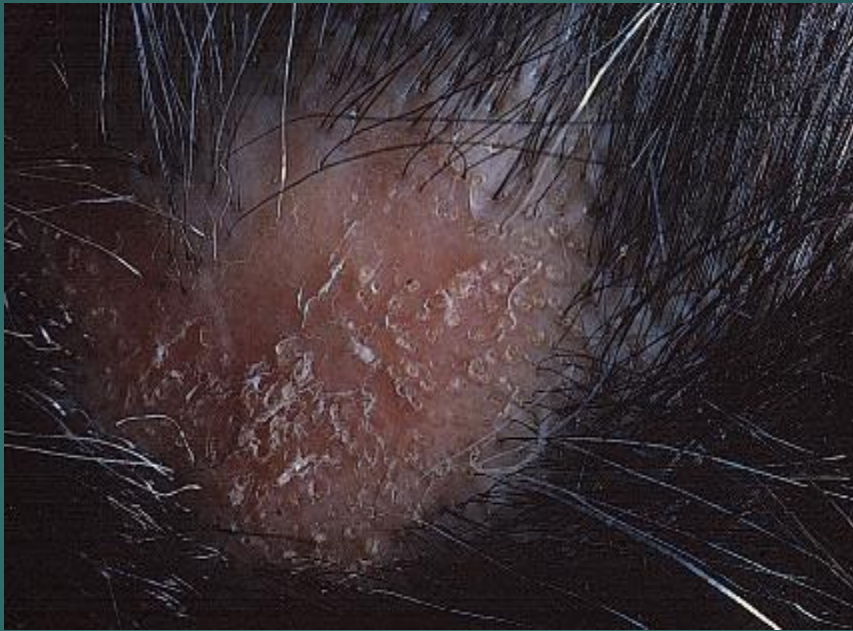
Must have at least four:

- Malar rash
- Discoid plaques
- Photosensitivity
- Mouth ulcers
- Arthritis
- Serositis
- Renal disorder
- Neurological disorder
- Haematological disorder
- Immunological disorder
- Antinuclear antibodies (ANA)

Cutaneous manifestation of SLE

- ▶ Photosensitivity
- ▶ Malar rash (butterfly)
- ▶ DLE
- ▶ Bulous lesions
- ▶ Purpura & telengactesia
- ▶ Palmer erythema
- ▶ Non scaring diffuse alopecia
- ▶ Oral ulcers
- ▶ Raynauds phenomena

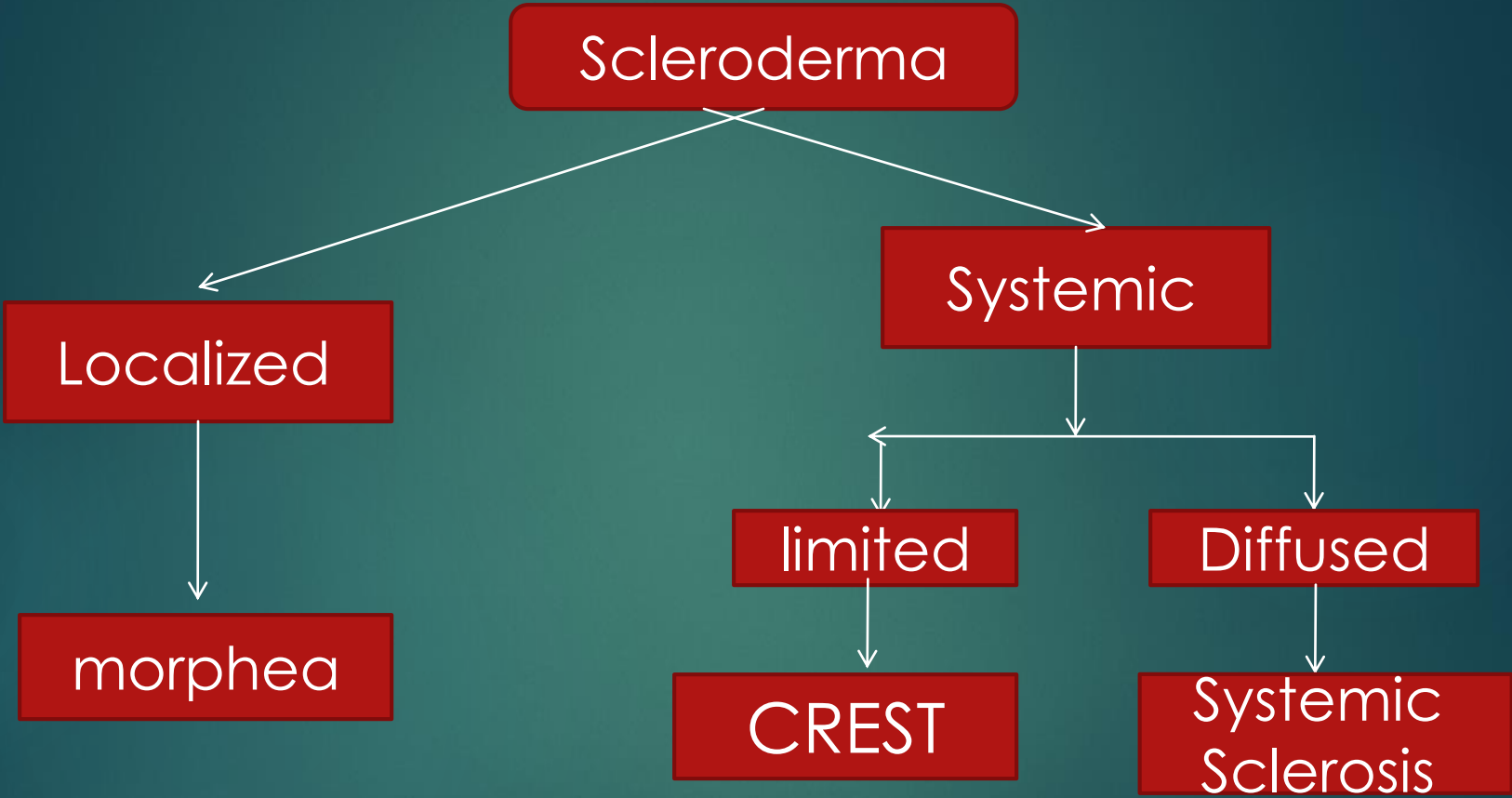






SCLERODERMA

- *Scleroderma is a chronic autoimmune connective tissue disease of unknown cause affects the skin, blood vessels and internal organs.*
- *Characterized by woody or hard non pinching skin and common in female than male .*
- *Characterized by the appearance of circumscribed or diffuse, hard, smooth, ivory-colored areas that are immobile .*



Localized scleroderma (Morphea):

- *Is twice more common in women than in men and occurs in childhood as well as in adult life.*
- *It presents most often as macules or plaques a few centimeters in diameter, but also may occur as bands .*
- *It present for several years and then may disappear with atrophy and a mottled hyperpigmentation.*

Clinical types of morphea:

1-Plaque like.

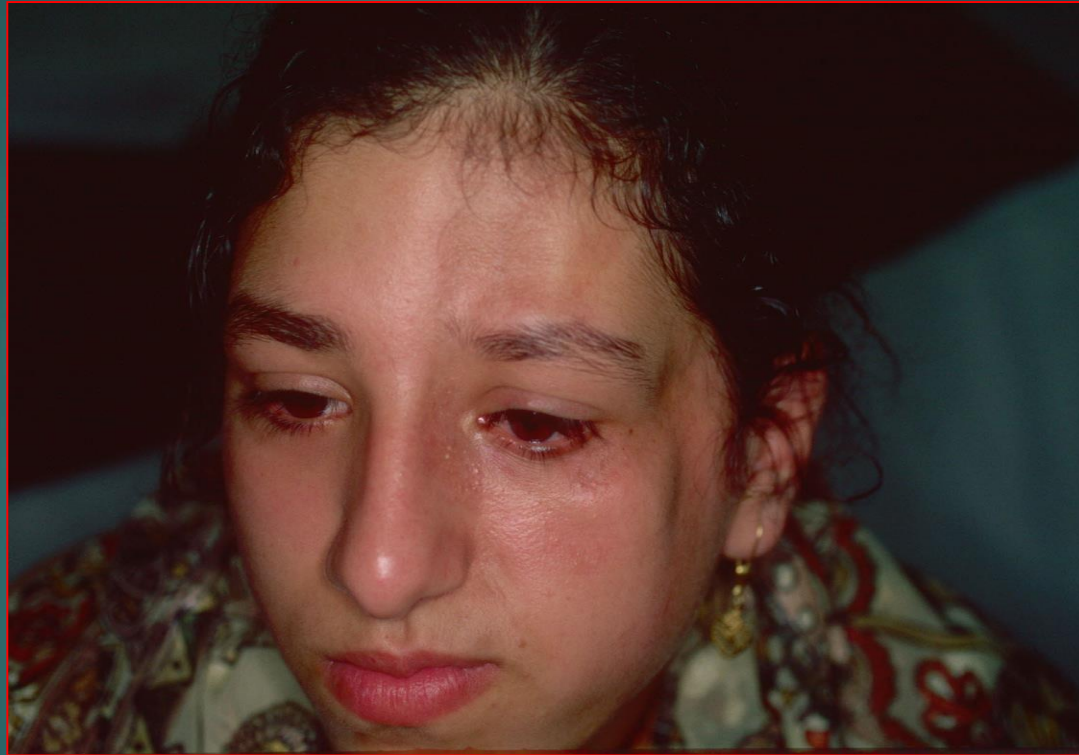2-Generalized .

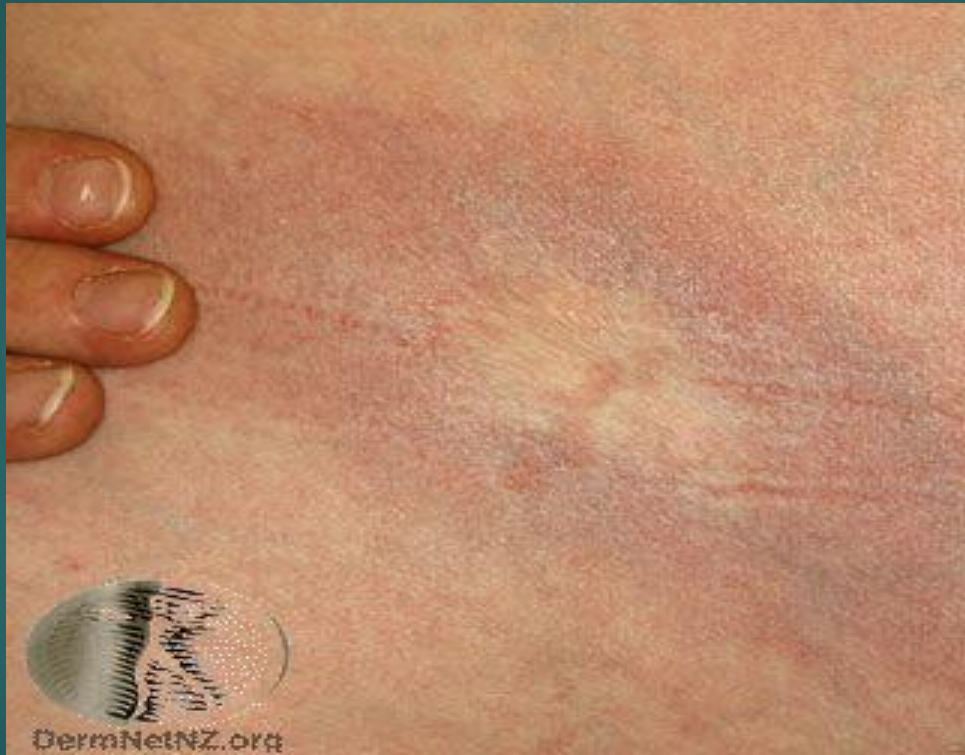3-Linear .

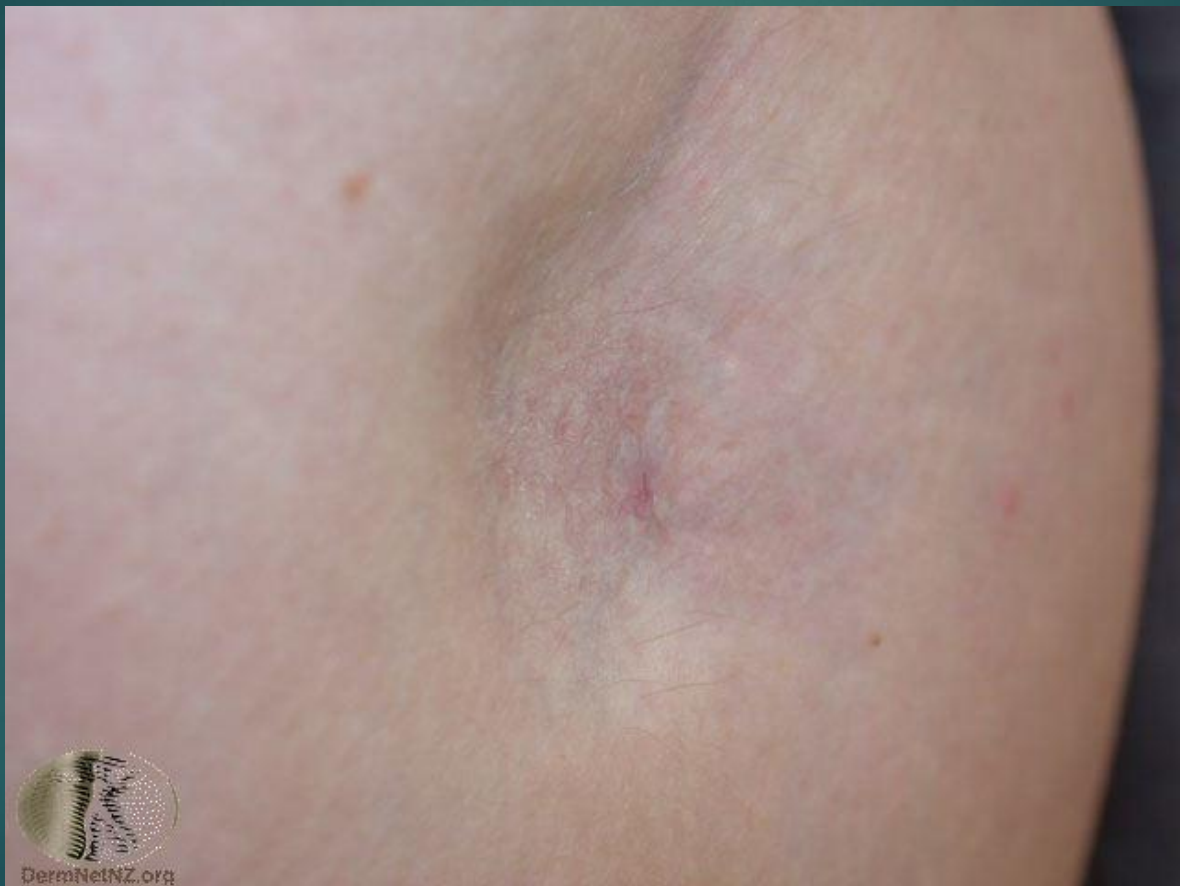4-Guttate.

5-En coup de sabre (frontoparietal scleroderma).

En coup de sabre (frontoparietal
scleroderma).







Therapy:

Solitary lesions with high-potency topical corticosteroids, also under occlusion or intralesional.

- *Bath PUVA or UVA1*

Systemic scleroderma

(progressive systemic sclerosis)

- *Multi-organ disease with diffuse sclerosis of connective tissue favoring skin, lungs, GIT and kidneys.*
- *Age 30 and 50 years*
- *increases with age*
- *female : male ratio 5:1*
- *men have worse prognosis.*

Cutaneous manifestation of SS

1-Raynaud's phenomenon.

2-Sclerodactyly and digital pitting .

3-Mask face (loss of facial expression).

4-Small mouth, thinned lips, and radial perioral furrows.

5-Beak shape nose.



6-(Salt and pepper) appearance of skin.localized depigmentation sparing of the perifollicular skin.

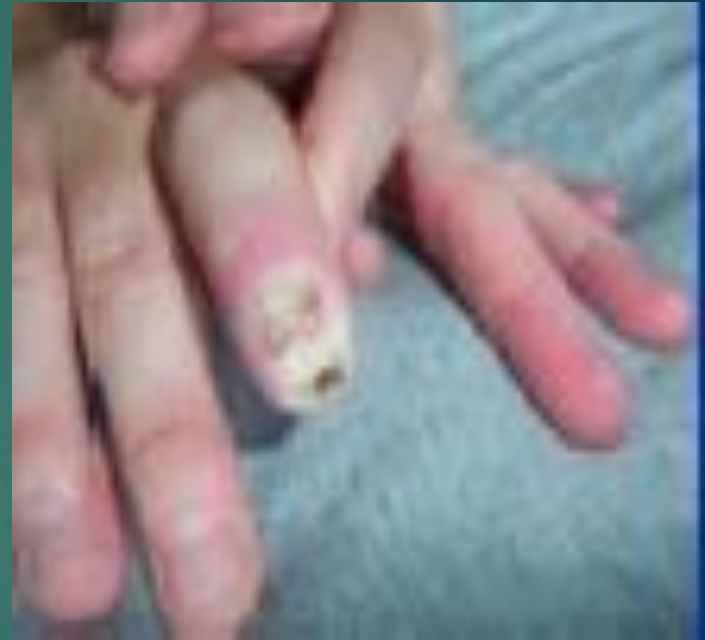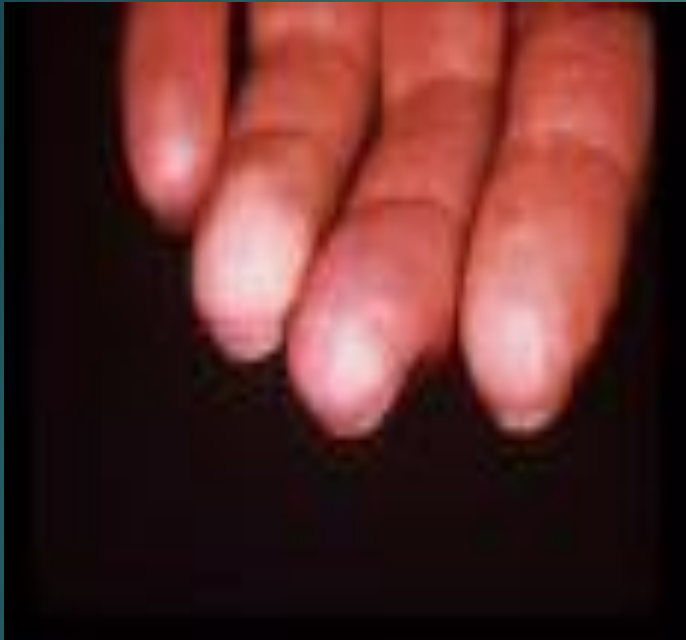7-Telangiectasia on the hands,face and proximal nail fold.

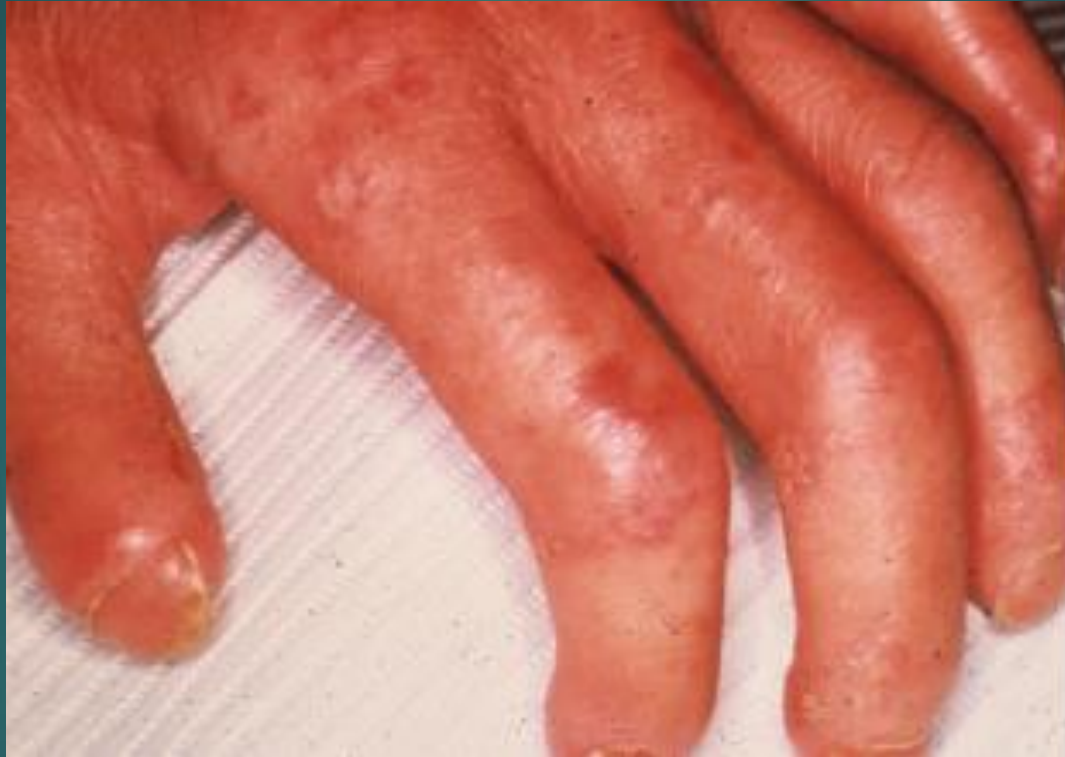8-Calcinosis cutis(extremities usually near joints and distal location).

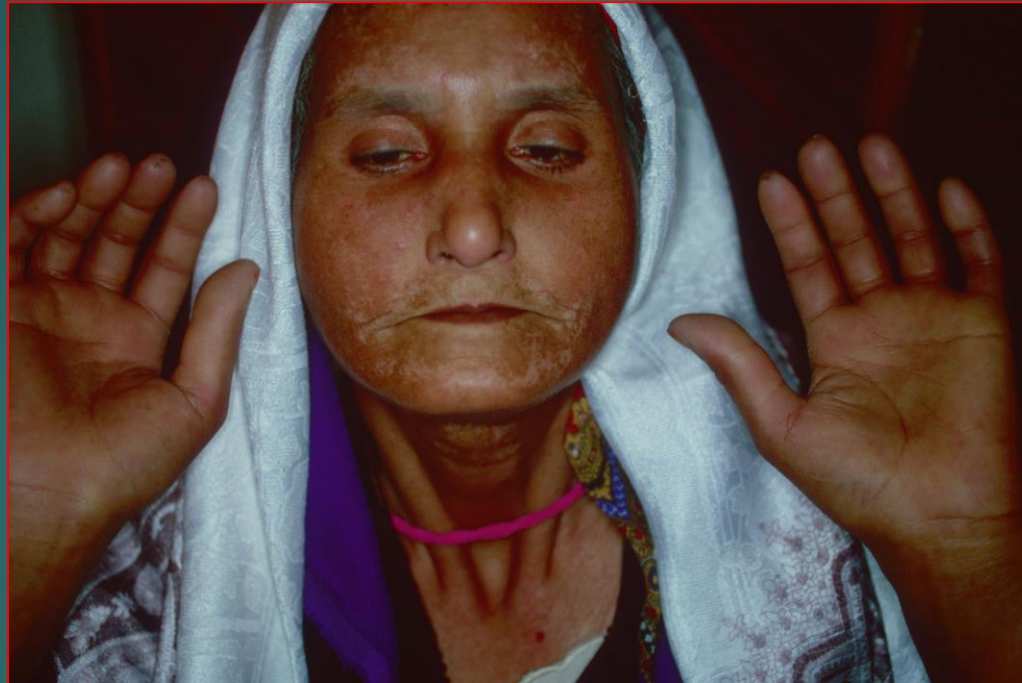9-cutaneous ulceration.

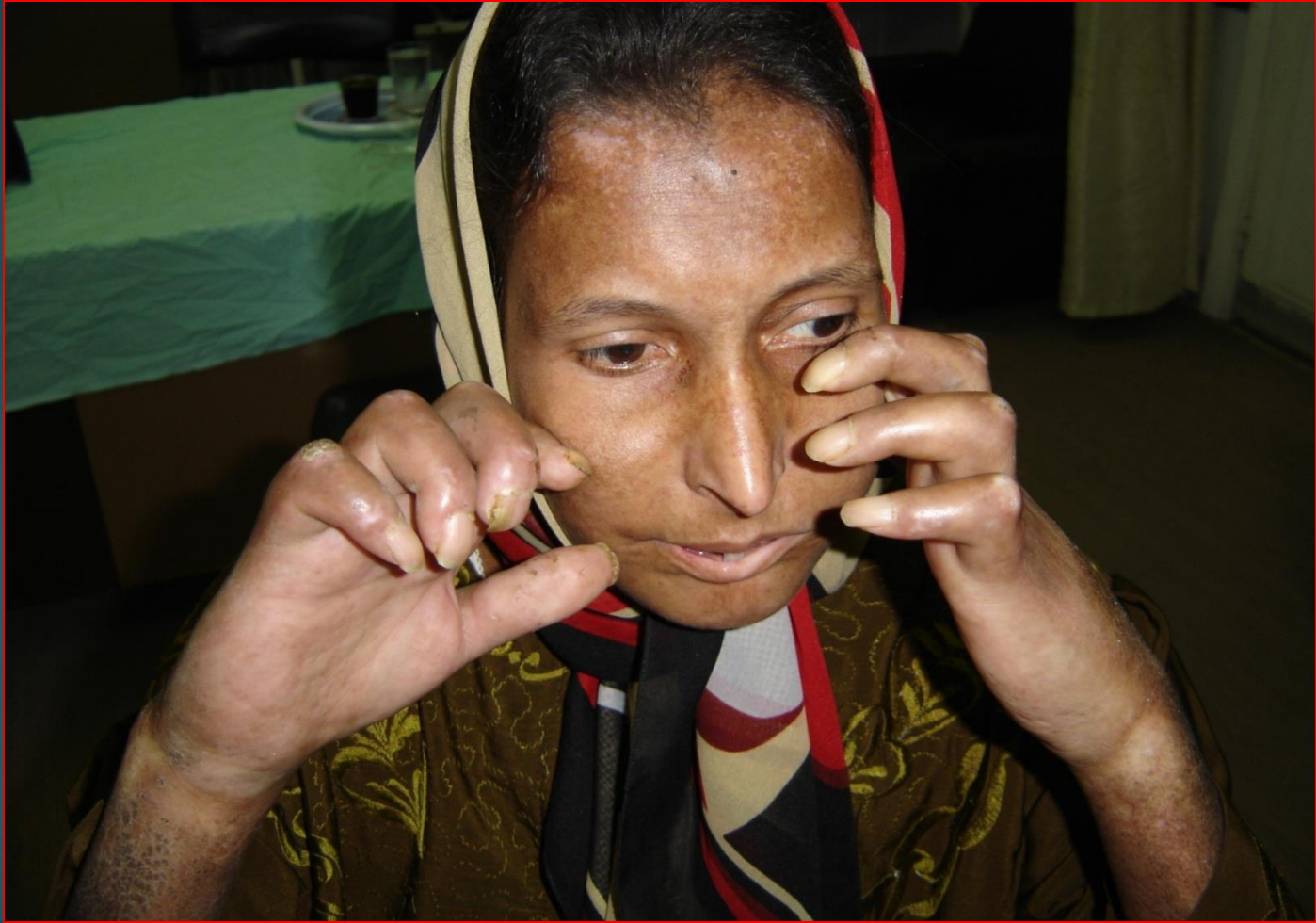10-fingers tapering.

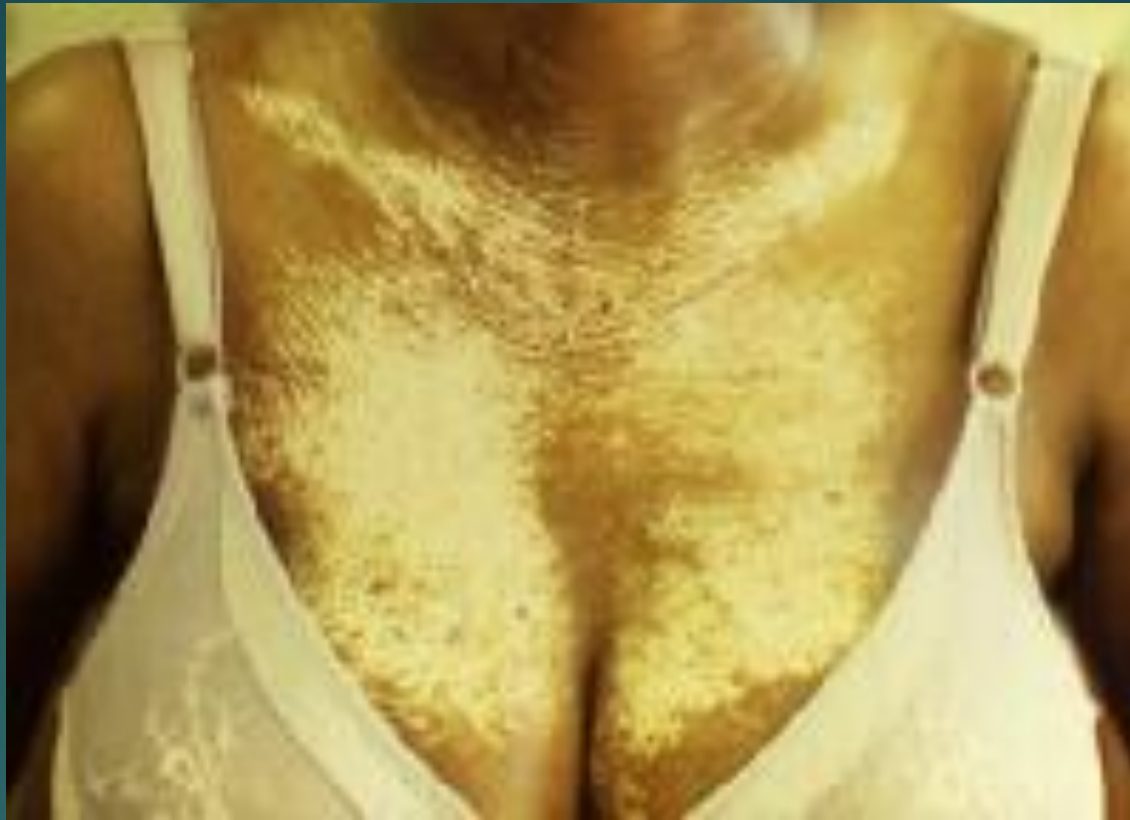Digital ulcerations











Anterior chest demonstrating salt-and-pepper hypopigmentation and diffuse hyperpigmentation in a white woman.

CREST Syndrome

- C- Calcinosis.
- R- Raynaud's.
- E- Esophageal dysmotility.
- S- Sclerodactyly.
- T- Telangiectasia.

Laboratory:


- *More than 90% have positive ANA.*
- *Anti-Scl-70 positive in 30–70%; usually with severe course.*
- *Anti-centromere antibodies present in type I systemic sclerosis and CREST syndrome.*
- *Rheumatoid factor positive in 30%.*

Therapy



Raynaud phenomenon:


- Warm skin and vasodilators (nifedipine), ACE inhibitors, prostacycline analogue.
- Calcification: Surgery sometimes required.
- Ulcers: Occlusive dressings .
- Physiotherapy & phototherapy

- 
- *Immunosuppressive agents: Systemic corticosteroids (prednisolone 0.5mg/kg daily).*
 - *Methotrexate 20–30mg weekly, cyclosporine 3–5mg/kg daily, or cyclophosphamide 2mg/kg daily .*
 - *Aspirin: Pain relief and inhibition of platelet function.*

Internal organ involvement:


- *Angiotensin-converting enzyme (ACE) inhibitors are treatment of choice for renal hypertension.*
- *Proton pump inhibitors (omeprazole 20–40mg daily) indicated for esophageal dysfunction.*
- *Pulmonary hypertension treated with i.v. prostacyclin; interstitial lung disease may respond best to cyclophosphamide.*

- *Dermatomyositis is an idiopathic inflammatory myopathy (IIM) with characteristic cutaneous findings.*
- *It is a systemic disorder that most frequently affects the skin and muscles, but may also affect the joints, the esophagus, the lungs, and, less commonly, the heart.*

- 
- Calcinosis is a complication of dermatomyositis that is observed most often in children and adolescents.
 - An association between dermatomyositis and cancer has been recognized.

Four of the 5 criteria are related to the muscle disease, as follows:

- Progressive proximal symmetrical weakness.
- Elevated levels of muscle enzymes.
- An abnormal finding on electromyography.
- An abnormal finding on muscle biopsy.
- The fifth criterion was compatible with cutaneous disease.

- 
- *Drug-induced dermatomyositis like hydroxyurea, penicillamine, statin drugs, quinidine, and phenylbutazone.*
 - *Ages of onset : in adults, approximately 50 years, whereas in children, approximately 5-10 years.*
 - *Dermatomyositis and polymyositis are 2 times common in women as in men .*

Clinical Presentation

- *Often 40% of patients, present with skin disease as the initial manifestations.*
- *Muscle disease may occur concurrently, it may precede the skin disease, or it may follow the skin disease by weeks to years.*
- *Systemic manifestations may occur like arthralgias, arthritis, dyspnea, dysphagia, arrhythmias, and dysphonia.*

Muscle involvement

- Proximal muscle weakness, and muscle tenderness may occur.
- pathognomonic cutaneous features of dermatomyositis are:
 - heliotrope rash .
 - Gottron papules.
 - Gottron sign.

cutaneous manifestation of Dermatomyocytis

heliotrope rash .

Gottron papules.

Gottron sign(*violaceous erythema on the extensor surfaces*).

malar erythema.

poikiloderma in a photosensitive distribution.

periungual and cuticular changes.

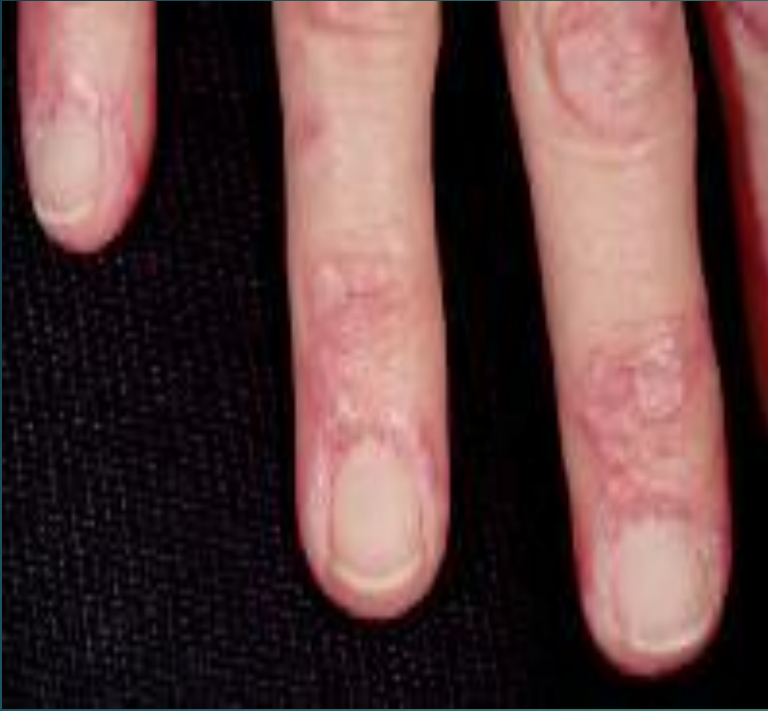Pruritis

Calcinosis cuties

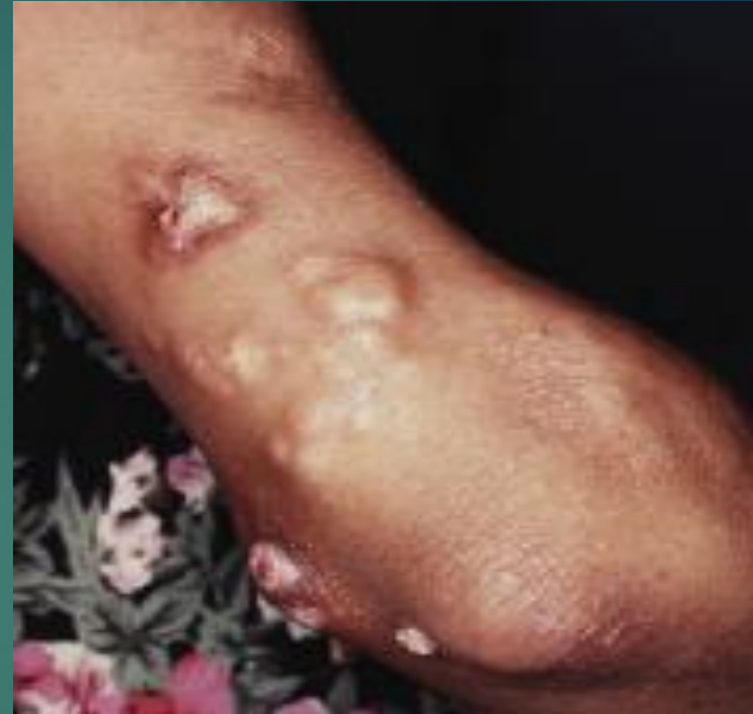Mechanic hands

➤ heliotrope rash

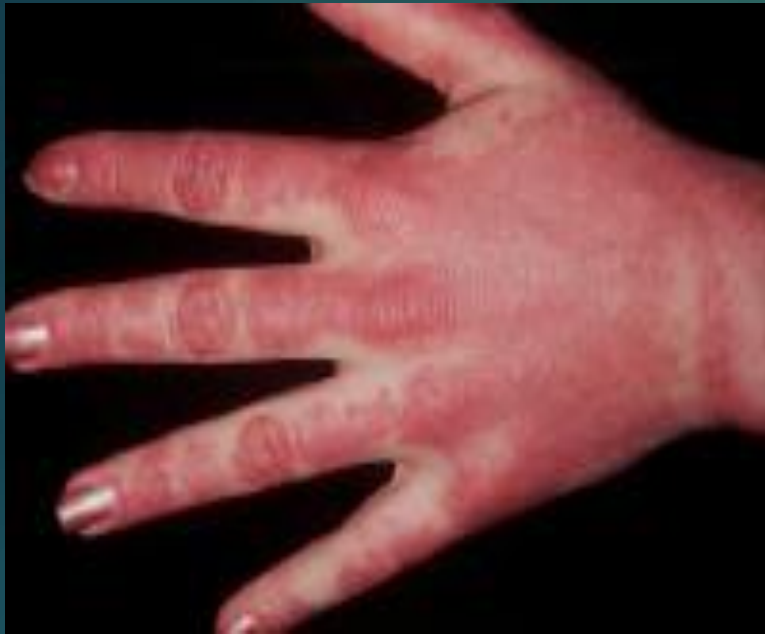



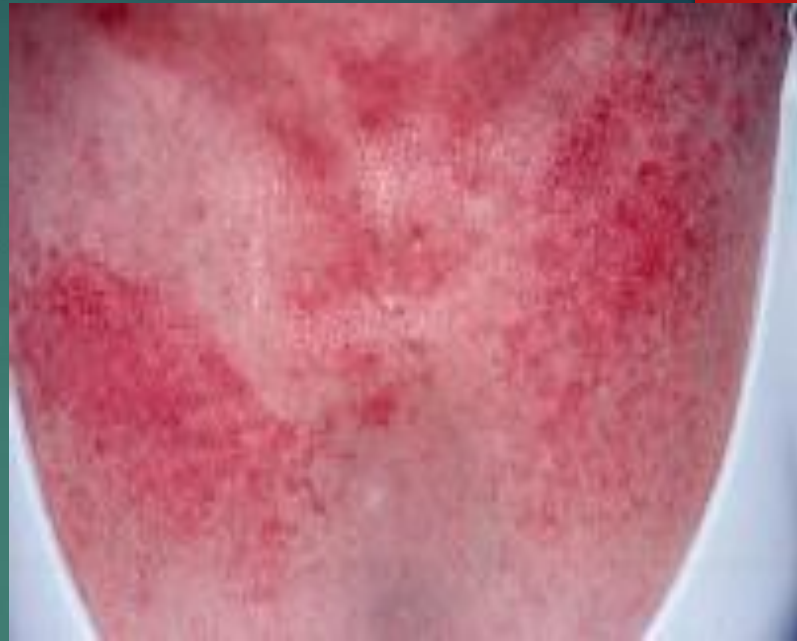Gottron papules and nail-fold telangiectasia



Calcinosis due to dermatomyositis in childhood




The lesions on the dorsal aspect of the hand demonstrate the photodistribution of dermatomyositis. Note the sparing of the interdigital web spaces.



Dermatomyositis is often associated with a poikiloderma in a photodistribution


Diagnosis


- *Raised circulating muscle enzymes: creatine kinase (CK) and sometimes aldolase, aspartate aminotransferase (AST) & lactic dehydrogenase (LDH).*
- *Antinuclear antibody (ANA) is found in most patients, specific Anti-Mi-1 is found in one quarter and Anti-Jo-1 in a few, usually those who have lung disease.*

- 
- Skin biopsy and biopsy of an affected muscle.
 - Electromyography (EMG) .
 - Magnetic resonance imaging (MRI) scan of muscles.

Clinical Management

- *Avoid sun exposure and use sun protective , including broad-spectrum sunscreens.*
- *Topical corticosteroids .*
- *Systemic corticosteroids with or without an immunosuppressive agent, for the cutaneous disease is often difficult.*

- 
- *Hydroxychloroquine and Methotrexate is also useful, mycophenolate mofetil , intravenous immune globulin .*
 - *Rituximab has been used for skin disease.*
 - *Aggressive early treatment of the myositis, particularly in children.*

- 
- *Malignancy evaluations for at least the first 3 years following diagnosis of dermatomyositis .*
 - *Women should be screened for ovarian cancer.*



THANKS

FOR YOUR ATTENTION