



LIBYAN INTERNATIONAL MEDICAL UNIVERSITY
Faculty of Dentistry

Comprehensive case presentation

Presented by: Nuhair Ahmed
No: 902

This work was achieved by the student: Nuhair Ahmed under the supervision of dental teaching staff at Libyan International Medical University:

- Rafik Alkwafi
- Abdelmonem Abdelnabi
- Asma Benhariz
- Malek Abdalmatloub
- Ali Busnaina
- Amal Elawamy
- Randa Alhassy
- khadiga Alfallah
- Seham Almarimi
- Nuha Alkadiki
- Masoud Daihoum

Patient information

- Name: M.S.E
- DOB :1986
- Occupation: Dermatologist
- Nationality: Libyan
- Sex : Female
- Address: Almajori

Chief complaint and history of chief complaint :

- **C.C :**

Patient complains of pain in her upper right back teeth since 2 days .

- **H.C :**

Pain started 5 months ago as mild localized intermittent pain related to her upper teeth aggravated by cold drinks and sweets lasts for 5mins, relived by warm water rinse, not disturbing her sleep ,non radiating nature not associated with any other symptoms.

Suddenly in last 2 days the pain become sever, throbbing, spontaneous, continuous pain, which increases with biting, and reduced by stopping of mastication (biting) associated with tenderness around the tooth and disturbing her sleep.

She didn't take any medication for it

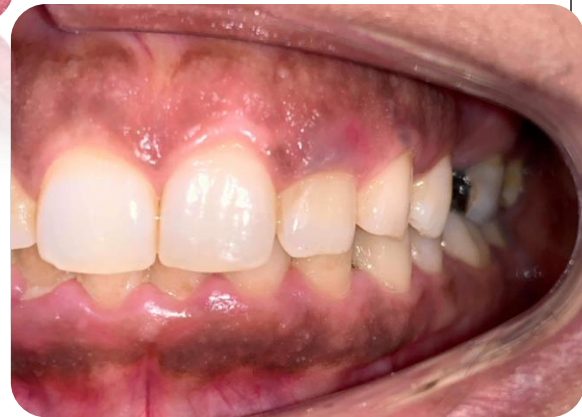
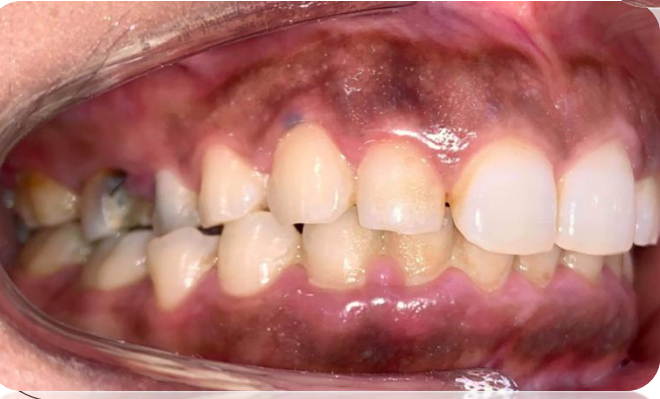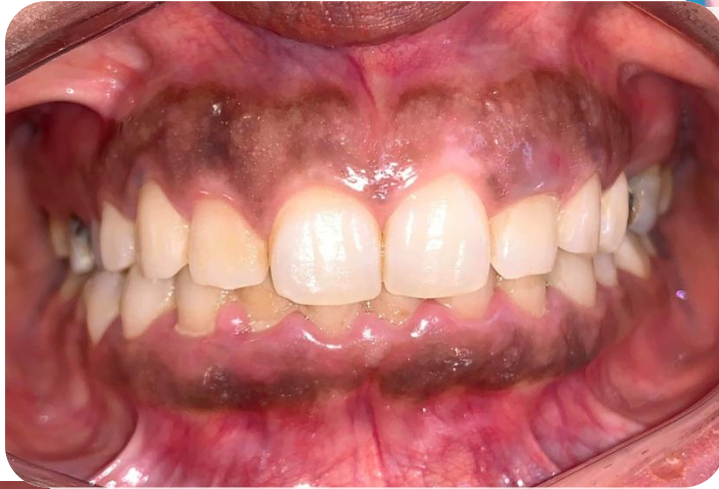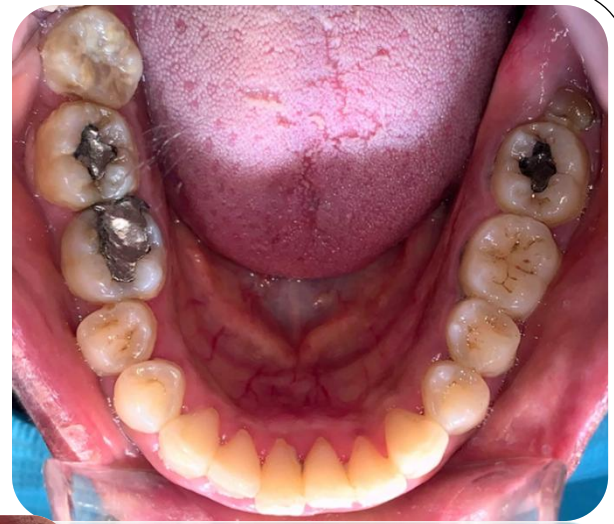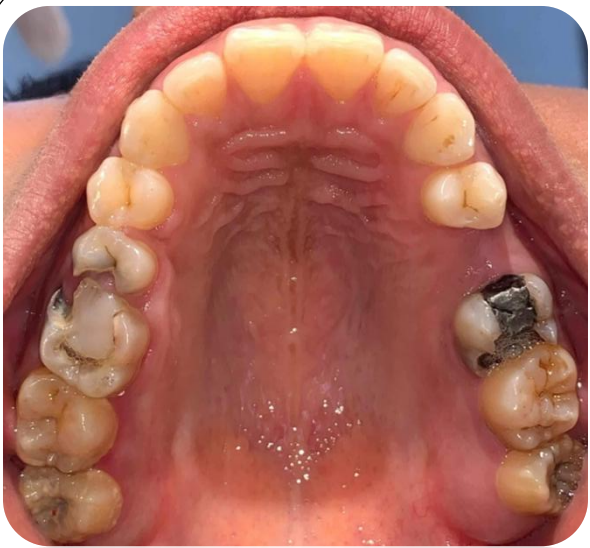- **Medical history** : N.O.S .
- **Drug history** : N.O.S .
- **Allergic history** : N.O.S .
- **Family history** : N.O.S.
- **Social history** : Single.
- **Dental history** : Brushes her teeth ones morning with soft brush , vertical technique ,No other methods of cleaning ,History of fillings , root canal treatment and uncomplicated extractions over 3years ago (destructed by caries).

Extra -oral examination

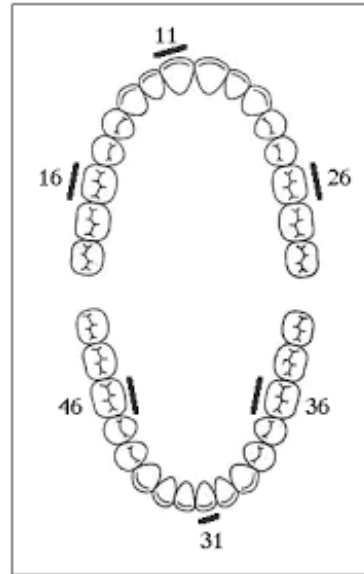
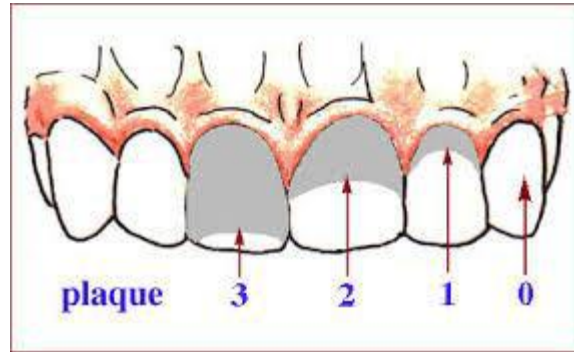
- Pt. is fit & healthy, with slightly asymmetrical face, no palpable neither tender L.N.
- TMJ examination reveals no clicking, crepitations, limitation or deviation of mouth opening, with no masticatory muscles tenderness.
- The Lips are competent.

Intra-Oral Examination:

- No halitosis
- Tongue : Normal
- Cheek : Normal
- Floor of the mouth : Normal
- Oral mucosa : Physiological pigmentation



Intraoral examination hard tissue



16	11	26
1		
1	1	1
46	31	36

16	11	26
1		1
1	1	1
46	31	36

Plaque index : 4/6

Calculus index : 5/6

Fair (1.3-3)

$$\text{OHI+S} = 0.6 + 0.8 = 1.4$$

Dental Chart

8	7	6	5	4	3	2	1	1	2	3	4	5	6	7	8
D		RC	D									M	RC	D	D
D	RC	RC												RC	

DMFT 8

Bruxism

Clinical examination for the offending tooth revealed decayed tooth with gingival polyp . Which is tender to vertical percussion and tender to palpation.

5

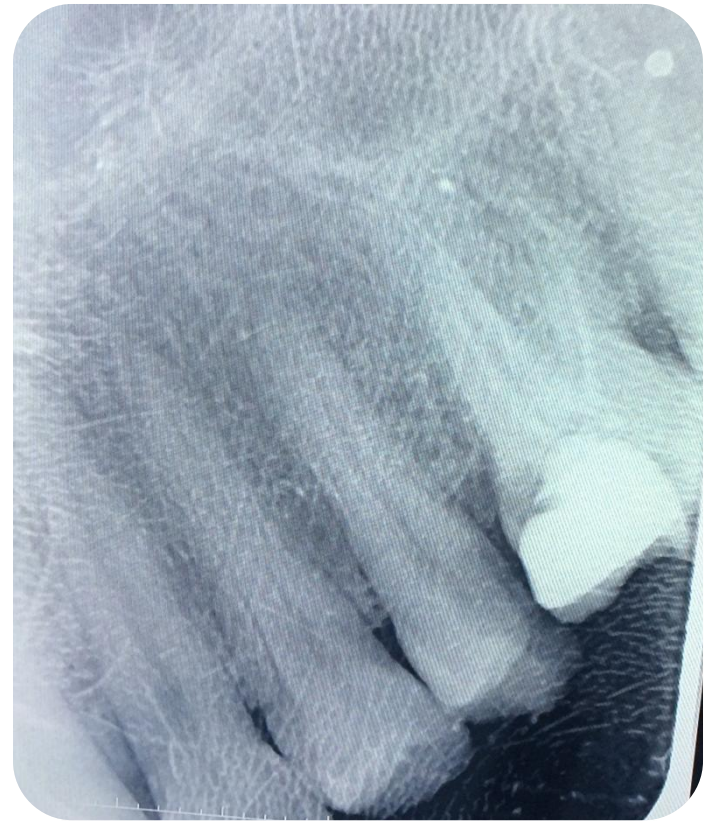Differential Diagnosis of Chief Complaint: (15)

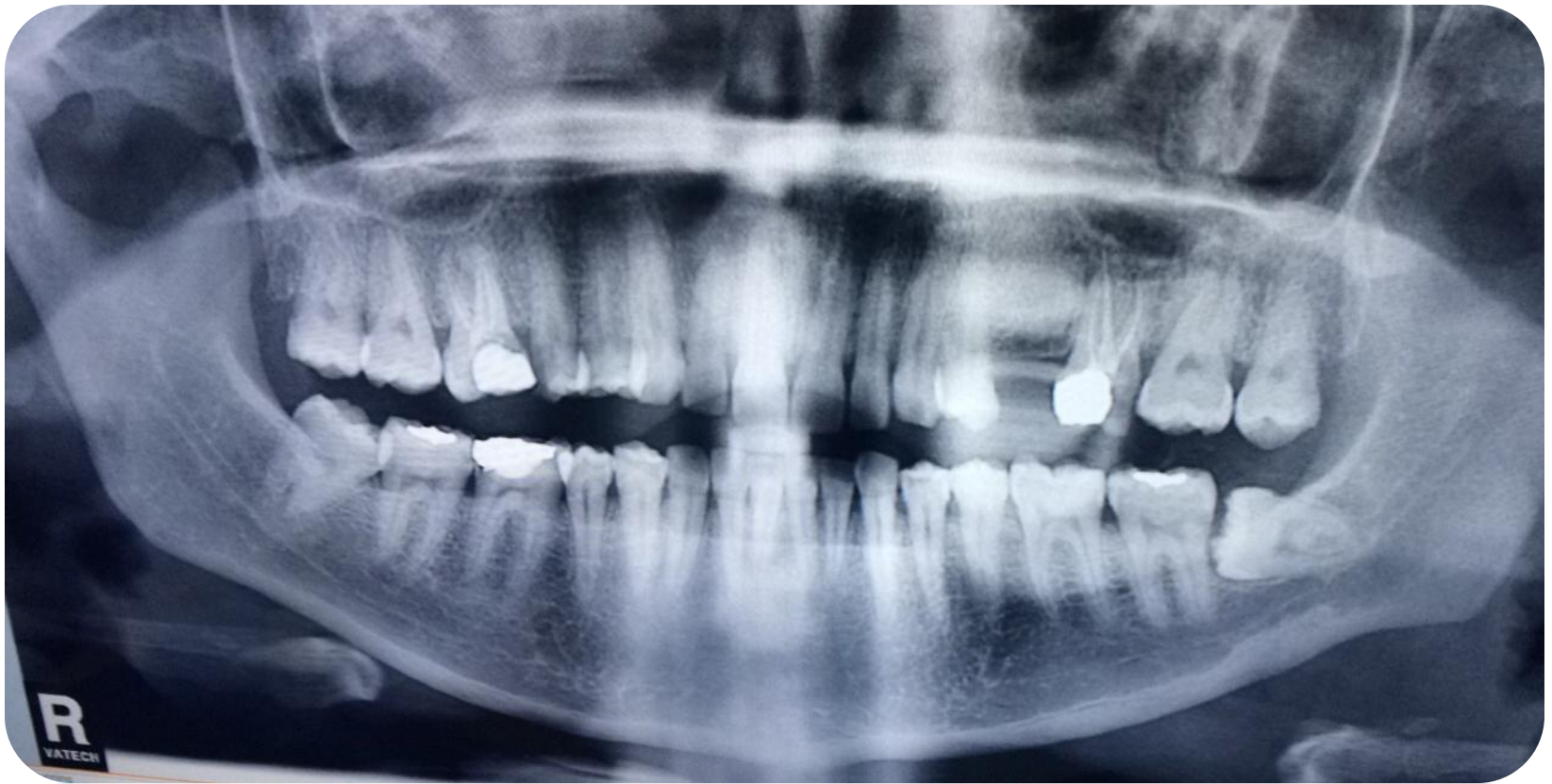- Acute periapical periodontitis \ abscess.
- Acute exacerbation of chronic periapical abscess \ periodontitis.

Investigation

Intraoral periapical radiograph:

Show upper right 3,4,5 and 6 related to patient chief complains (5) large radiolucent area in the distal side of the crown reached to the pulp with slightly loss of lamina dura.





Orthopantomogram Radiograph Examination:

- Showing maxillary and mandibular teeth
- localized mild horizontal bone loss related to (16-26-27).
- multiple restorations and multiple endodontically treated teeth
- Missing tooth
- Impacted tooth

Gingival status

	Left	Anterior	Right
Color	Pink with physiological pigmentation in both man and max	Man reddish pink with physiological pigmentation	Pink with physiological pigmentation in both man and max
Contour	Scalloped round margin blunt IDP	Scalloped round margin blunt IDP	Scalloped round margin blunt IDP
Size	Normal	Man Enlarged	Normal
Consistency	Firm and resilient	Man soft and Edematous	Firm and resilient
Stippling	Absent	Max present Man absent	Absent
Position	Max at CEJ Man coronal to CEJ	Max coronal to CEJ Man coronal to CEJ	Max at CEJ Man coronal to CEJ
Bleeding on probing	Present max	Present max and man	Present max

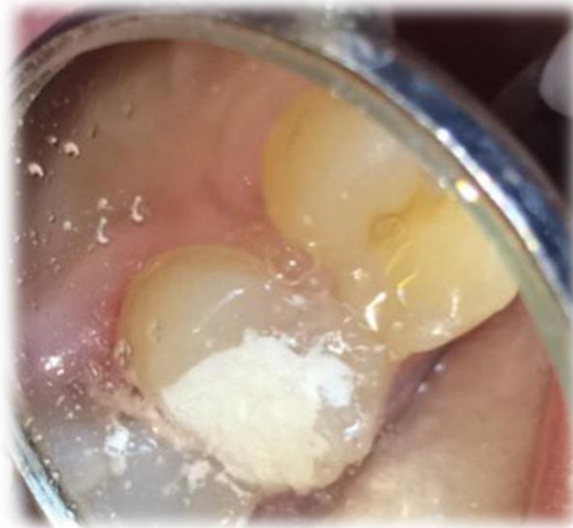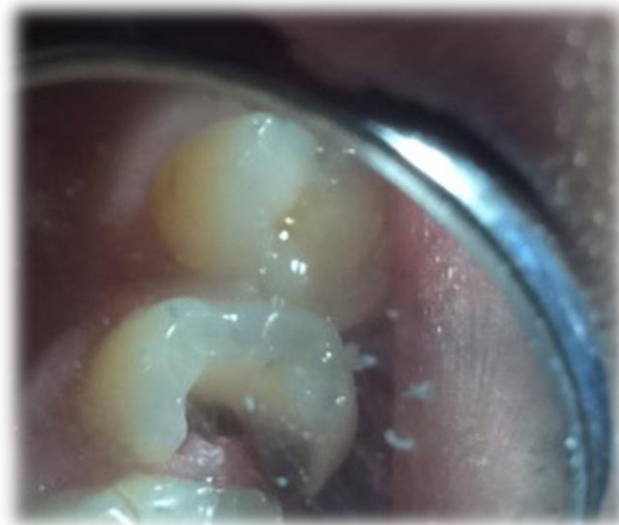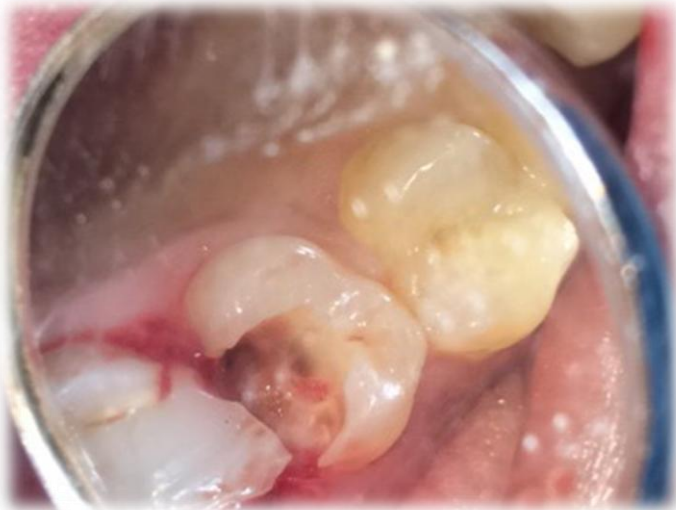
Final diagnosis

- Acute exacerbation of chronic periapical peridontitis (15).
- Decayed teeth (18-16-26-27-28-37-46-47-48).
- Localized mild chronic peridontitis .
- Missing tooth (25)

Treatment plan

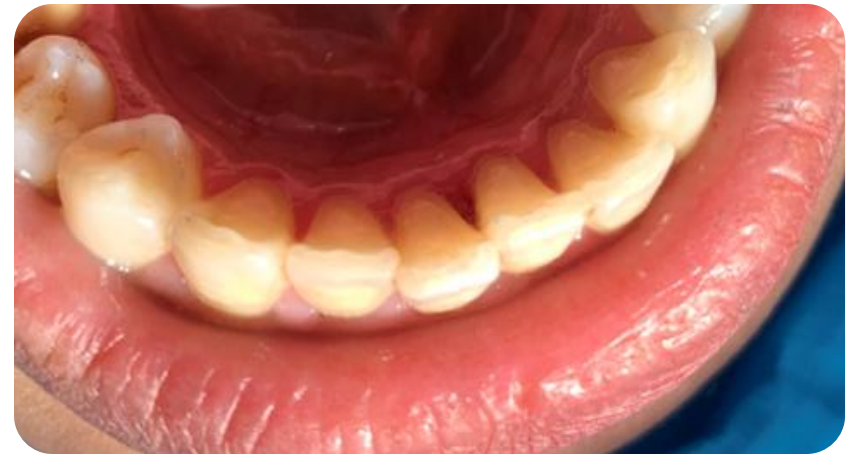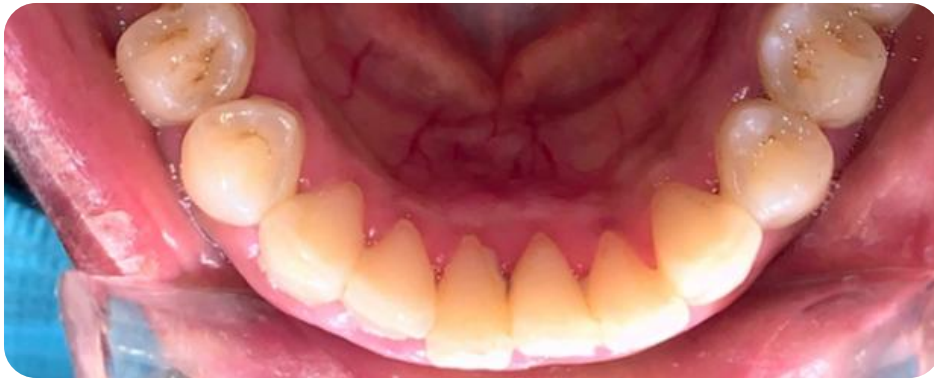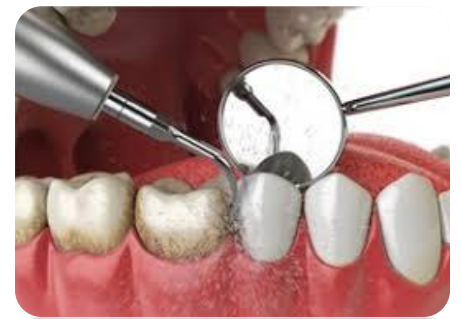- **Emergency phase** : Pulp extirpation (15).
- **Phase I** : O.H instruction ,diet sheet,scaling & root planning.
Pit and fissure sealant for (14-17-24-34-35-36-44-45).
Night guard
Reevaluation of phase I
- **Phase II** : Extraction of impacted 8.
- **Phase III** :Restoration (18-27-28-37-47-48).
RCT(46)
Retreatment (16-26).
Post ,core and Crown for RCT teeth.
Replacement of (25) : Implant
Bridge
RPD (Kennedy class III).
- **Phase IV** : Maintenance after 2-3 months then every 6 months.

Emergency phase:



Phase I Therapy :

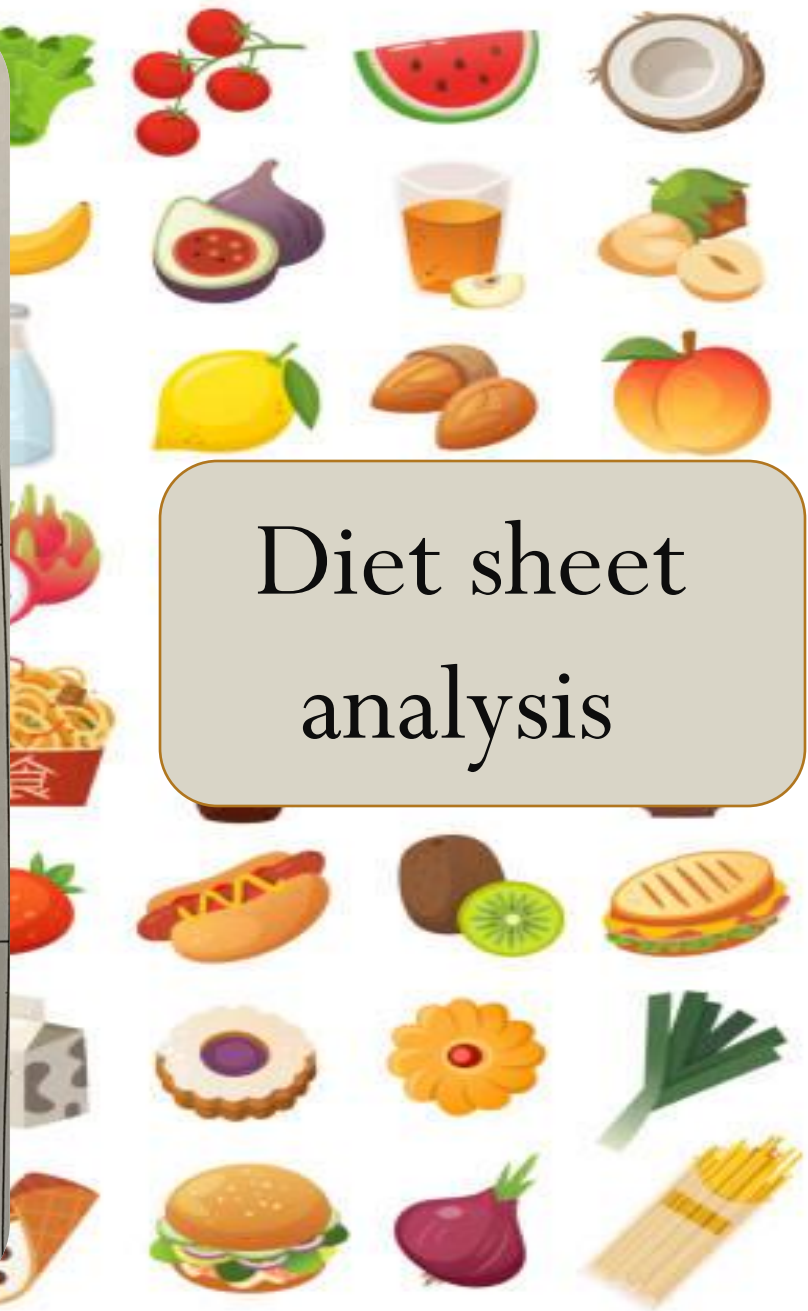
- O.H instruction, diet sheet ,full pridontal chart, scaling & root planning and Reeevaluation of phase I.



Patient Name: [REDACTED] Gender: M/F Date of Birth: 1986
 Occupation: [REDACTED] Address: [REDACTED]

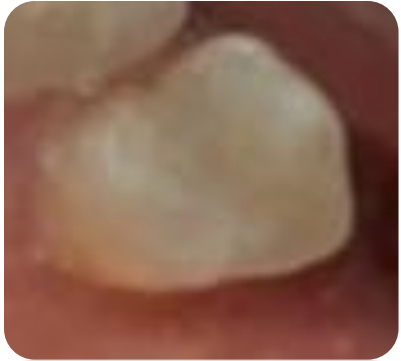نوع الوجبة	المأكولات والمشروبات	الساعة	الأيام
فطور عشاء عصيره	نشاينه - كيتة - كوب ماء غسل الأسنان مكرونه - دجاج - سلاطه - قازوزه قهوة - مقرنحس + ماء دخن تن - خيس غسل الاسنان بعد العشاء	8 2 5 9	الخميس
فطور عشاء عصيره عشاء	نشاينه - بطولم - غسل الاسنان بعد الاظفار دخن جبه كسطو - محشس - سلاطه قهوة - بسبوسة - ماء بيترزا + قازوزه غسل الاسنان بعد العشاء	8 10 2 6 10	الجمعة
فطور عشاء عصيره عشاء	قهوة - كيتة - ماء غسل اسنان طيفه بطاطا - خبز - سلاطه بريوش - نشاينه فول وطعمية وكيسر - سلاطه غسل اسنان بعد العشاء	9 2 5 9	السبت

Diet sheet analysis

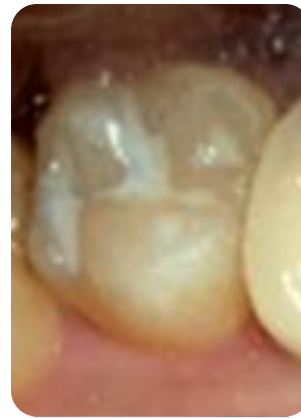
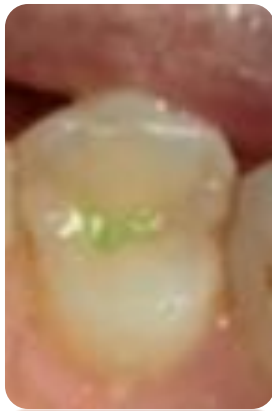
Revaluation phase

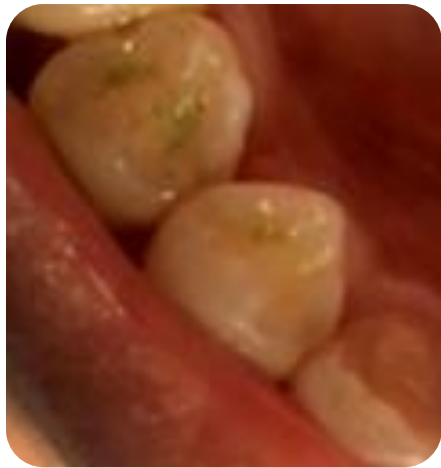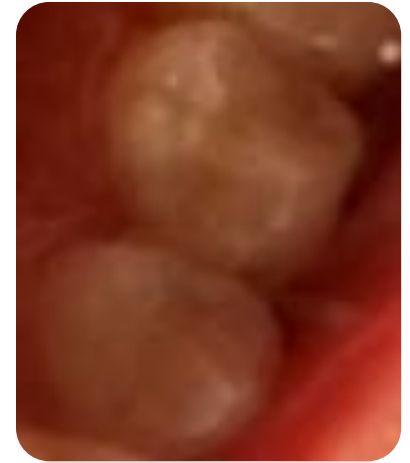
- P.t was satisfied and the inflamed gingiva is decreased.
- No plaque or calculus present .
- Probing depth is decreased .
- Attachment lose is decreased.



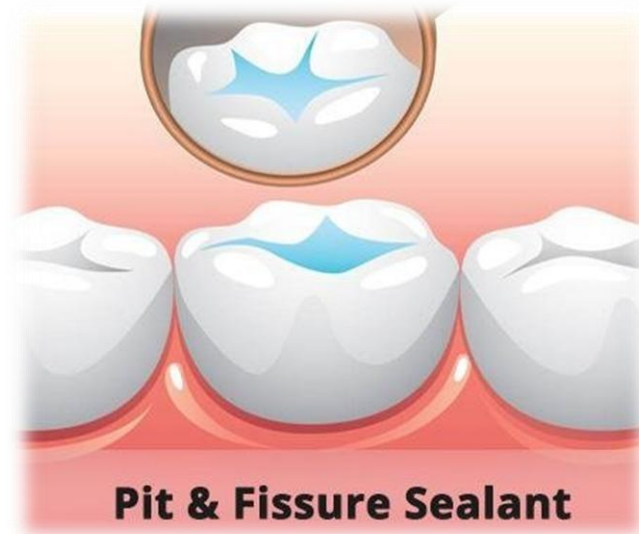UL(4)



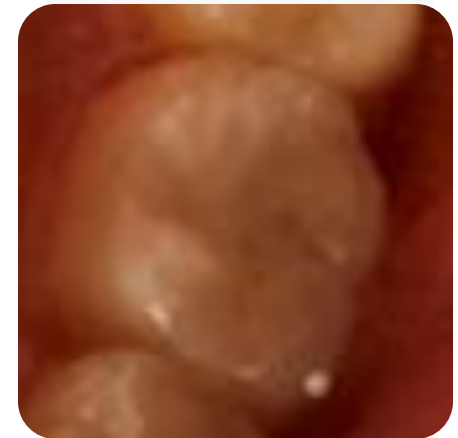UR(4-7)



LR(4-5)



Pit & Fissure Sealant



LL(4-5-6)

Phase II

REFUSE

- Extraction to impacted LL8.
- P.t refused the ttt plan, she won't to extract the tooth after explaining possible complication that may occur after extraction.

الجامعة الليبية الدولية للعلوم الطبية
كلية طب وجراحة الفم والأسنان
موافقة للأذن بالعلاج

أقر أنا /
بموافقتي الفضية والكتابة للبدء والاستمرار في العلاج بعادات كلية طب الأسنان بالجامعة
الليبية الدولية للعلوم الطبية والذي يتضمن

وقد تم شرح التشخيص المرضي لحالتي والخيارات المختلفة المتوفرة لمعالجتها والأعراض الجانبية والمخاطر التي قد
تصاحب العلاج والمشاكل التي قد تنتج عن عدم العلاج والمدة التقريبية اللازمة لانتهاء منه والتكلفة الإجمالية للعلاج
وفقا للرسم الرمزية المقررة كما اتفهم ان هذا العلاج قد تم تنفيذه من قبل طالب أو طبيب امتياز تحت الاشراف المباشر
لأعضاء هيئة التدريس بالكلية

اسم المريض:
توقيع المريض:
اسم الطالب أو طبيب الامتياز:
الأستاذ المشرف:
التاريخ: 2019/5/5

Phase III

Part 1 Restoration of carious teeth .

RCT for the complaining tooth (15).

Retreatment for (16-26).

RCT for(46) .

Filling for (18-27-28-37-47-48).

Part 2 Post core crown for the RCT teeth.

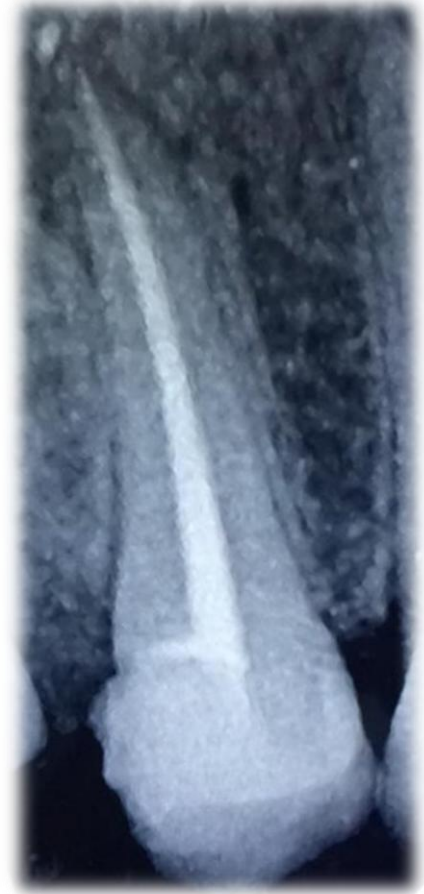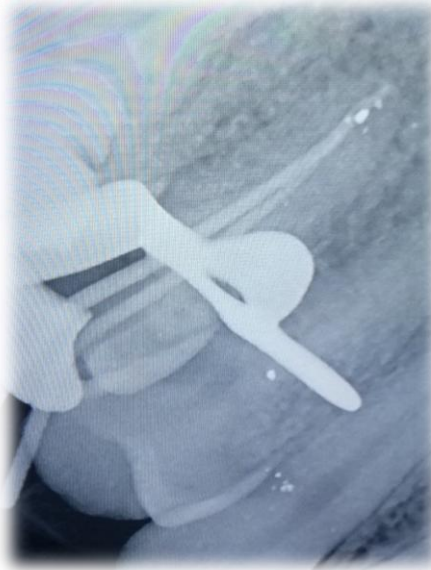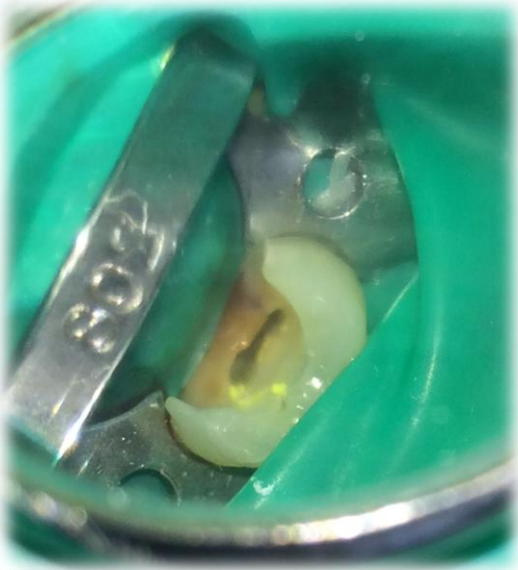(15-16-26-46).

Replacement for (25) : implant

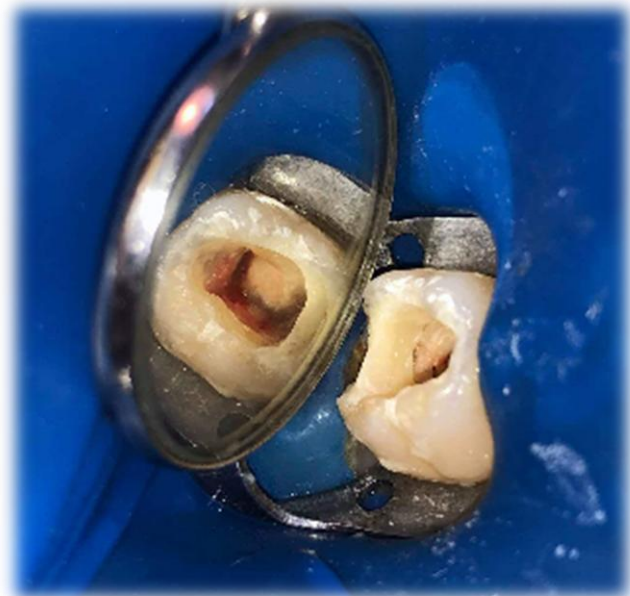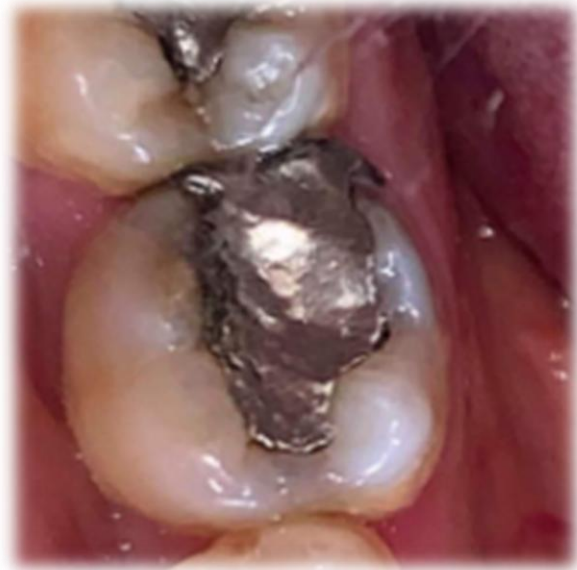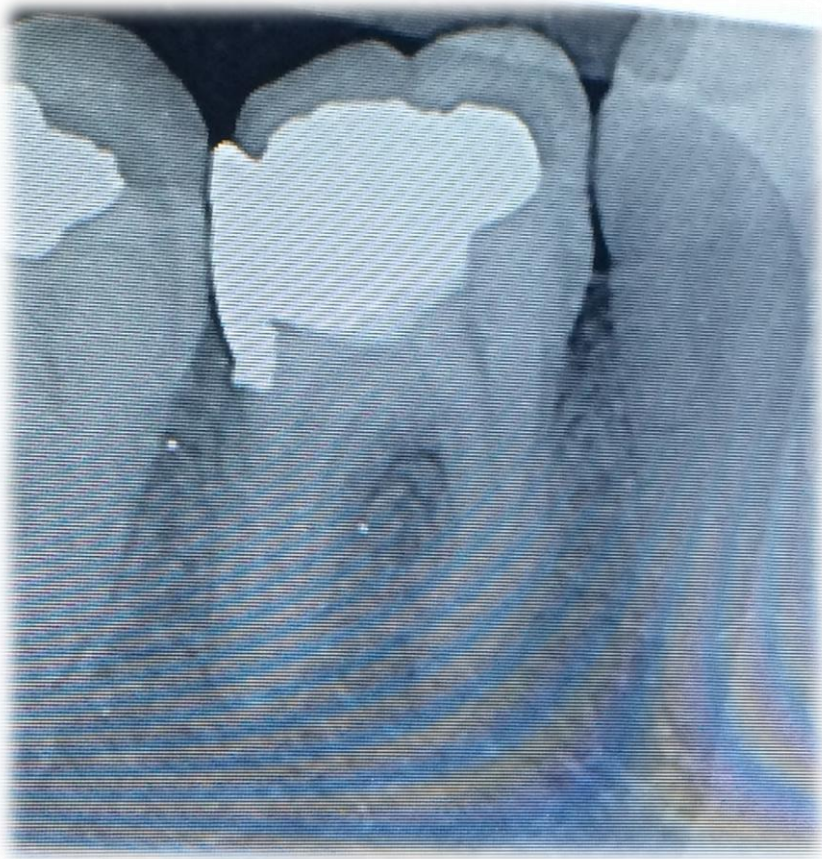
bridge

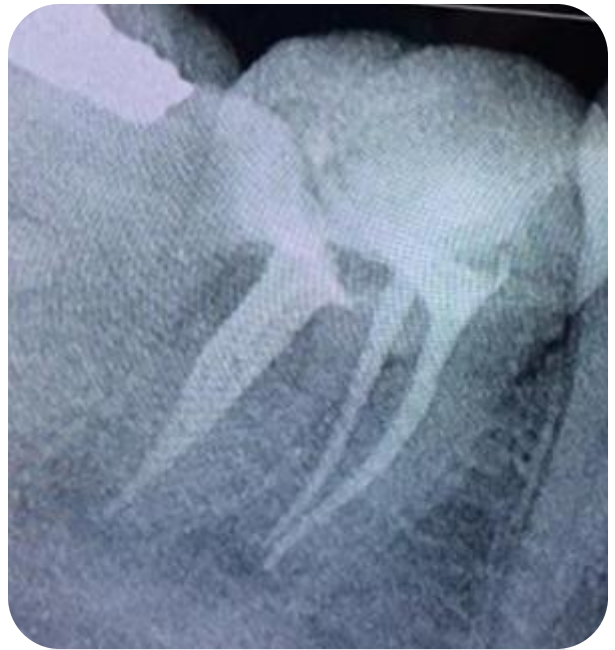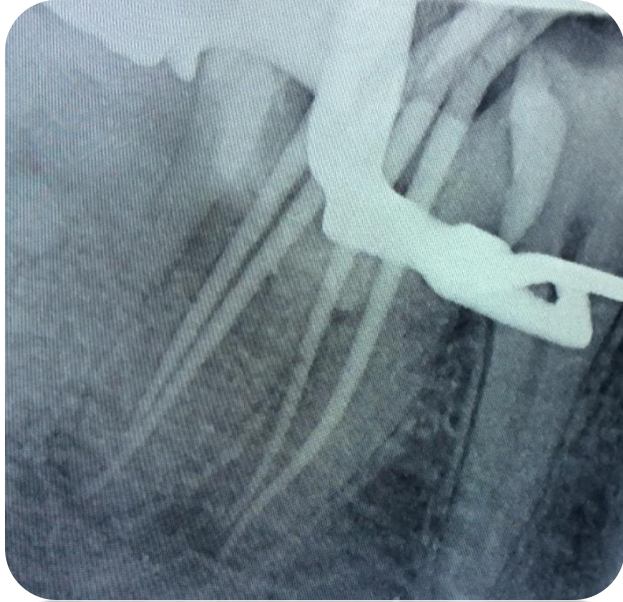
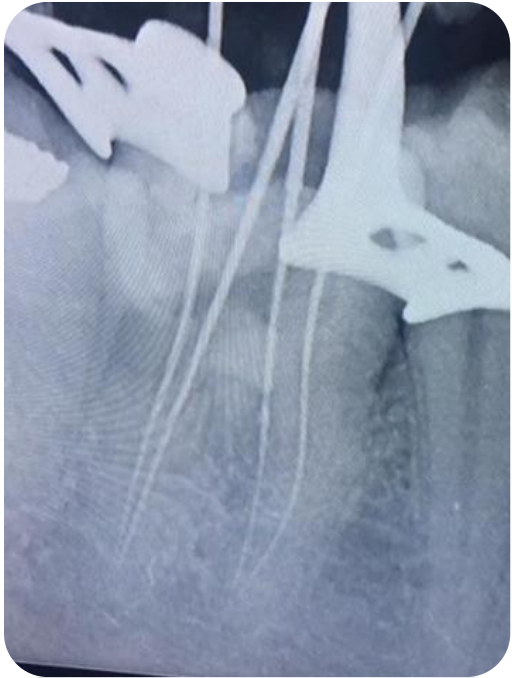
RPD

RCT for (UR5)

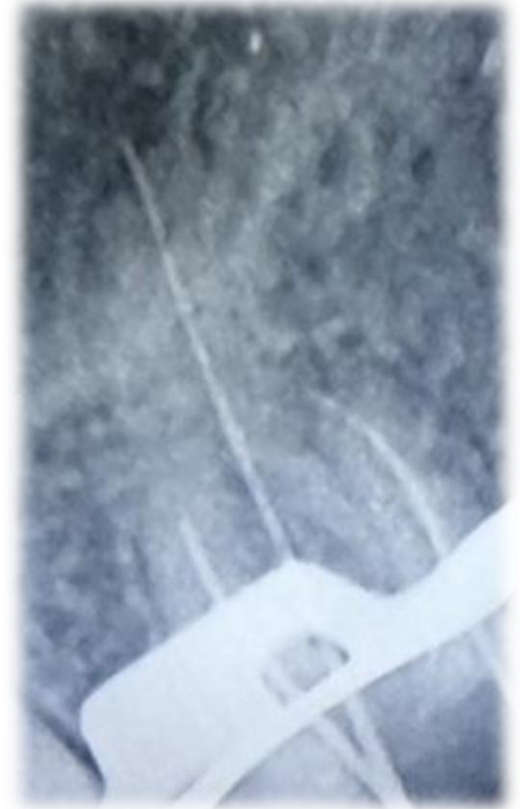
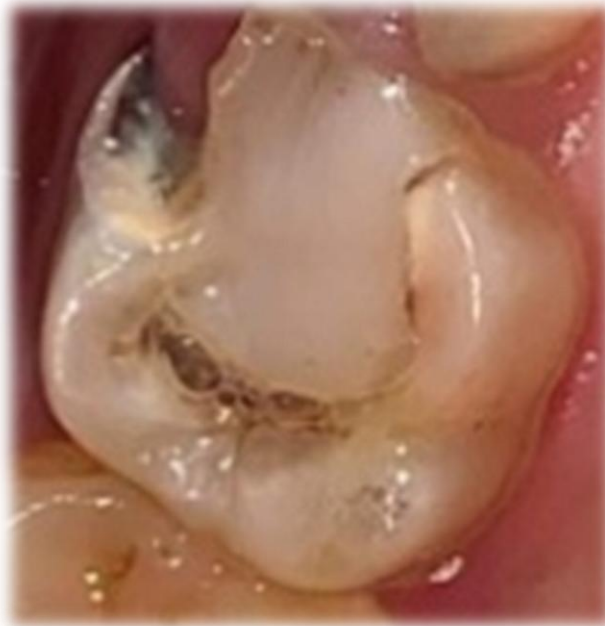
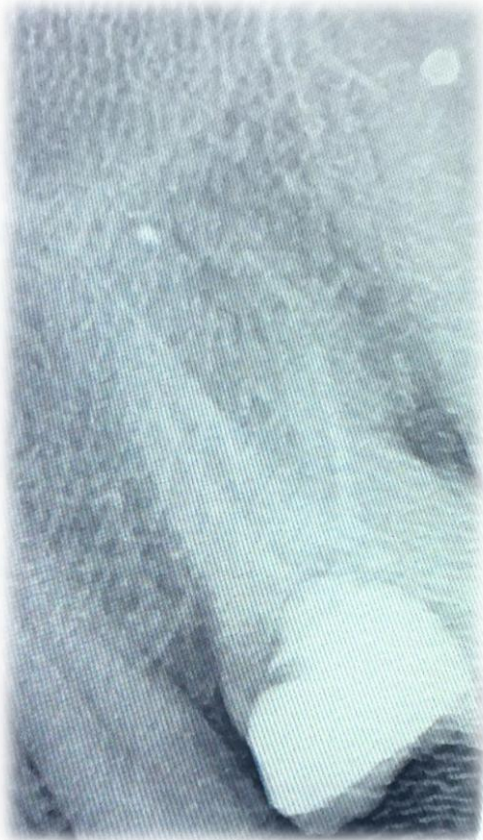

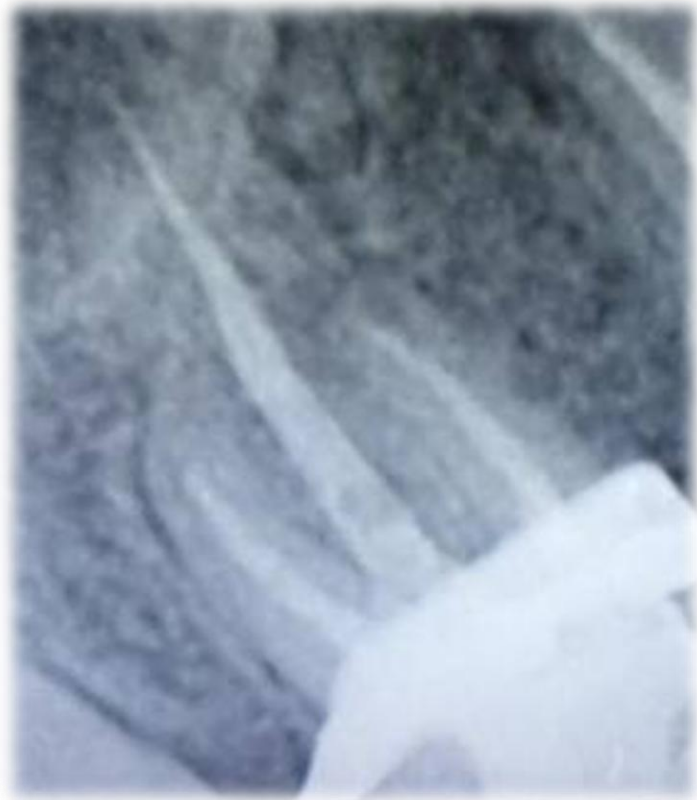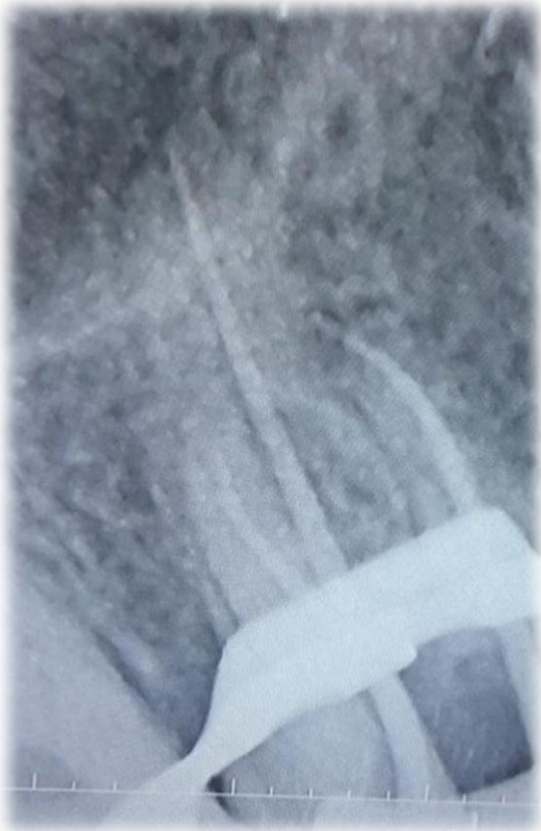
RCT for (LR6)



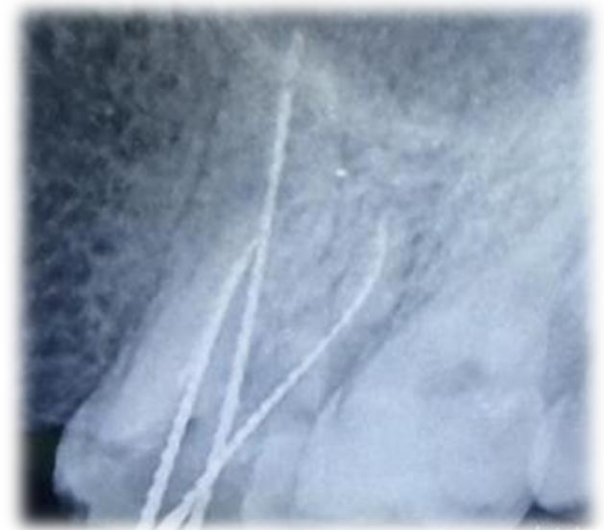
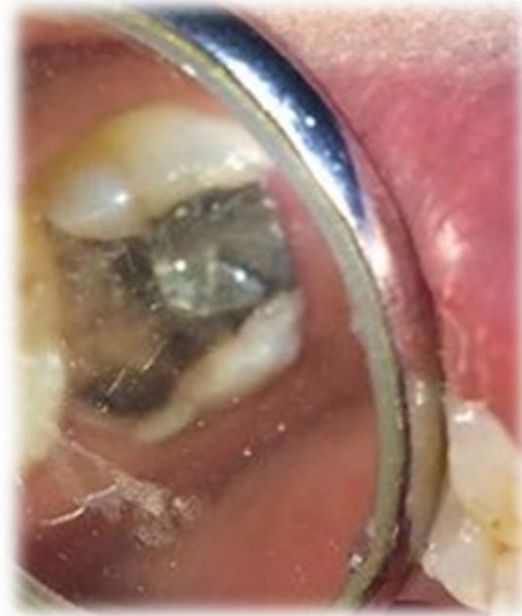
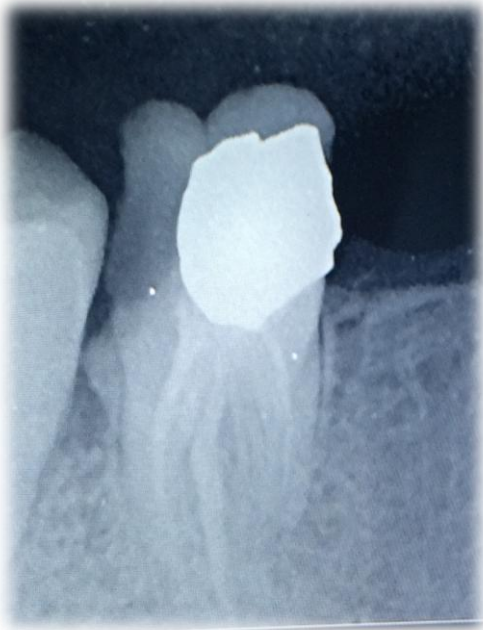
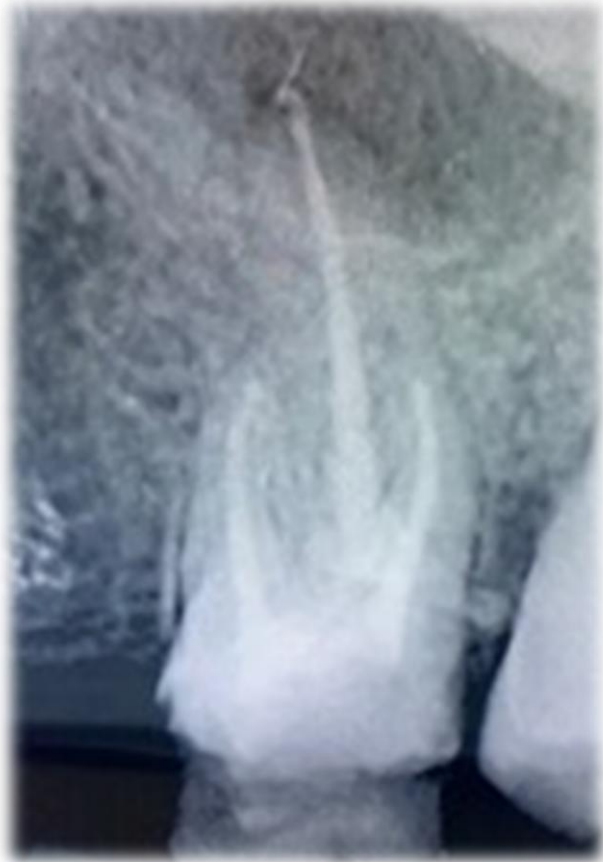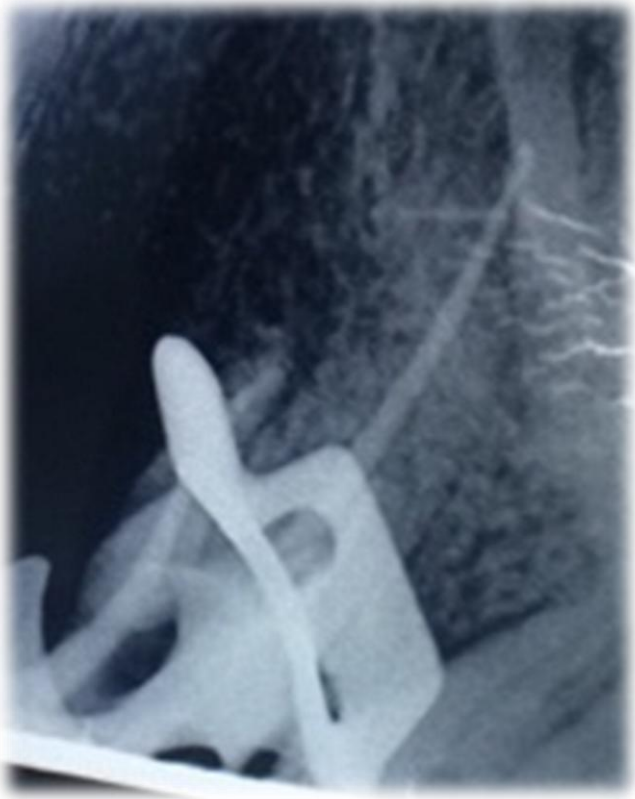Retreatment for (UR6)



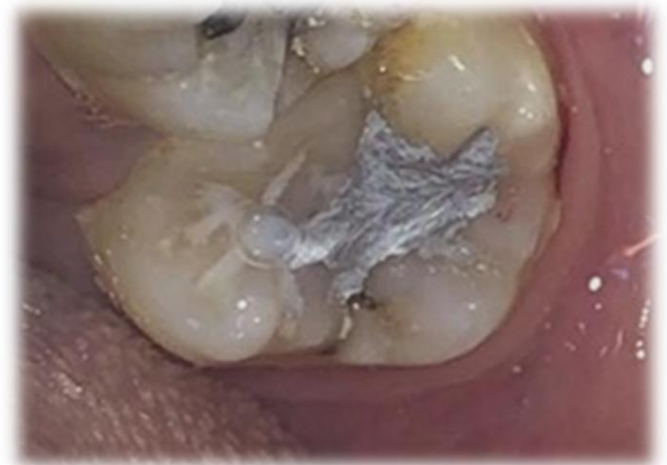
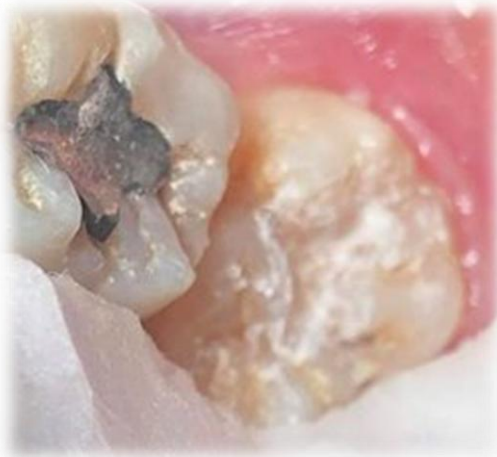
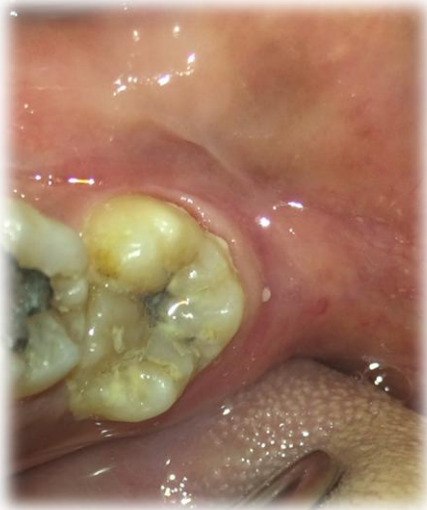Retreatment for (UL6)

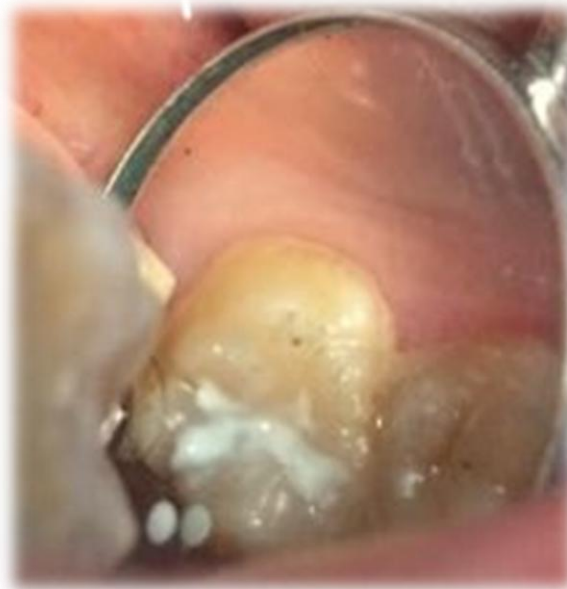
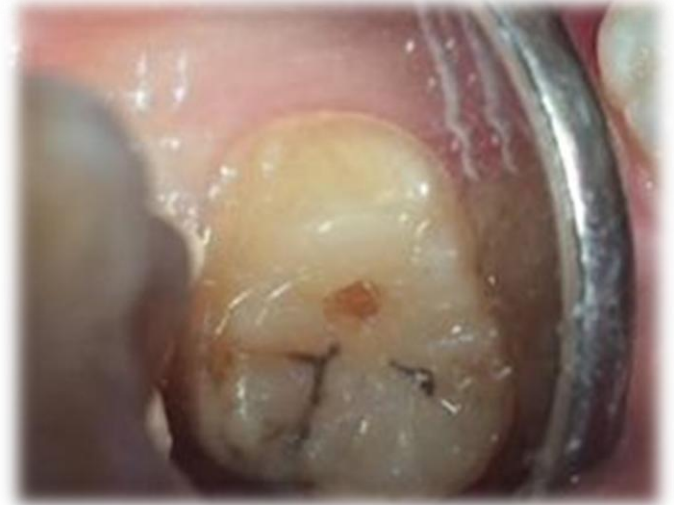
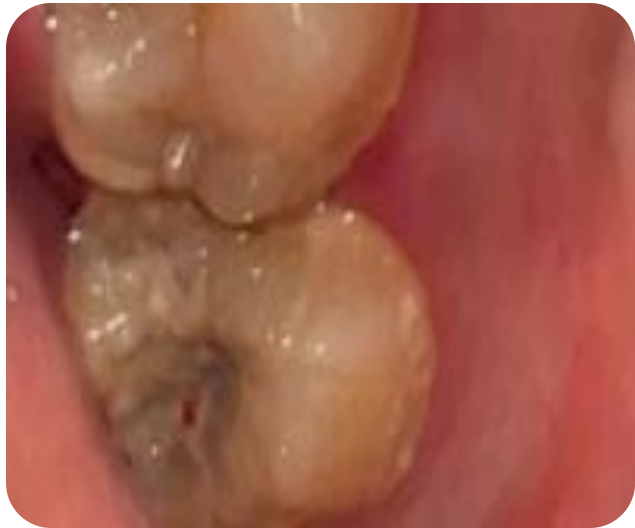

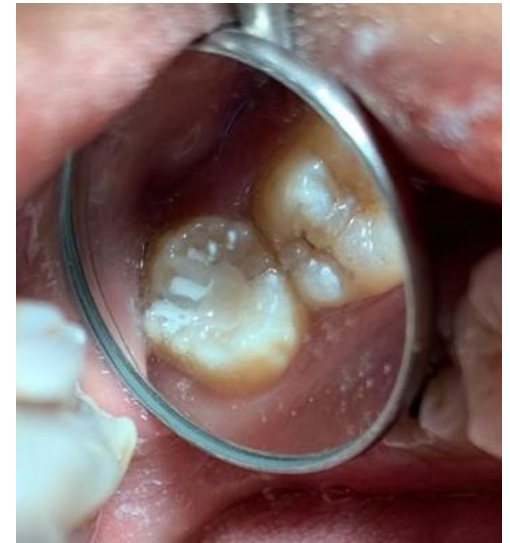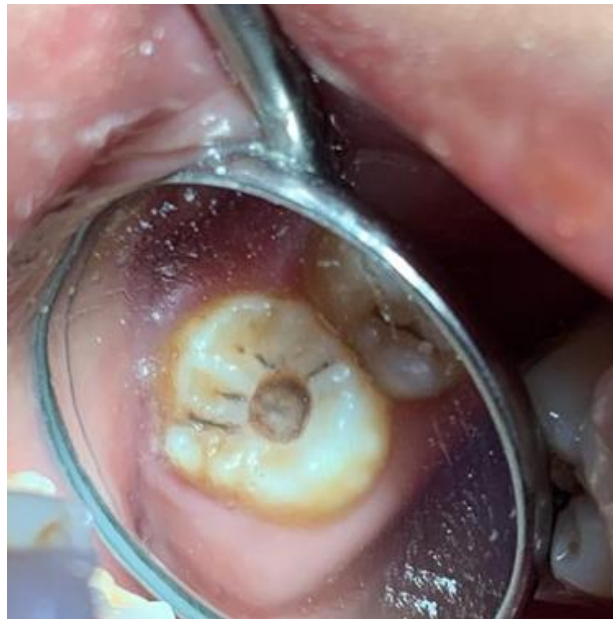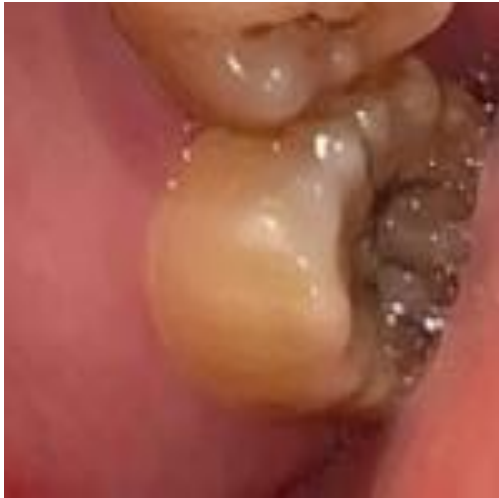Restoration for (LR8)



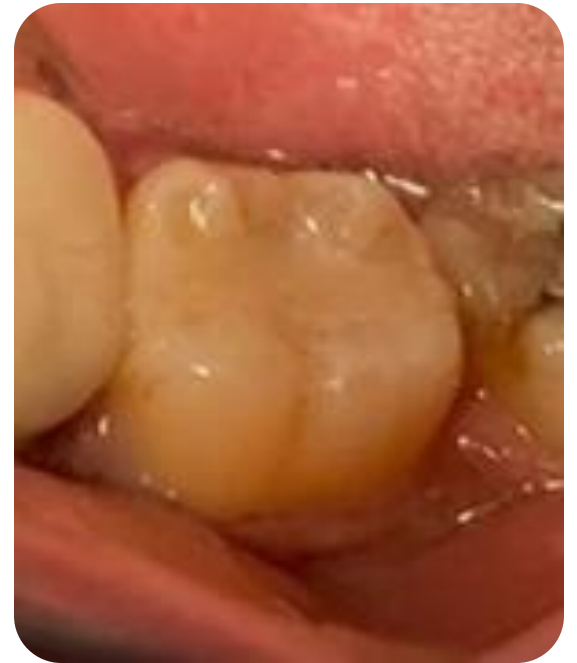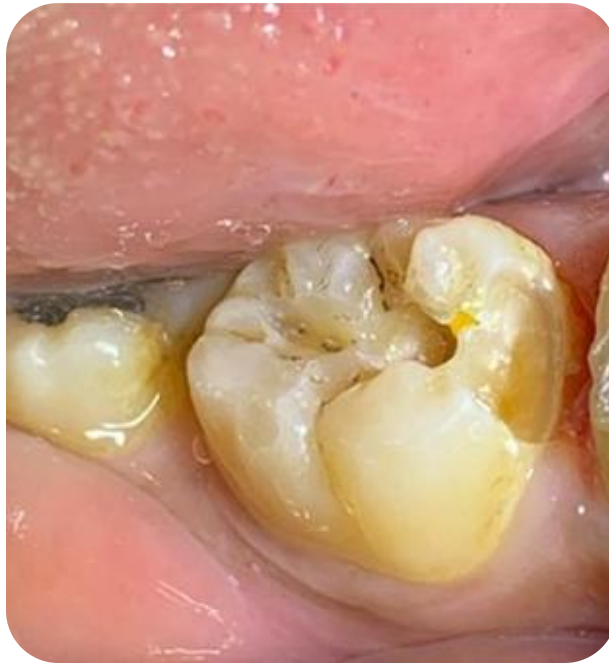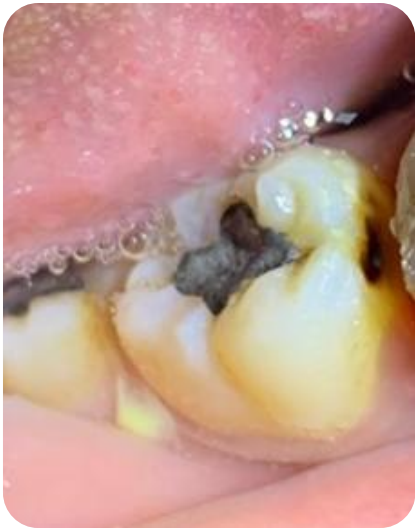Restoration for (UR8)



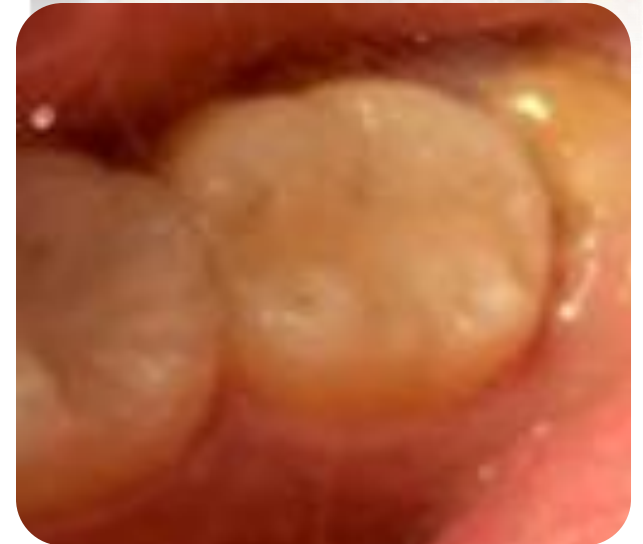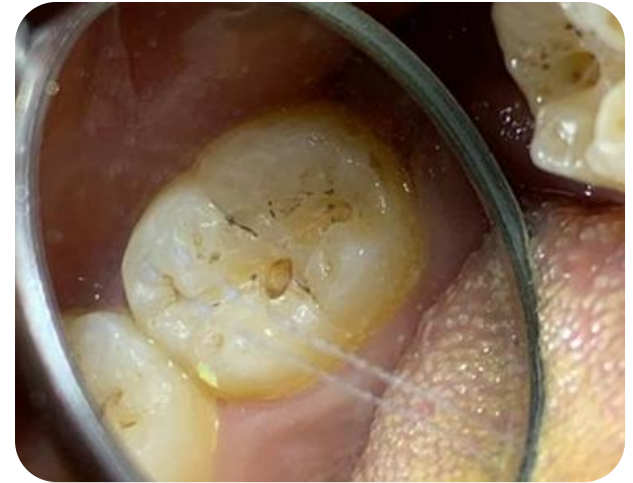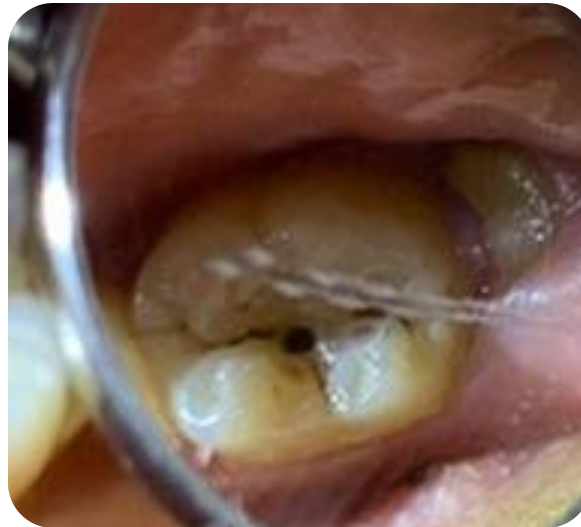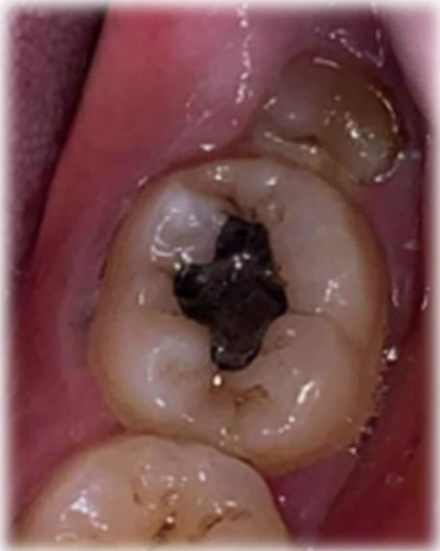Restoration for (UL8)



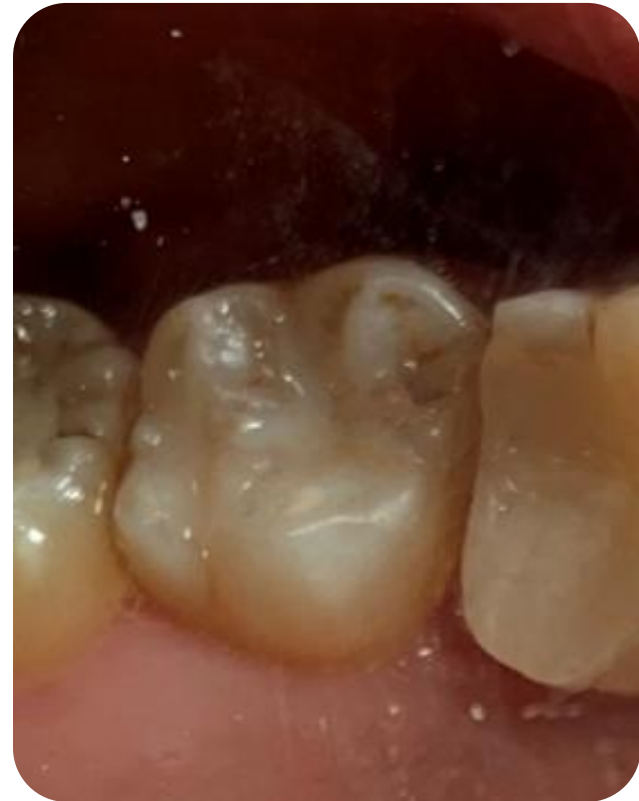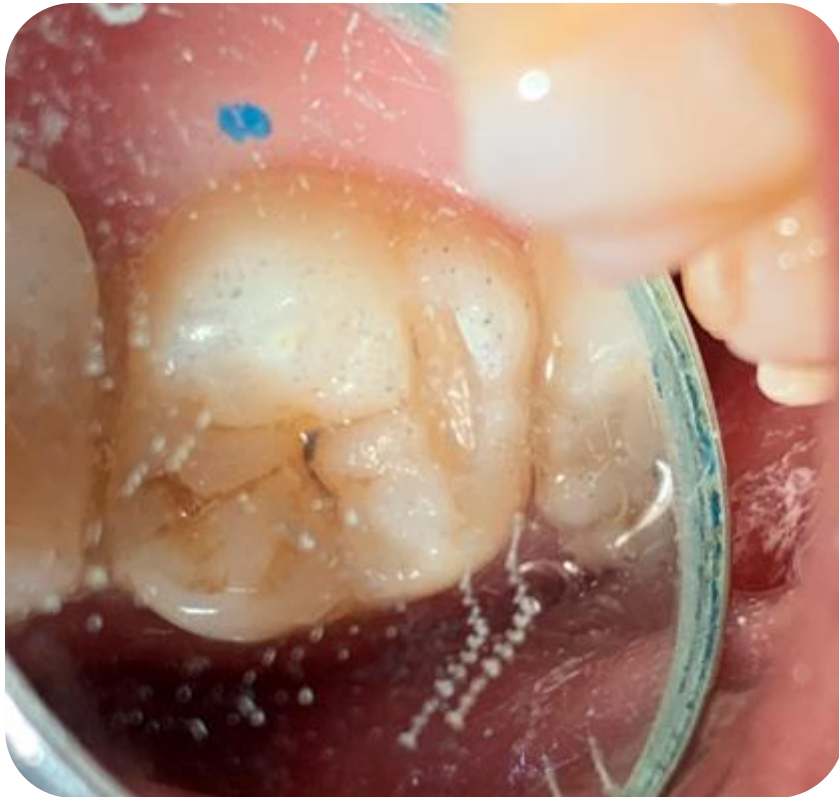Restoration (LR7)



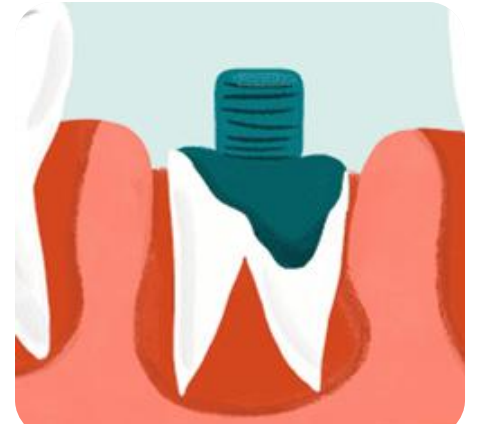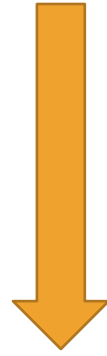
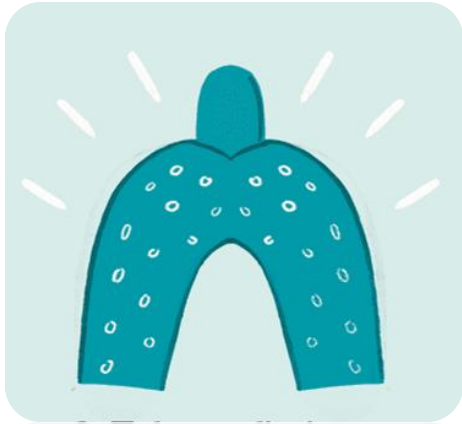
Restoration (LL7)



Restoration for (UL7)



Post-core and crown for

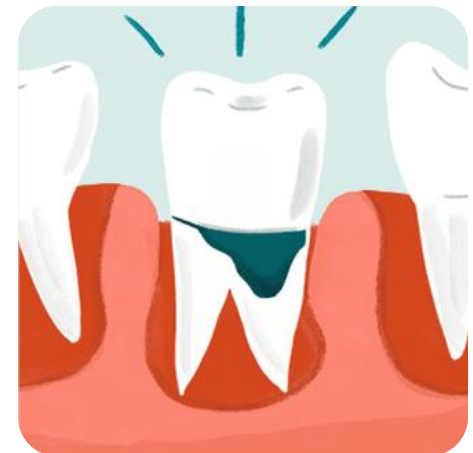
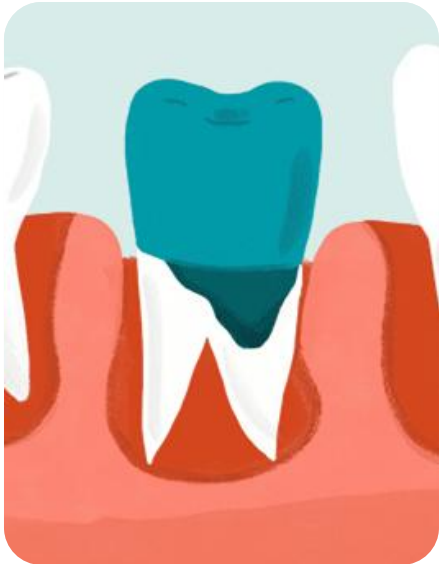

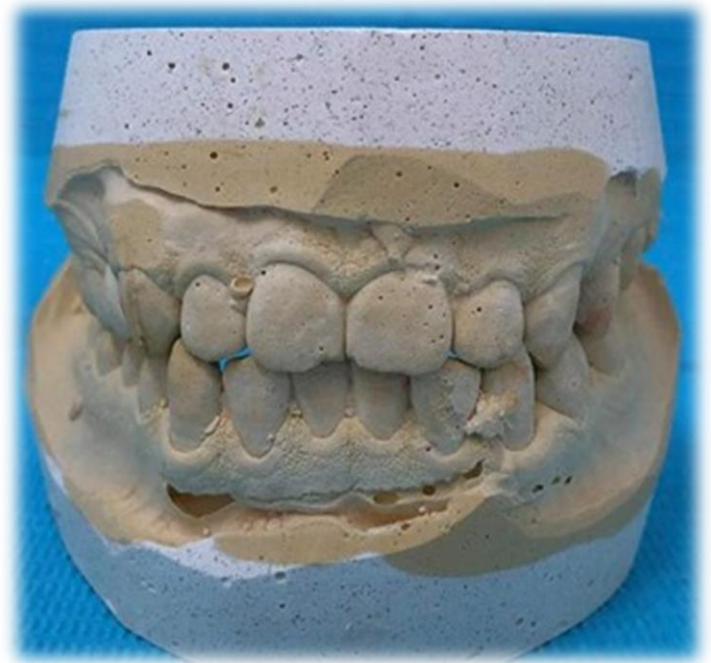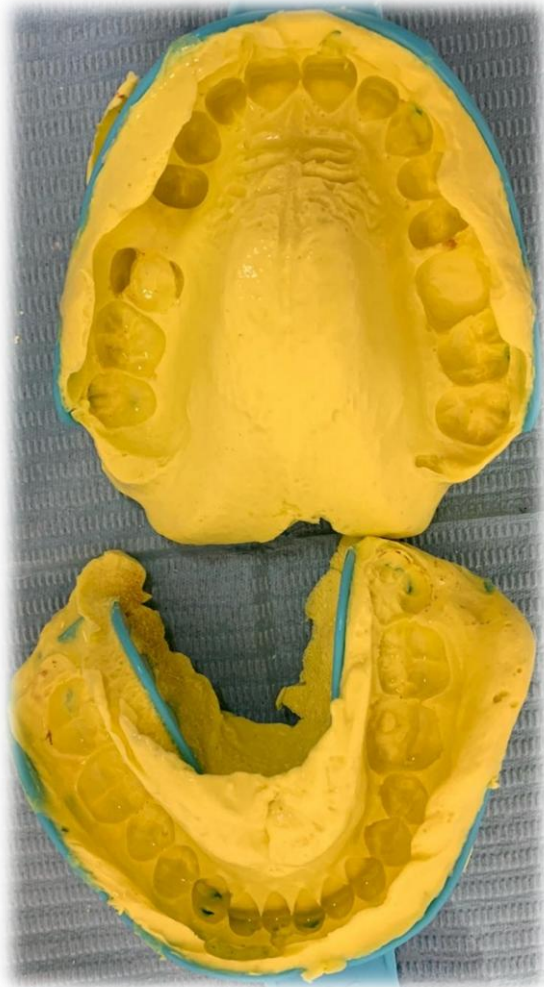
UR5-6 , UL6 and LR6

(PFM type)



But UR5 was TTP

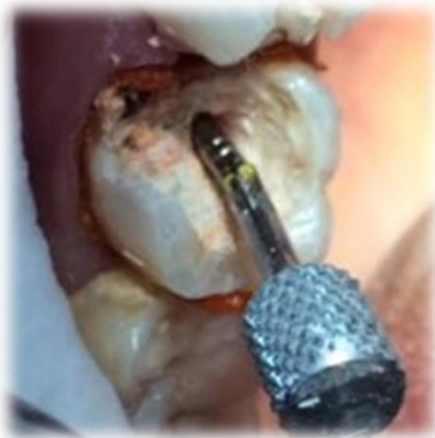
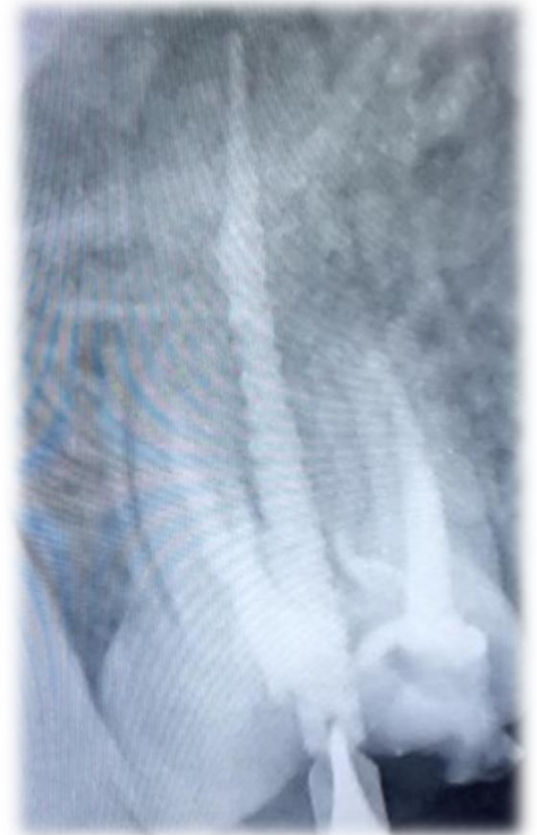
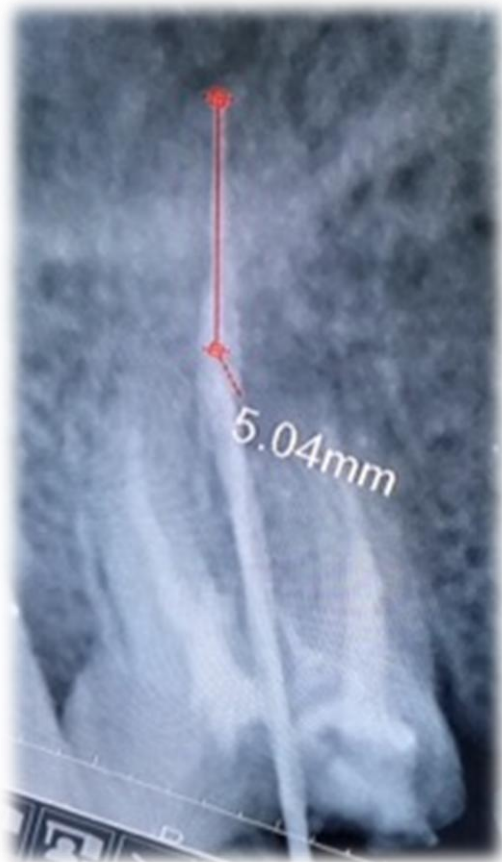



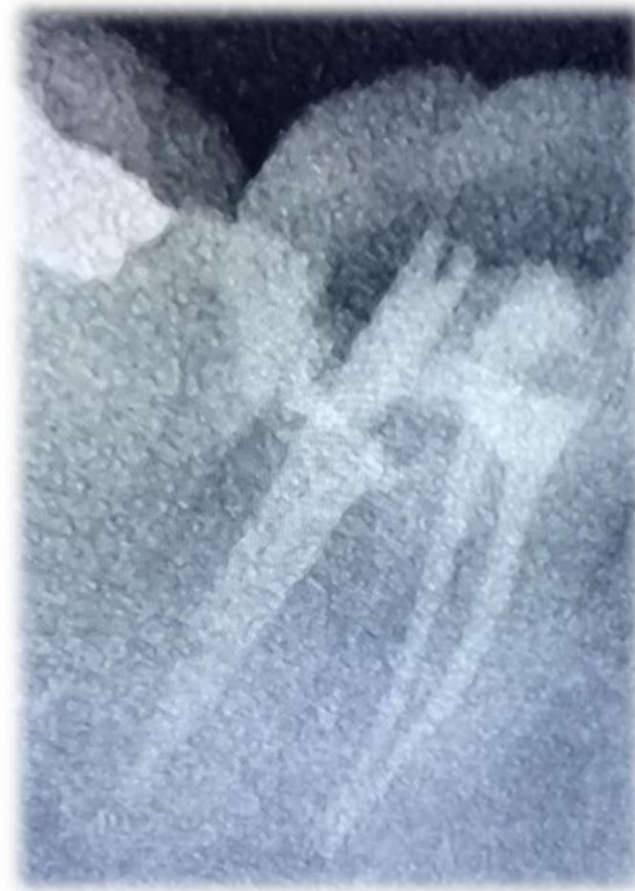
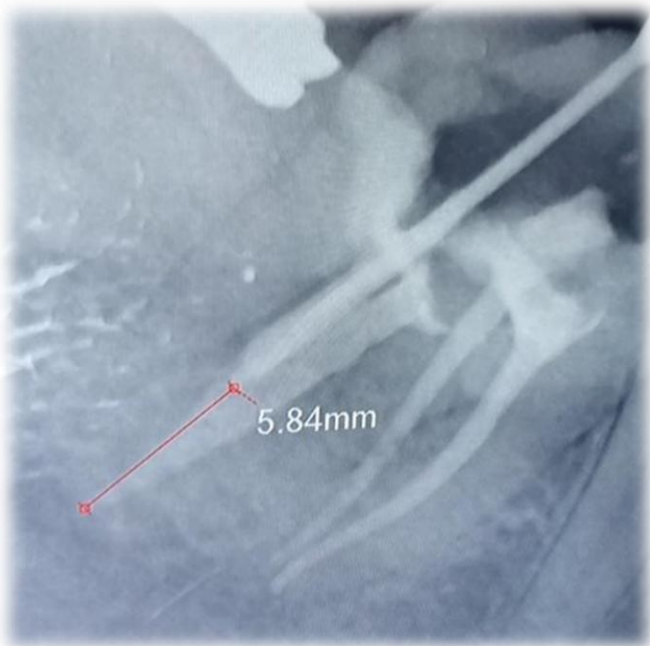
Primary impression

Diagnostic cast

Post preparation for UR6



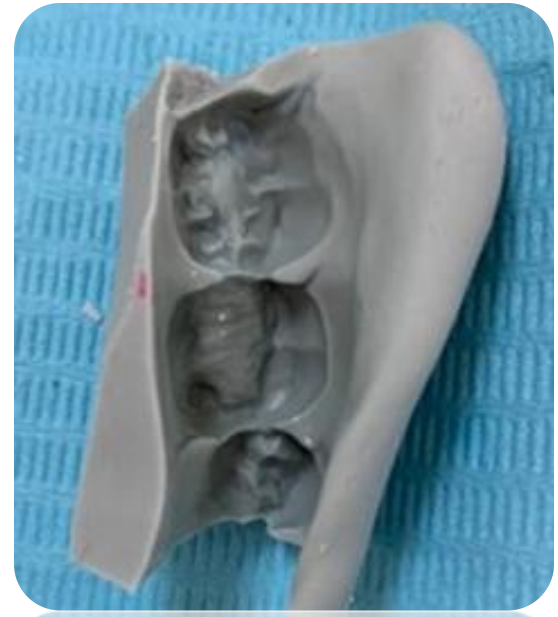Post preparation for LR6



Putty index

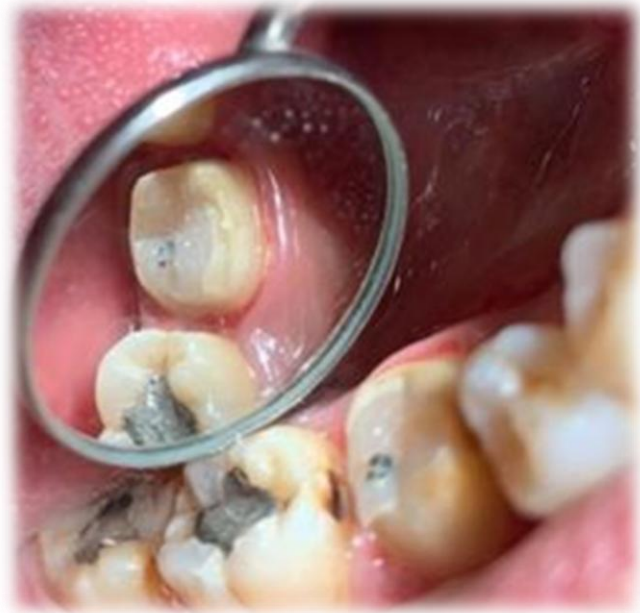
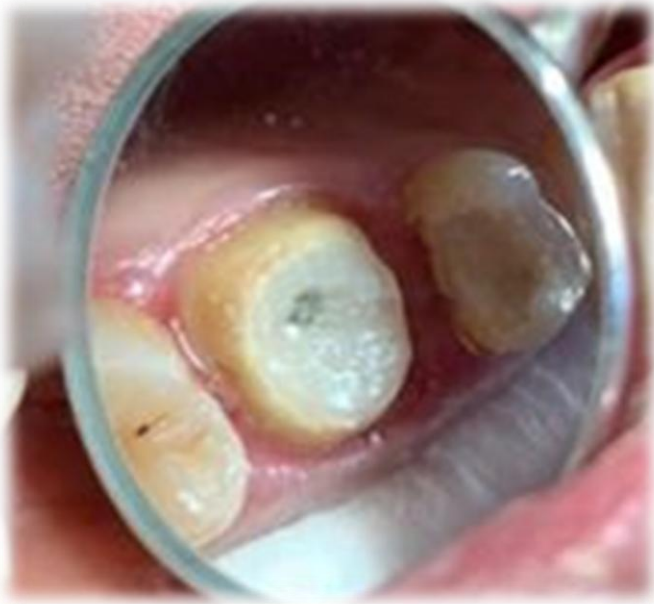
UR6

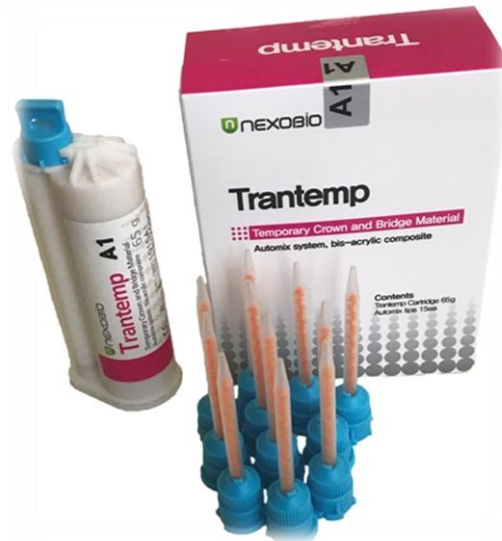
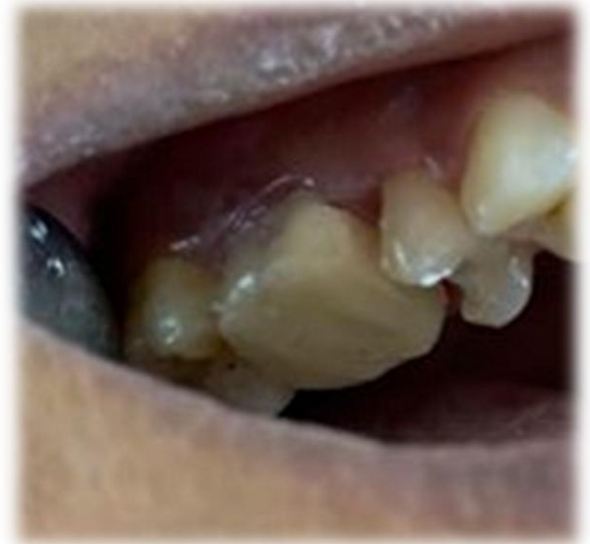
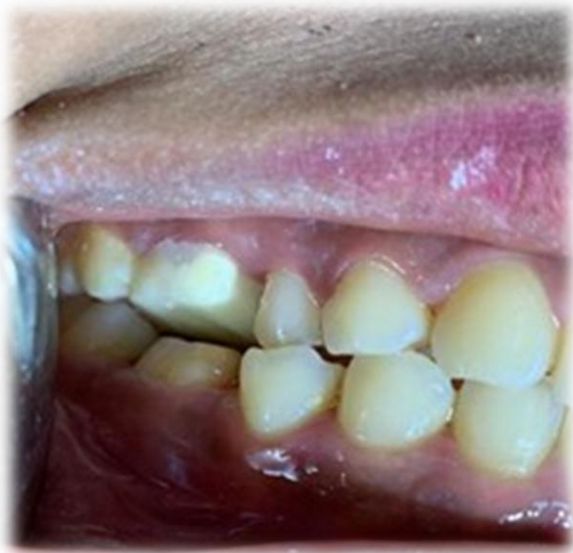LR6

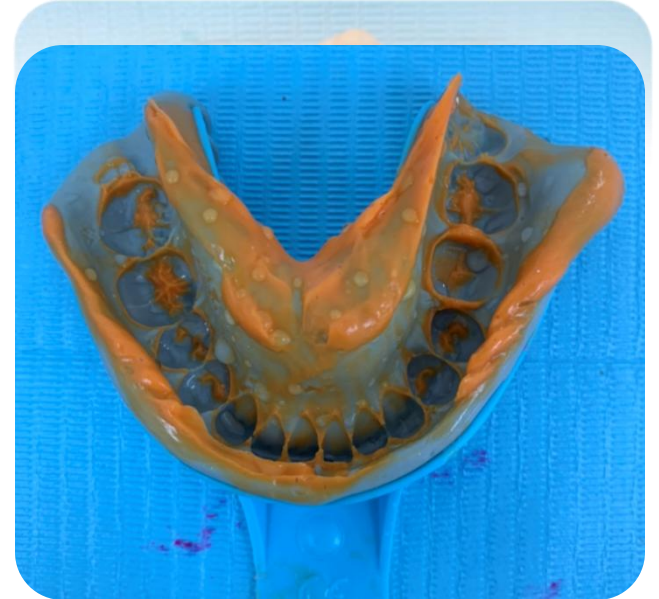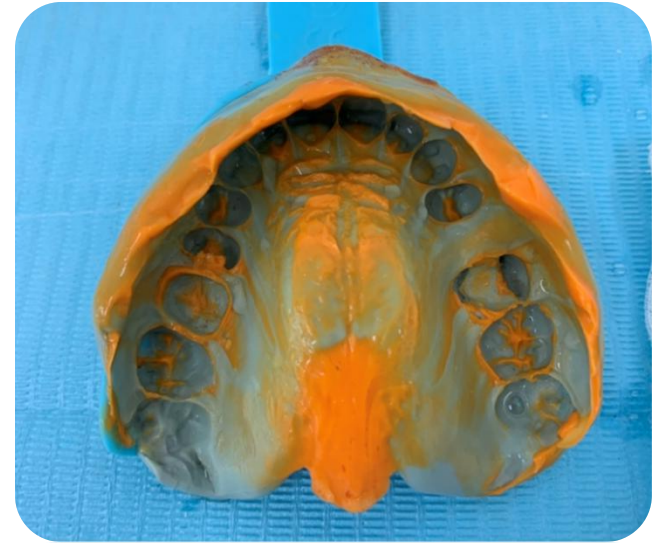
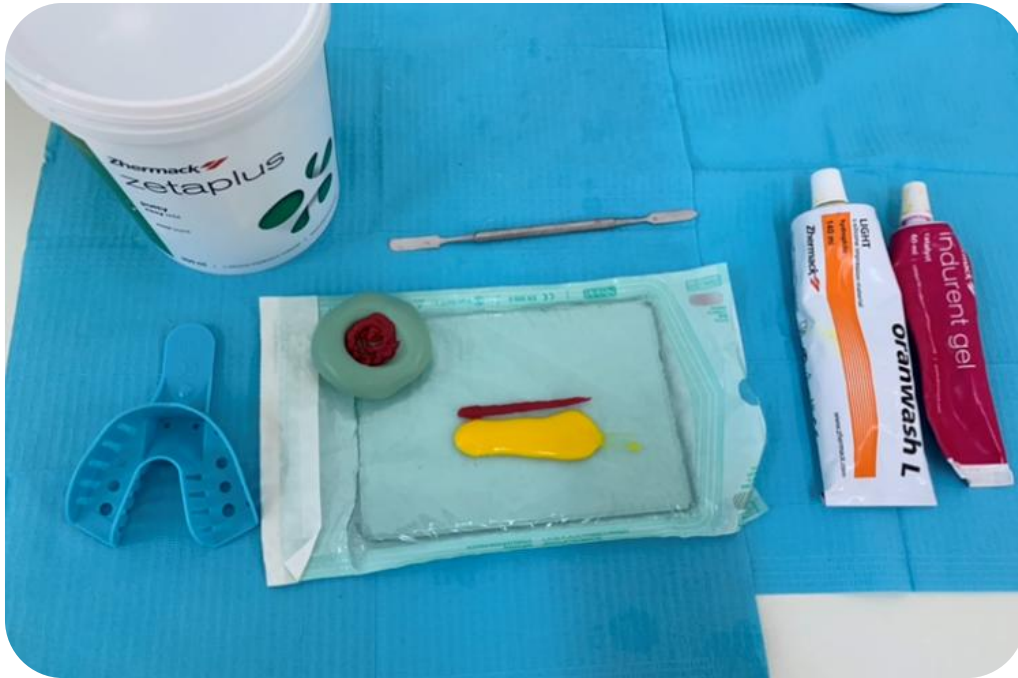Teeth preparation for UR6 and LR6



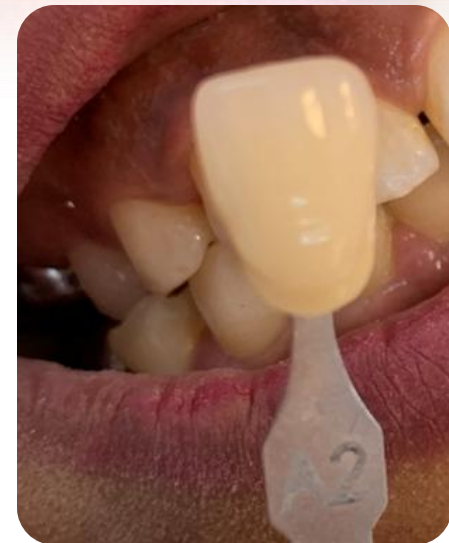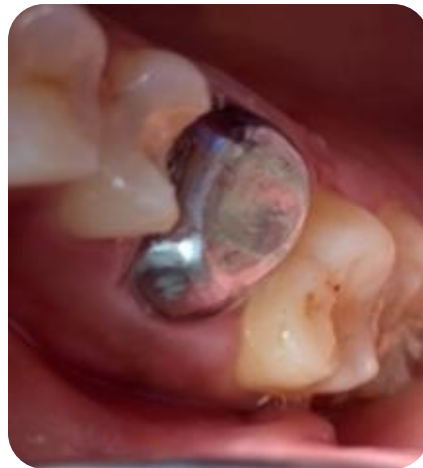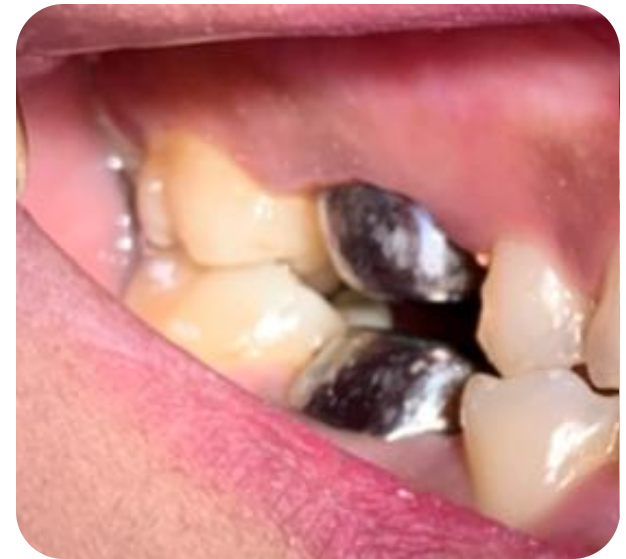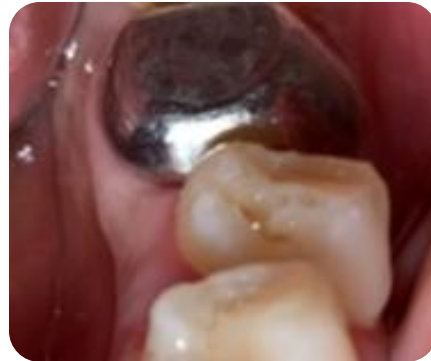
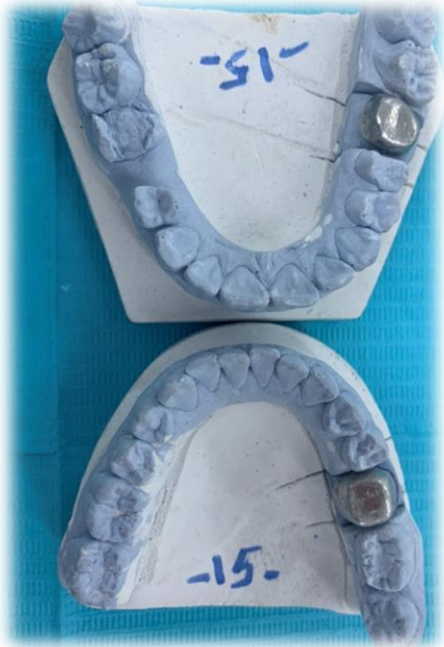Temporary crowns

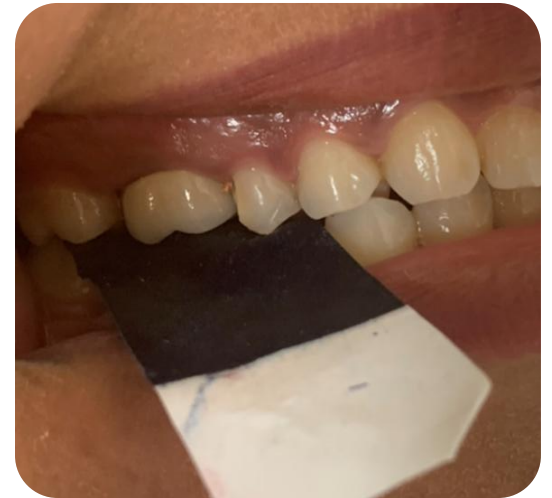
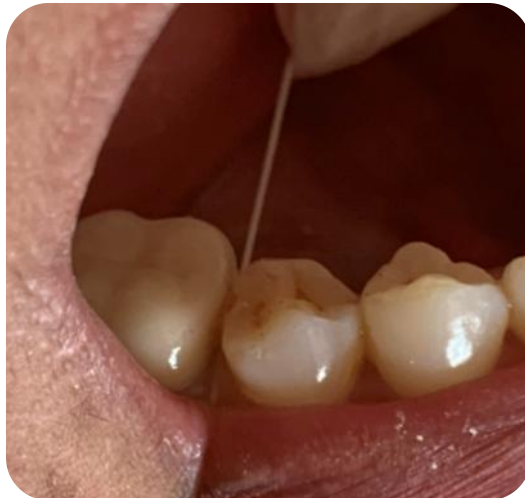
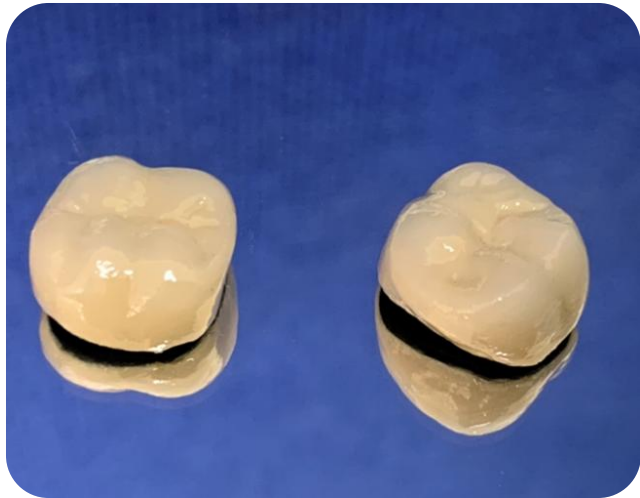Final impressions

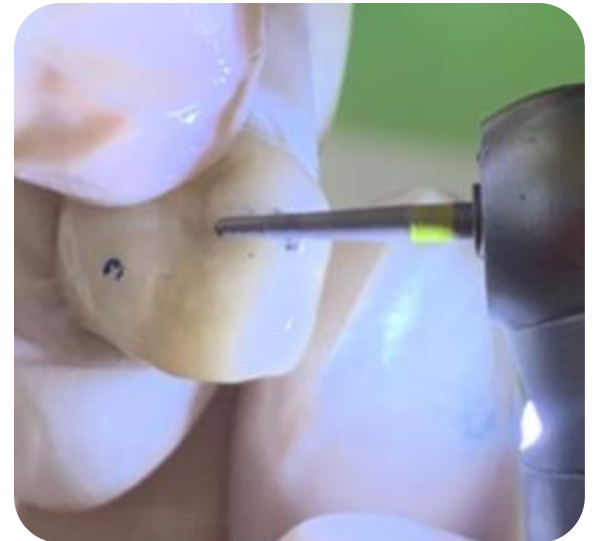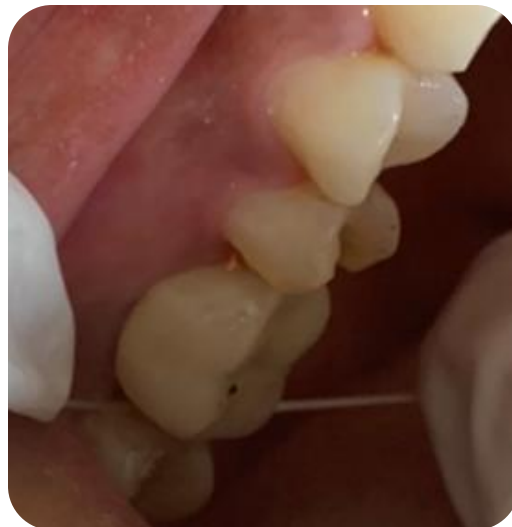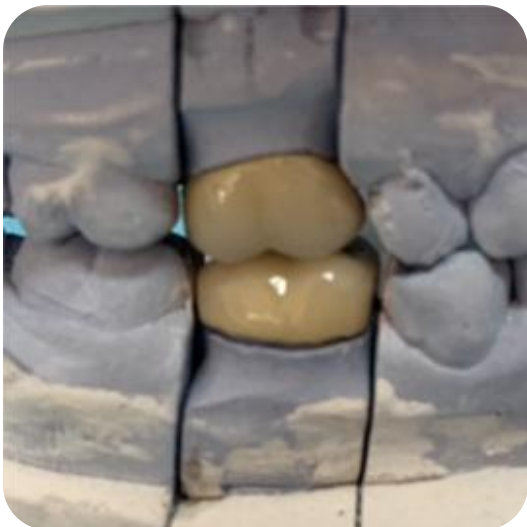


Metal Try-In

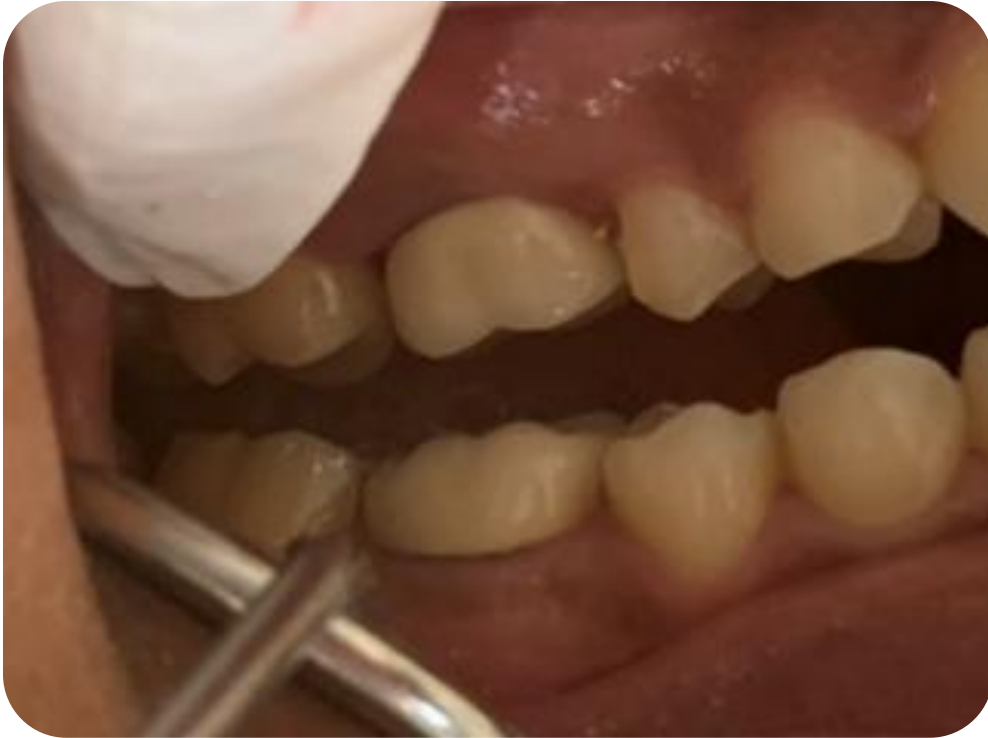



Insertion



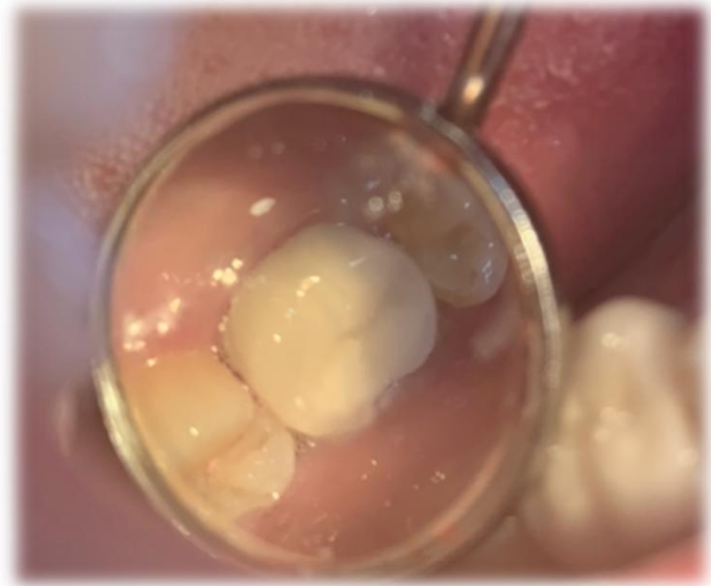
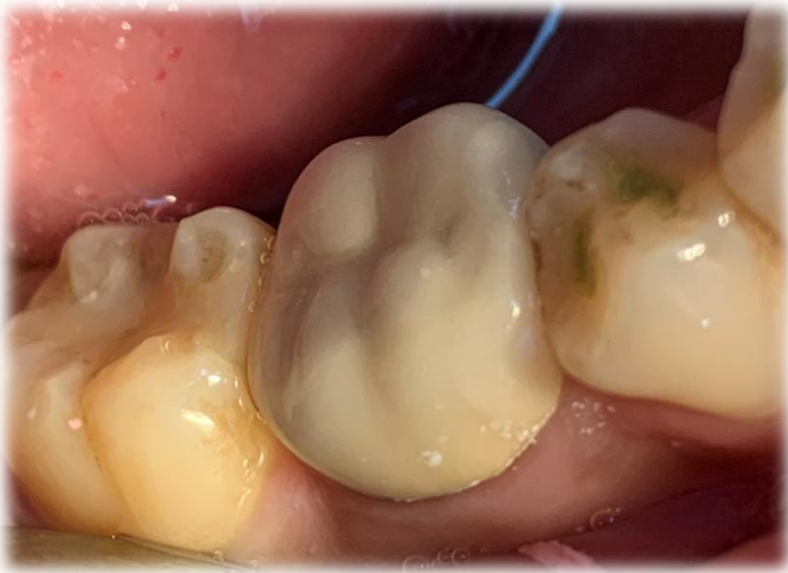Temporary cementation



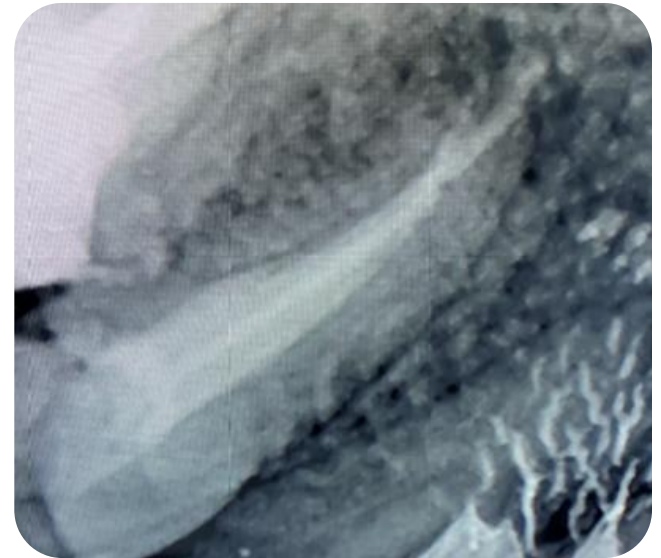
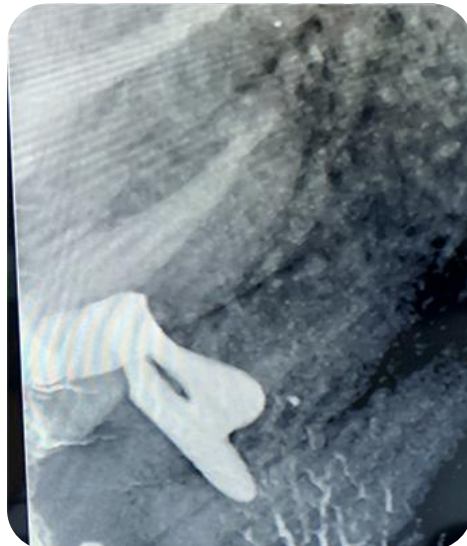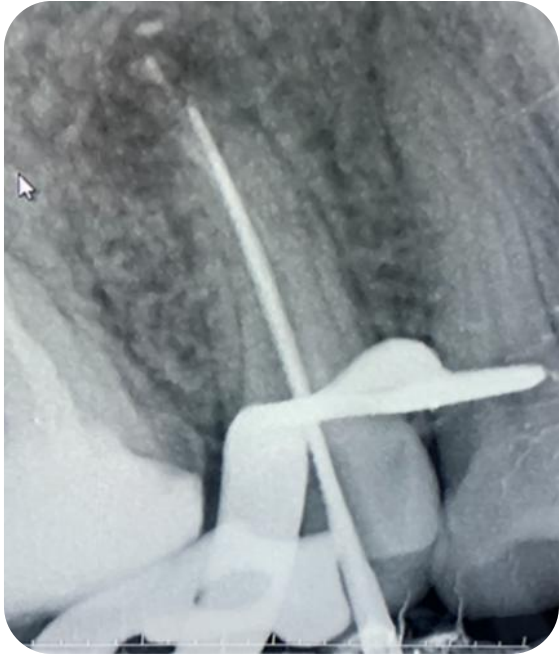After one week of trial cementation

- Pt complains from foot impaction in mesial side of UR6 And distal side of LR6.

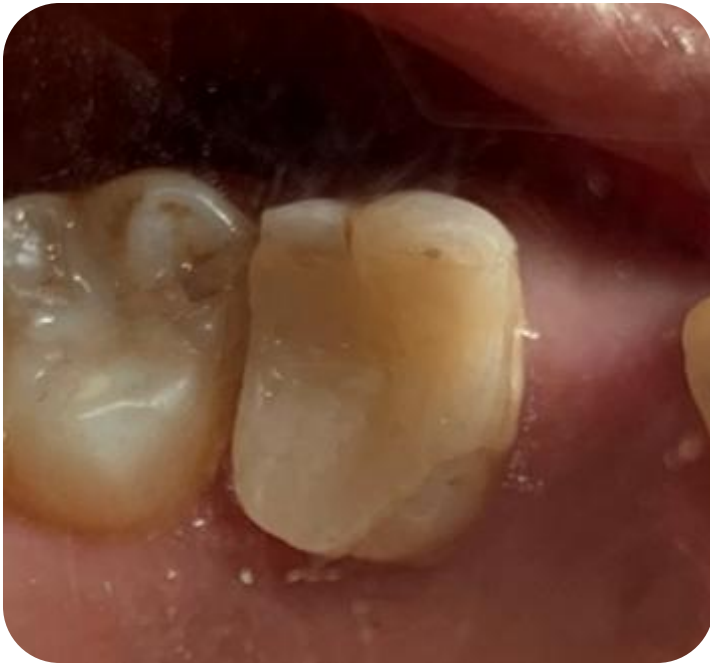Temporary cementation



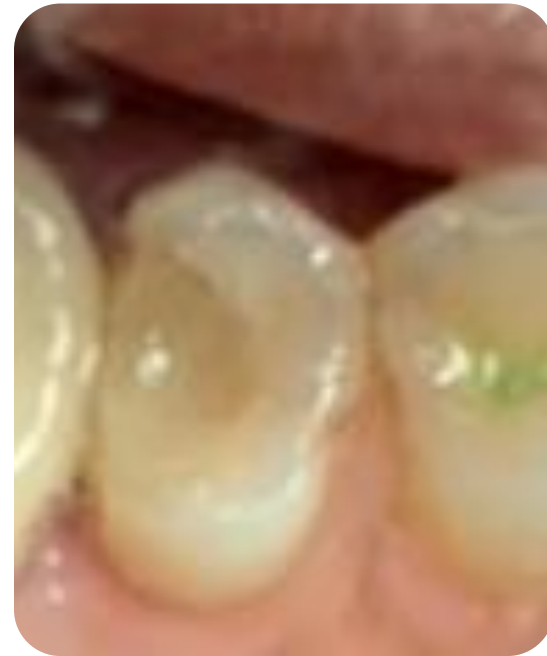Retreatment to UR5



Composite build up for and



UL6



UR5

Replacement for UR5

REFUSE

- Pt refused fixed bridge and removable appliance.
- She want make implant.

الجامعة الليبية الدولية للعلوم الطبية
كلية طب وجراحة الفم والأسنان
موافقة للأذن بالعلاج

أقر أنا / مريجة سجاد المبارك بطاقة شخصية رقم:

وأكمل أرادتي أنني أعطى موافقتي للفضية والكتابة للبدء والاستمرار في العلاج بعيادات كلية طب الأسنان بالجامعة الليبية الدولية للعلوم الطبية والذي يتضمن

عدم موافقة المريض على جسر

تسكينه مؤقتة للمسنن 15

وقد تم شرح التشخيص المرضي لحالتي والخيارات المختلفة المتوفرة لمعالجتها والأعراض الجانبية والمخاطر التي قد تصاحب العلاج والمشاكل التي قد تنتج عن عدم العلاج والمدة التقريبية اللازمة لانتهاء منه والتكلفة الاجمالية للعلاج وفقا للرسوم الرمزية المقررة كما اتفهم ان هذا العلاج قد تم تنفيذه من قبل طالب أو طبيب امتياز تحت الاشراف المباشر لأعضاء هيئة التدريس بالكلية.

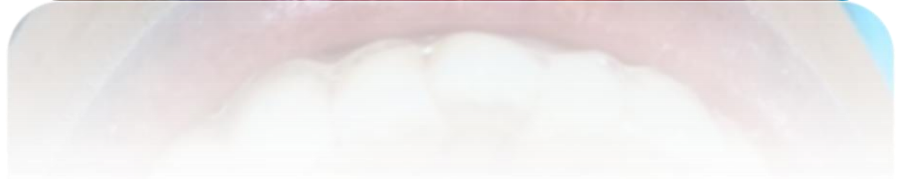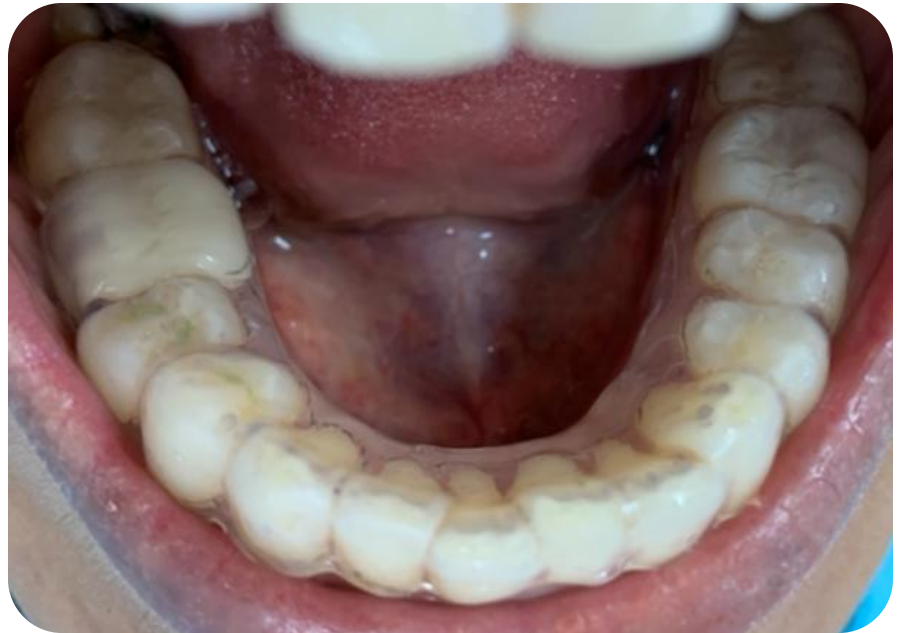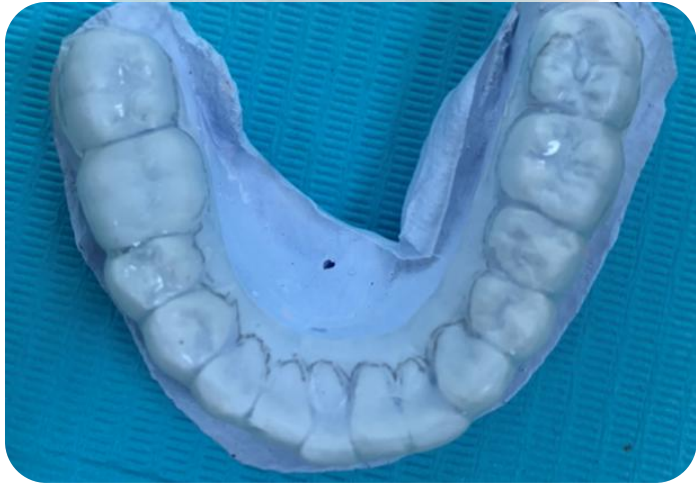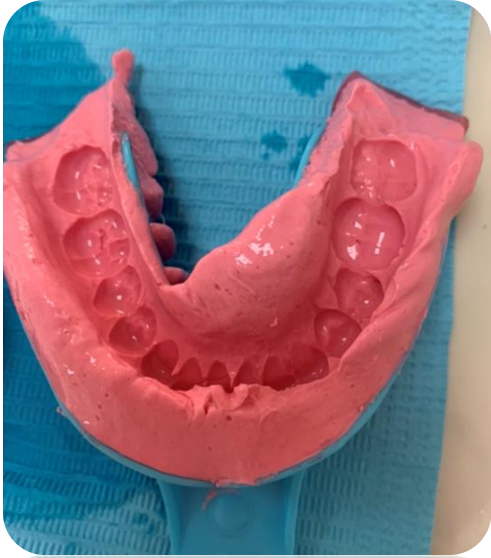اسم المريض: مريجة سجاد المبارك

توقيع المريض: مريجة

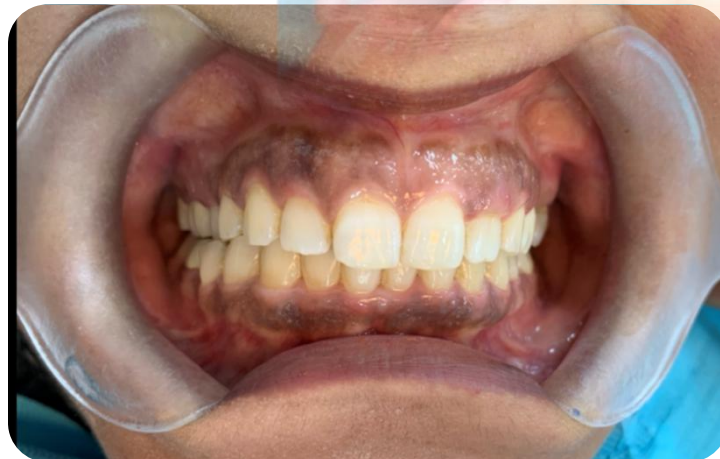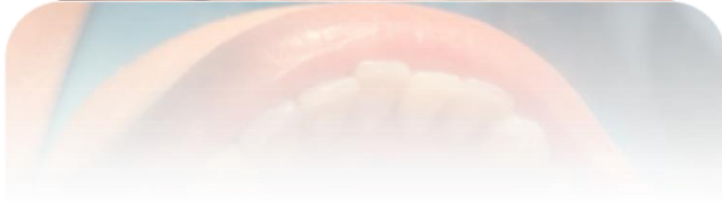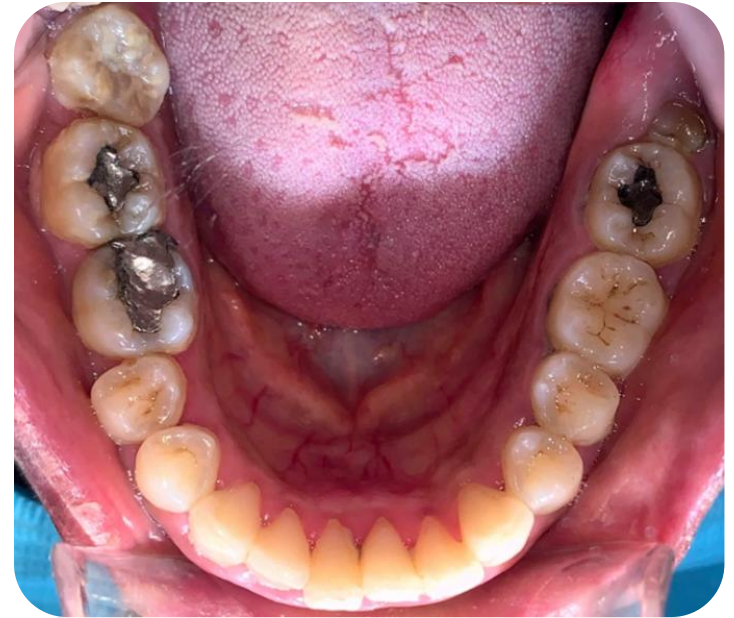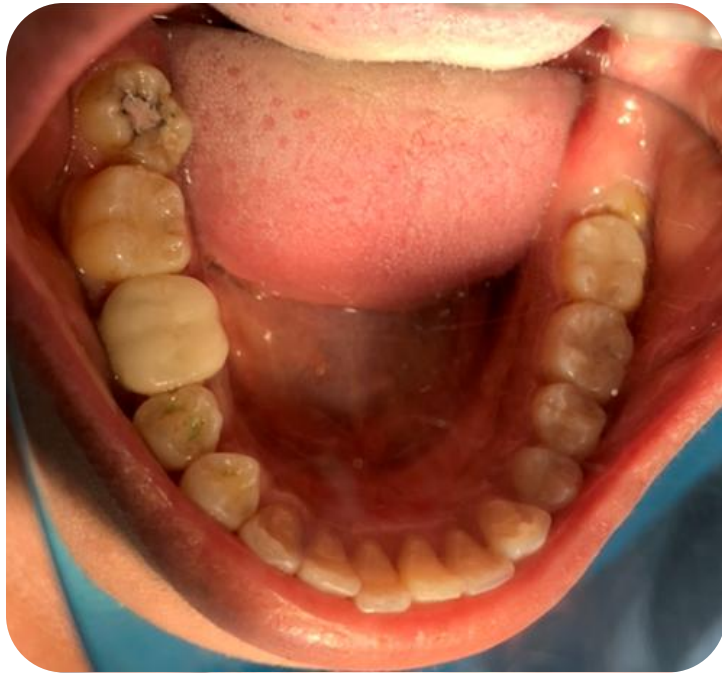اسم الطالب أو طبيب الامتياز: 1954

الاستاذ المشرف: 1954

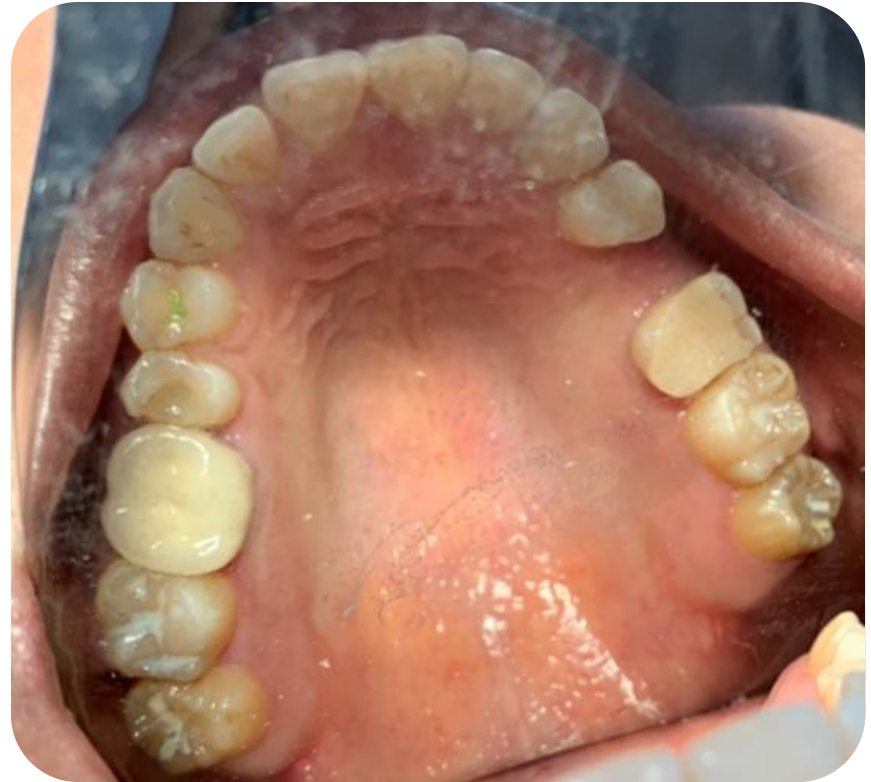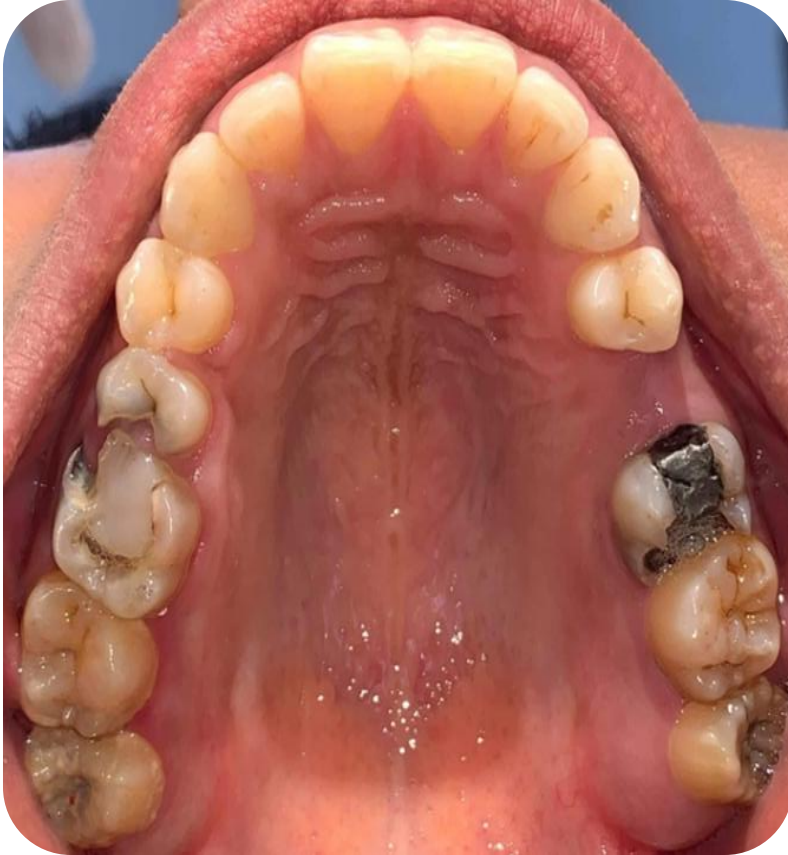Night guard



Before and after



Before and after



Thank you
for
listening!

