



Comprehensive treatment - Full Mouth Rehabilitation case

Presented by :


Safenaz M. Ibrahim Gehani

Role number : 723



This work was achieved by the student: Safinaz M. Ibrahim under the supervision of dental teaching staff at Libyan International Medical University:

- ❖ Rafeeq M. Al Kuafi
- ❖ Abdelmonem A. Abdelnabi
- ❖ Ranya F. Elemam
- ❖ Ali Busnaina
- ❖ Omar A. Huni
- ❖ Naima Beltamer
- ❖ Nada Kashbor
- ❖ Omer Zyou



+ Personal Data



Name : Z.K.E

Age : 19 years (30/03/1998)

Gender: Female

Nationally : Libyan

Occupation : Student

Material & Society : Single





Chief complaint & History of Chief complaint (1)



■ C.C :

Pain related to lower left back teeth ,since one week .

■ H.C :

Acute throbbing intermittent localized pain started one week ago , triggered by biting on hard objects. Once the pain starts it takes minutes to stop by its own. It doesn't interfere with sleeping. Also the patient doesn't notice any referred or radiating pain. No medication was taken by the patient .

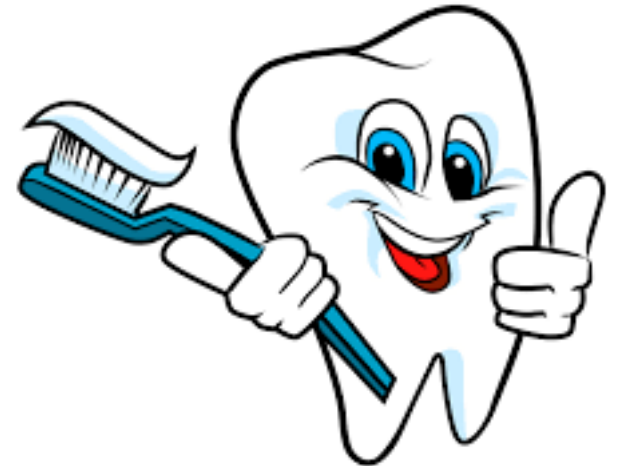The tooth was diagnosed one year ago as irreversible pulpitis by another dentist. And the patient attended just one visit and doesn't complete the treatment .



- **Medical history** : N.O.S
- **Drug history** : N.O.S
- **Allergic history** : N.O.S
- **Family history** : N.O.S
- **Social history** : single . Not smoker neither alcohol drinker or drug abuser.
- P.t is on balanced diet and drinking about 8 cups of water daily, brushing teeth twice a day with vertical and horizontal techniques .sometime she is using mouthwash also.

+ Dental history

- Not completed **RCT** for the lower first molars , hence patient attended just one visit .
- **Oral hygiene practice :**
 - **Brushing :** twice a day regularly
 - **Brushing method :** horizontal and vertical
 - **Kind of Dentifrice used :** not specific
 - **Any other orophysiotherapeutic Aids :** sometimes using mouthwash




+ Extra-oral examinations

■ **TMJ status :**

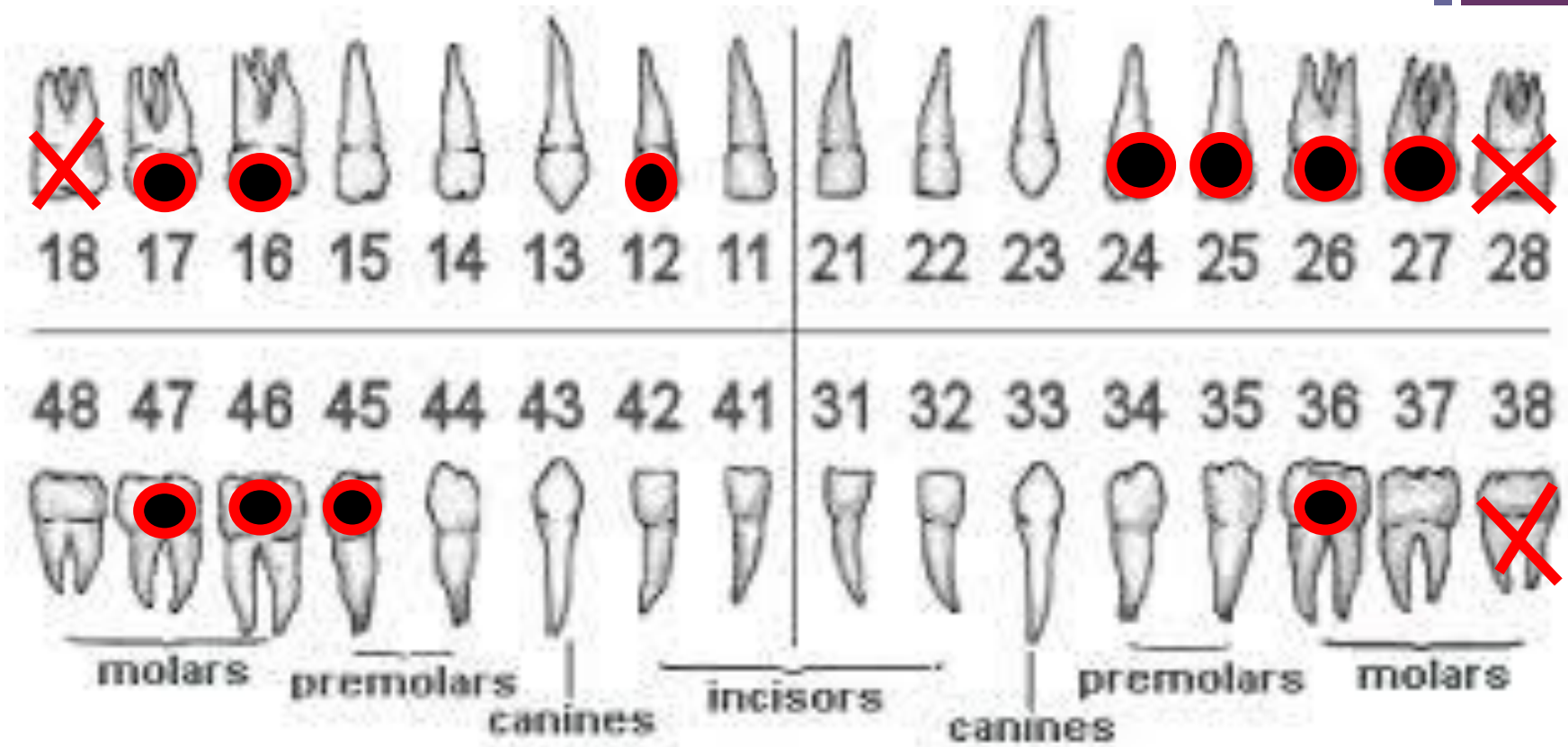
- examination reveals no clicking, crepitation, limitation or deviation of mouth opening, with no masticatory muscles tenderness.

■ **Lymph nodes :**

- not palpable , neither tender .



+ Dental Chart



DMFT : 11



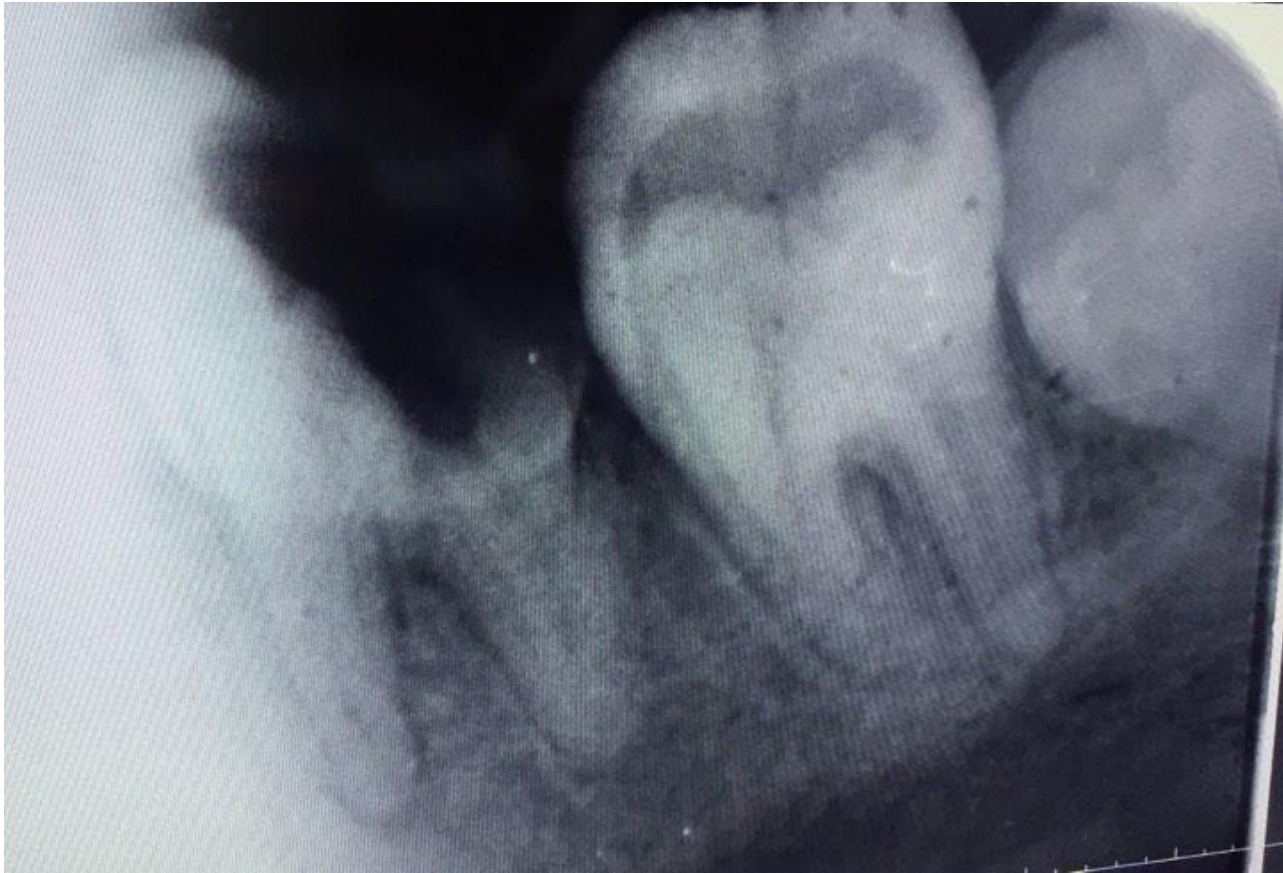- Clinical examination for the offending tooth revealed badly broken down tooth . Which is tender to **vertical** percussion , but it's not tender to palpation .

- **Differential diagnosis :**

- 1) acute periapical periodontitis
- 2) acute periapical abscess
- 3) Periapical granuloma



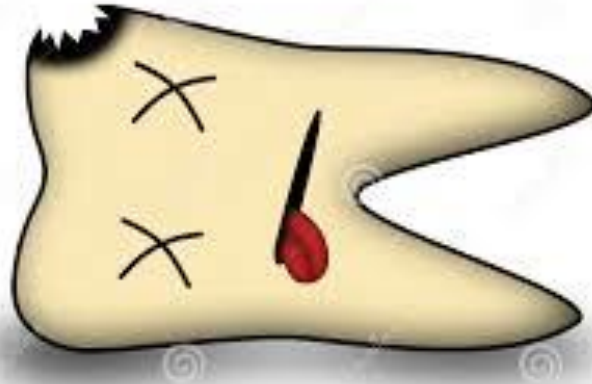
+ Intraoral Periapical radiograph





■ **Final diagnosis :**

Acute periapical periodontitis



+ Treatment plan

- **Emergency phase** : extraction



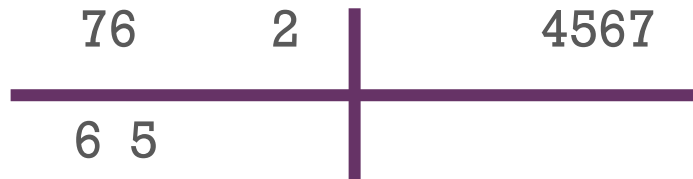
- **Phase I** : O.H instruction & scaling

- Reevaluation of phase I

- **Phase II** : extraction



- **Phase III** : restoration



Replacing of missing teeth

- **Phase IV** : reevaluation

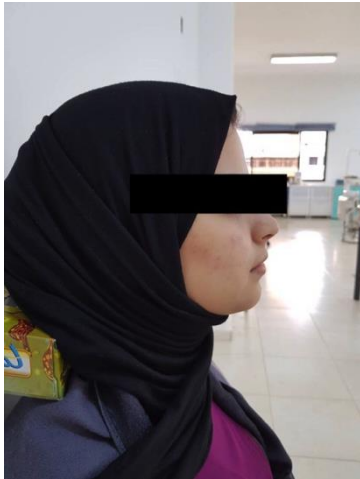
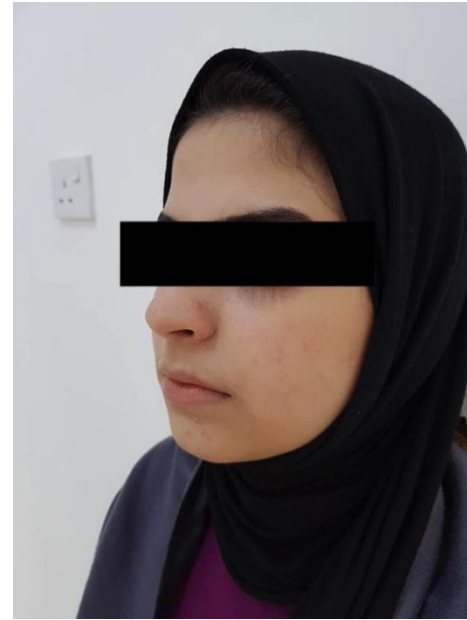
+ Five months later :

- the patient came to the clinic with two chief complaints .
- **The 1st** : in patient words 'I need to replace the missing tooth'
- **H.C** : the tooth was extracted 5 month ago , due to caries as it was diagnosed as hopeless tooth. (no complications)

-
- **The 2nd** : bleeding on brushing since one week.
 - **H.O**: bleeding on brushing related to upper right anterior teeth , started with brushing and stops after 1 minute by its own. Accomplished by mild annoying dull pain .p.t tried to use salty water rinse but with no to little improvement.

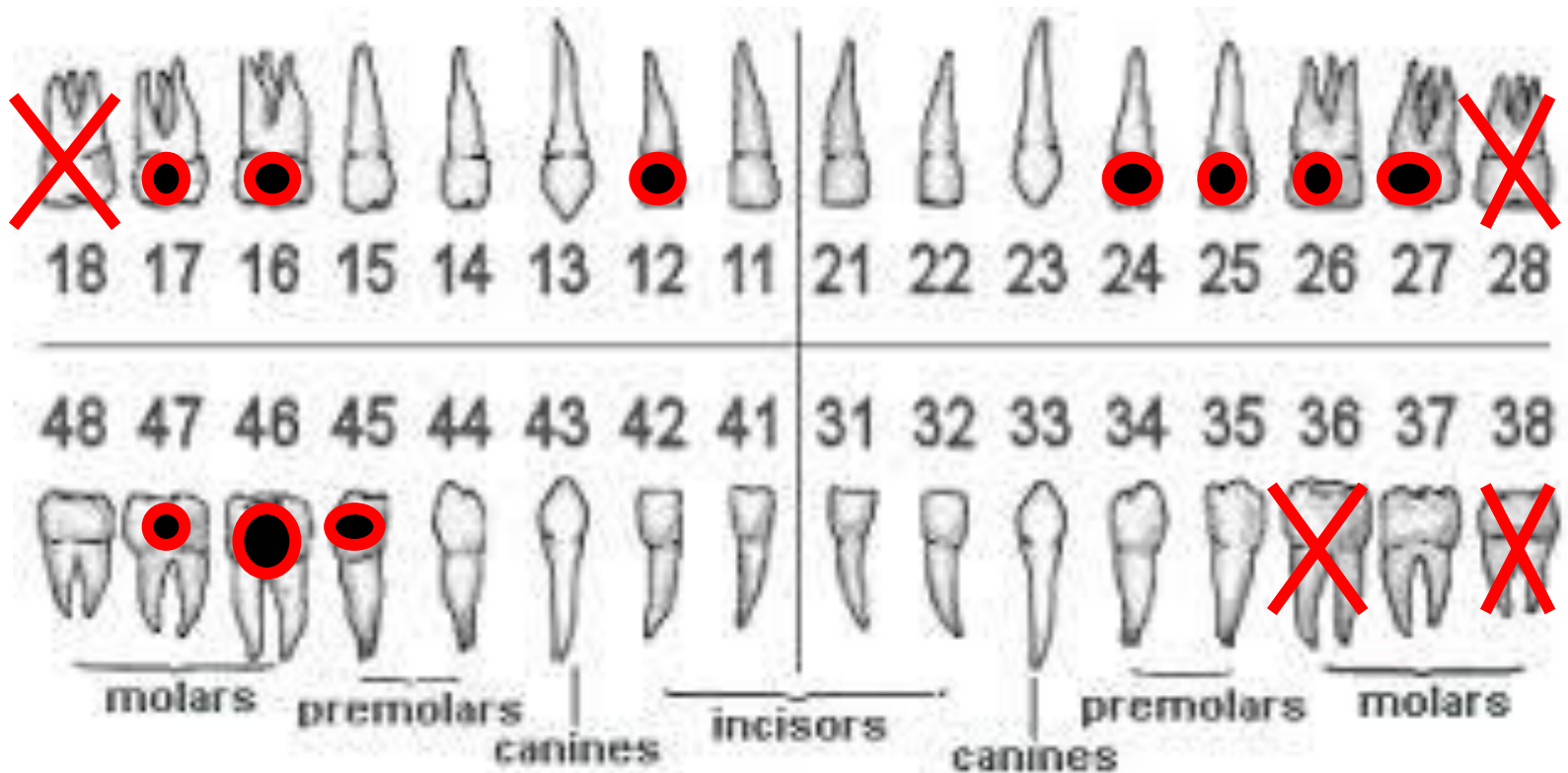
+Extra-oral photographs



strait profile



+ Dental chart



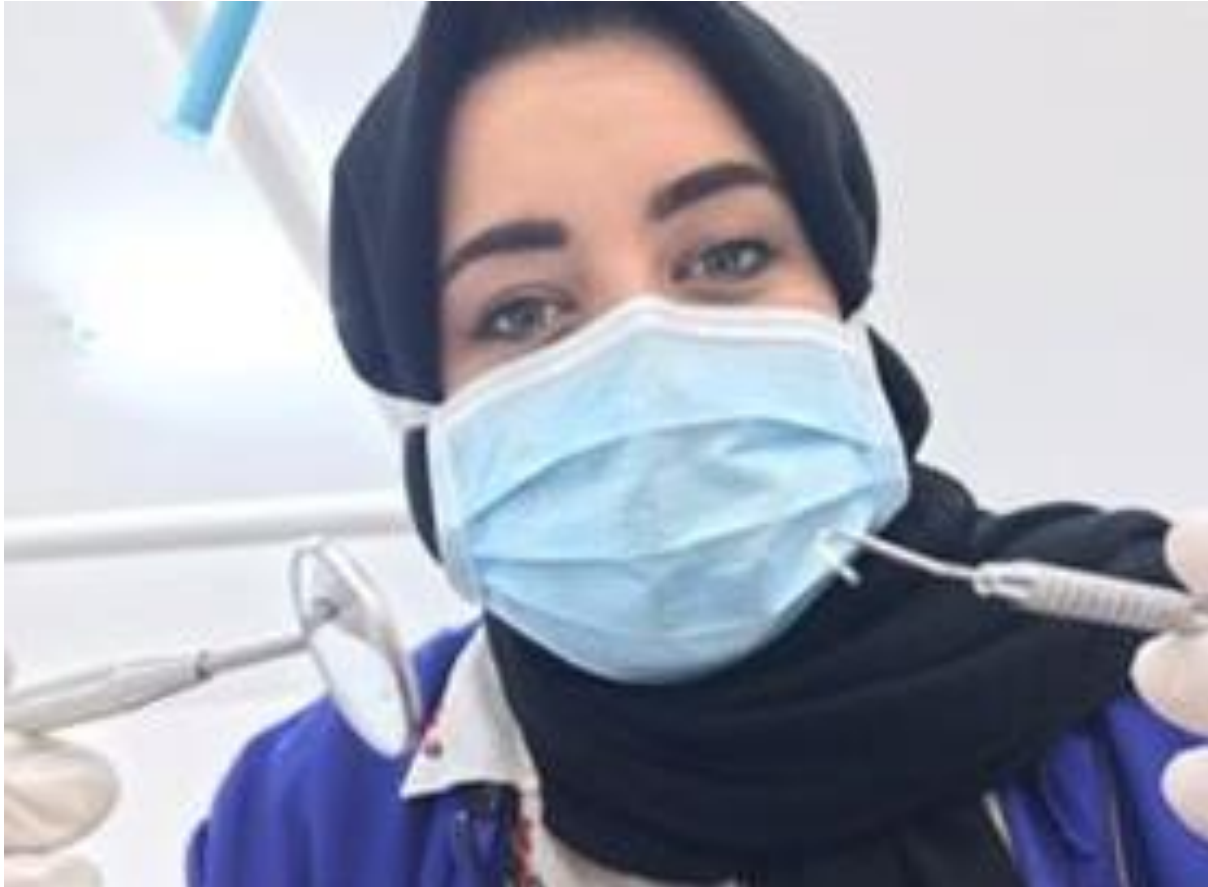DMFT :11

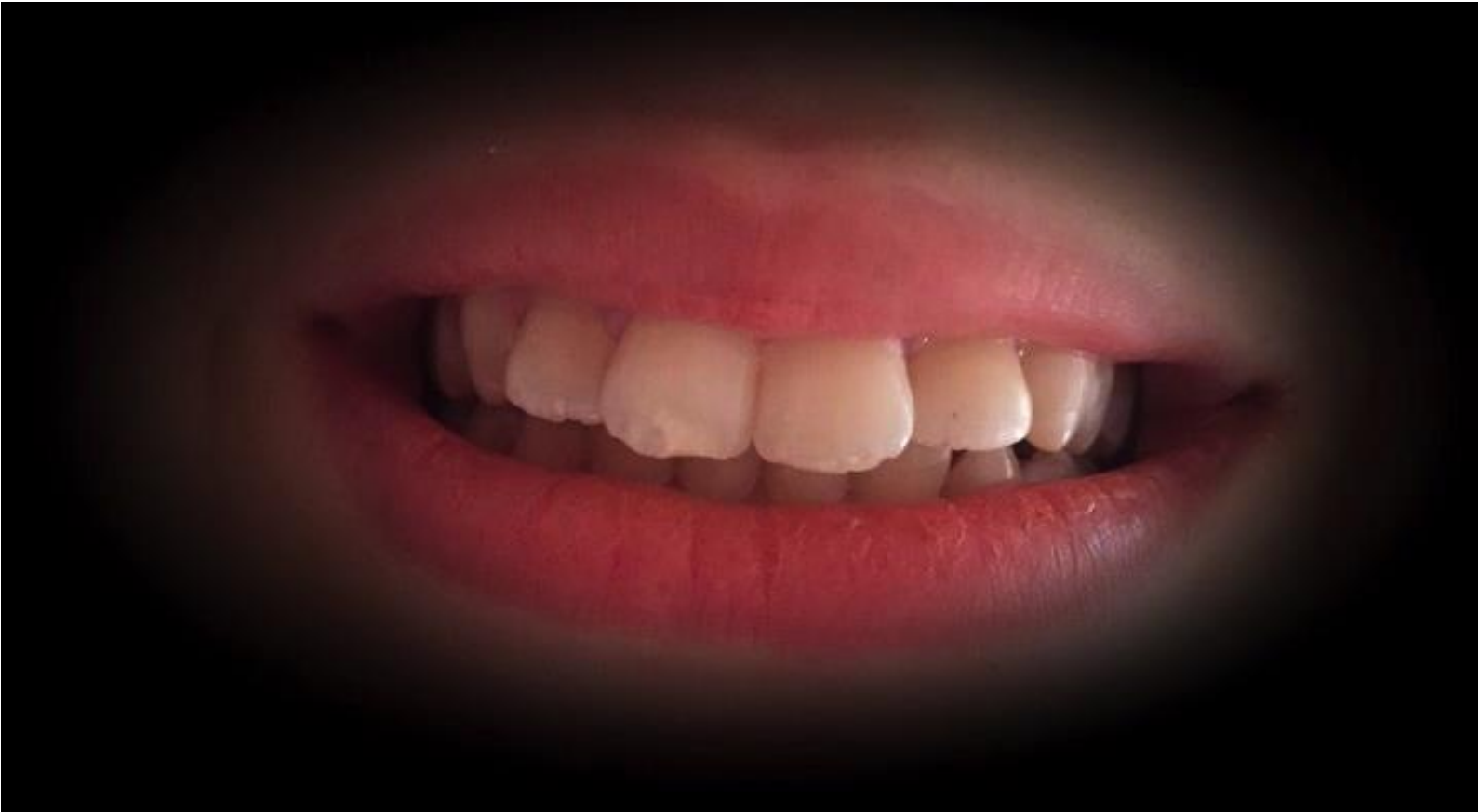oral hygiene index simplified : 0.3 good

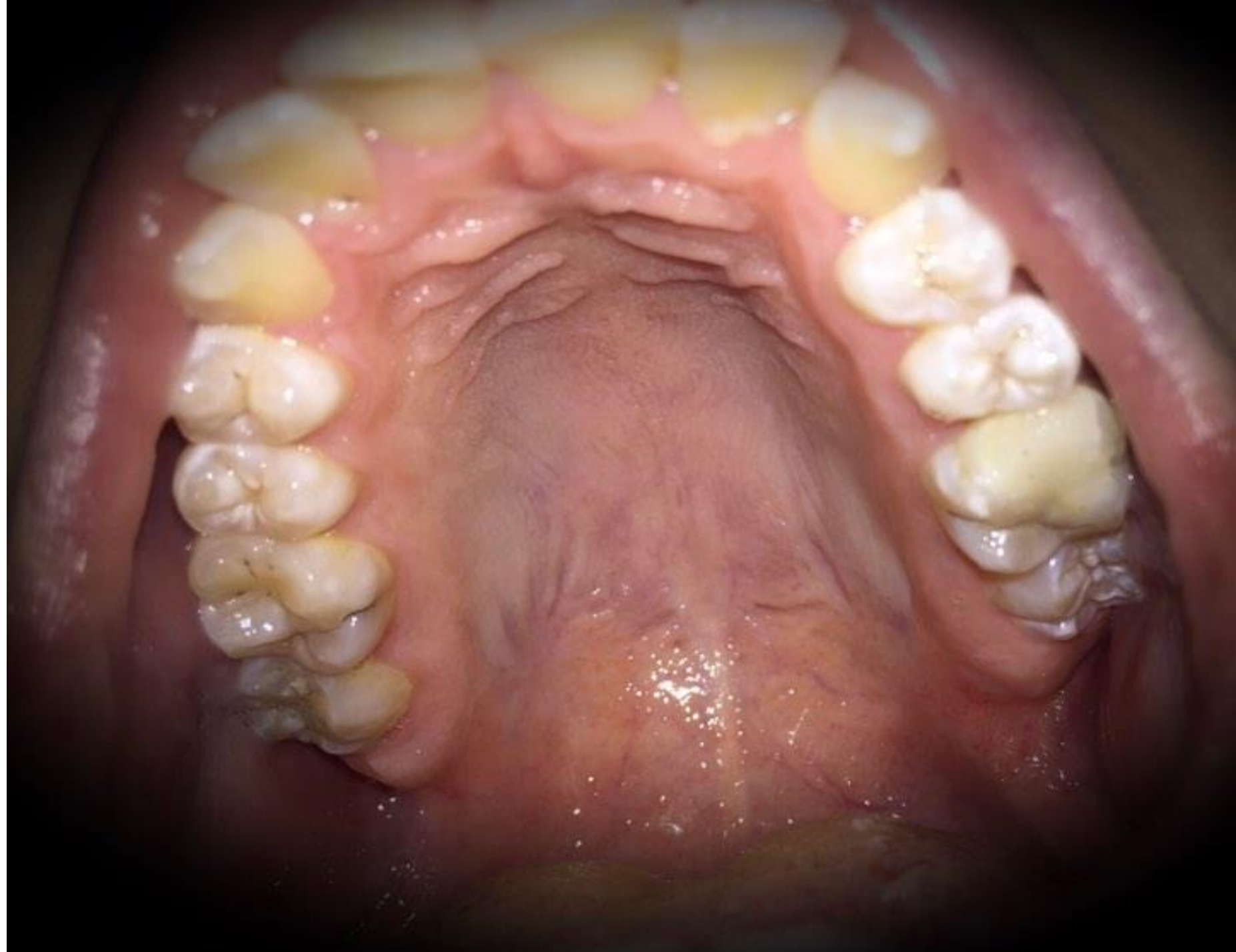+ Periodontal health

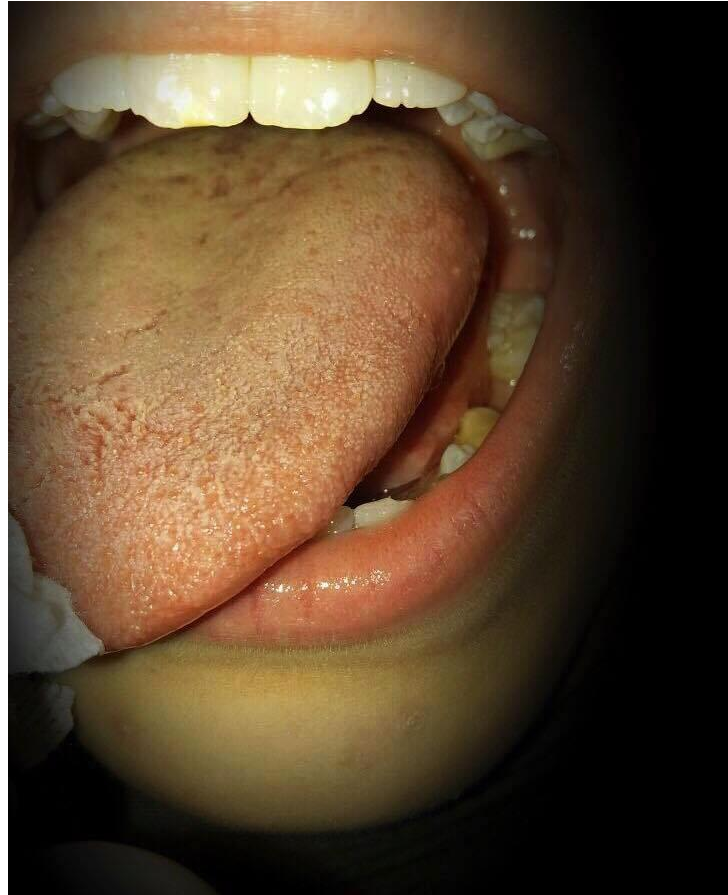
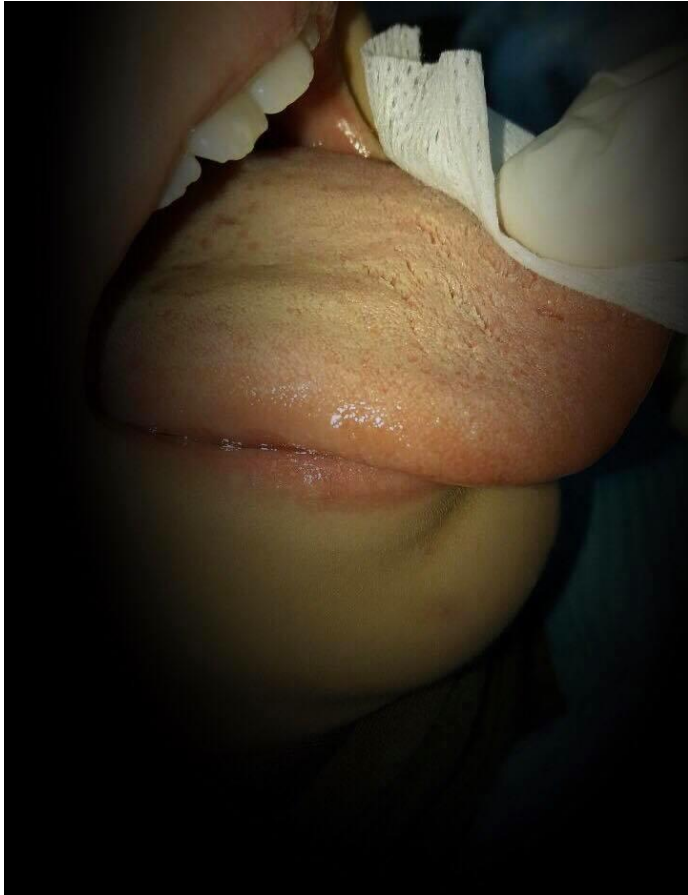

- Normal gingival collar pink color , with normal scalloped margin, and knife edge IDP . Except the area related to chief complaint exhibit some gingival oedema with blunt IDP.
- There is normal stippled gingivae .
- Pocket depth within **normal** range for all aspects .
- There is bleeding on probing related to upper Right central incisor , upper right lateral incisor and upper right canine of score **1 SBI**.
- There is no mobility .
- There is no recession .


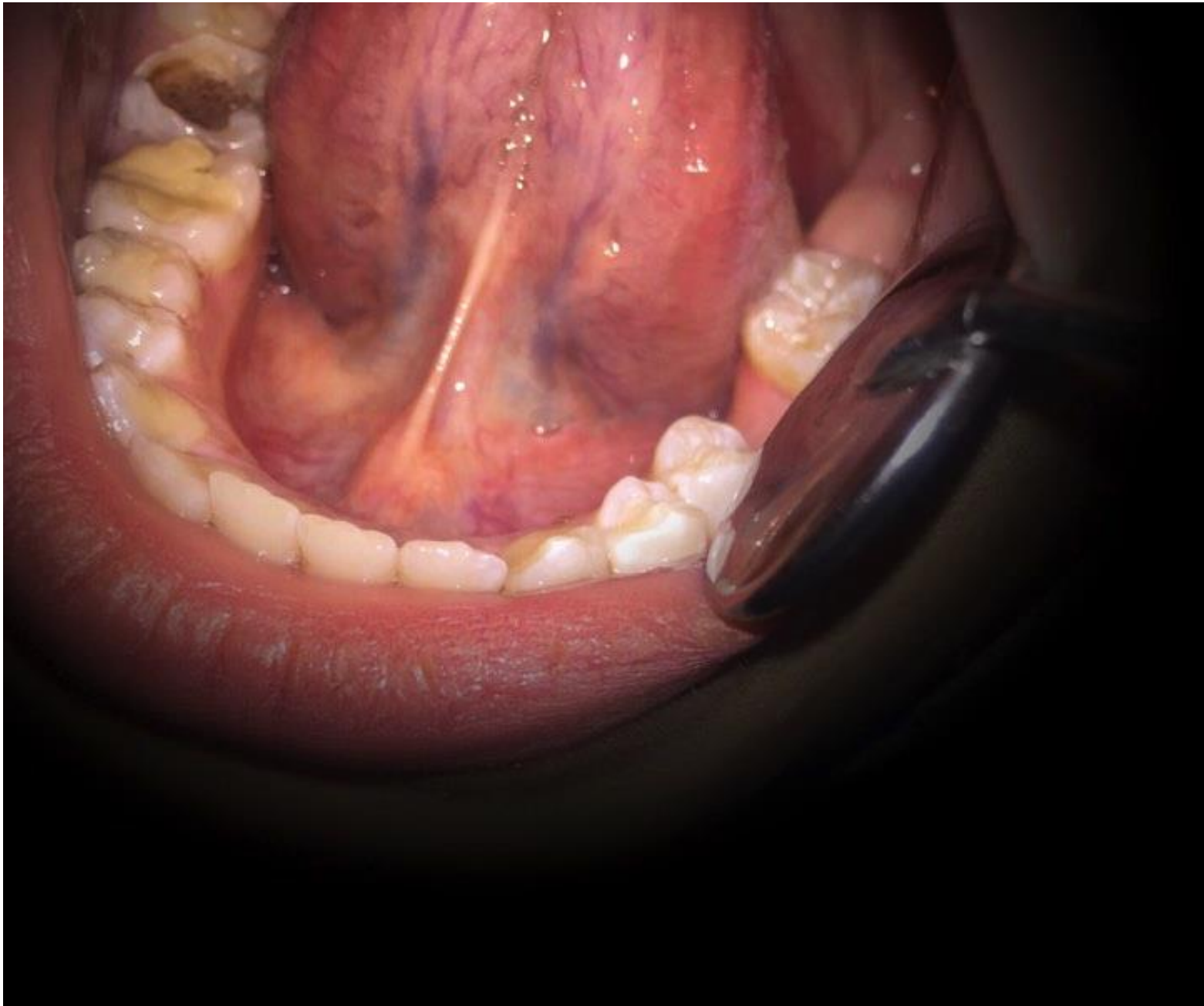
+ Intraoral photographs

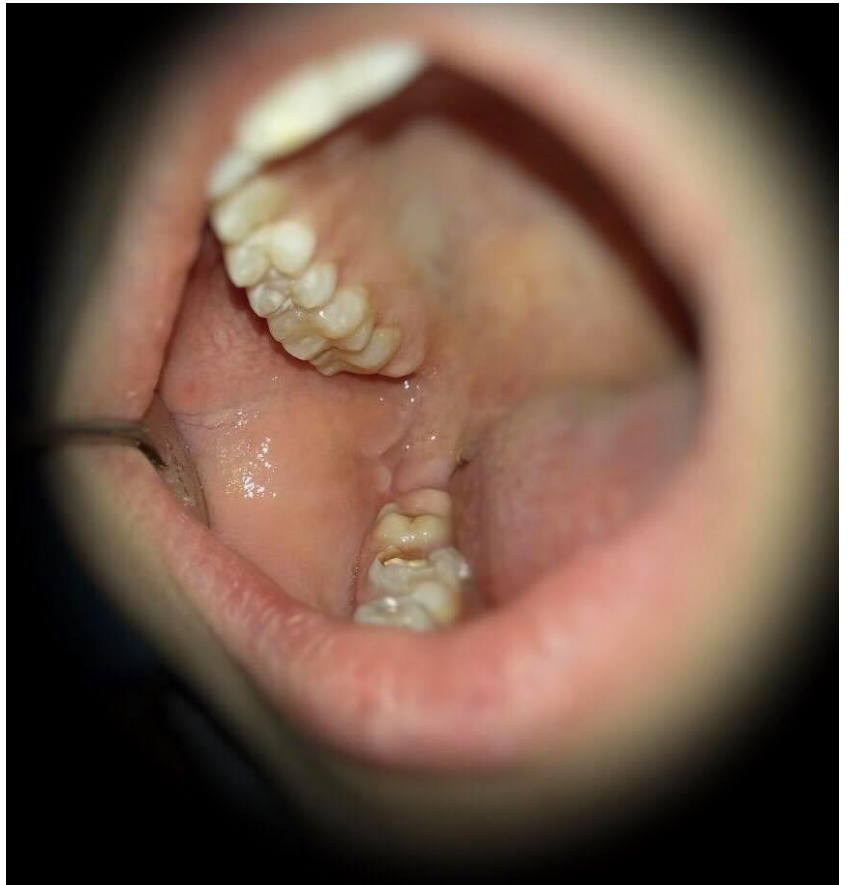
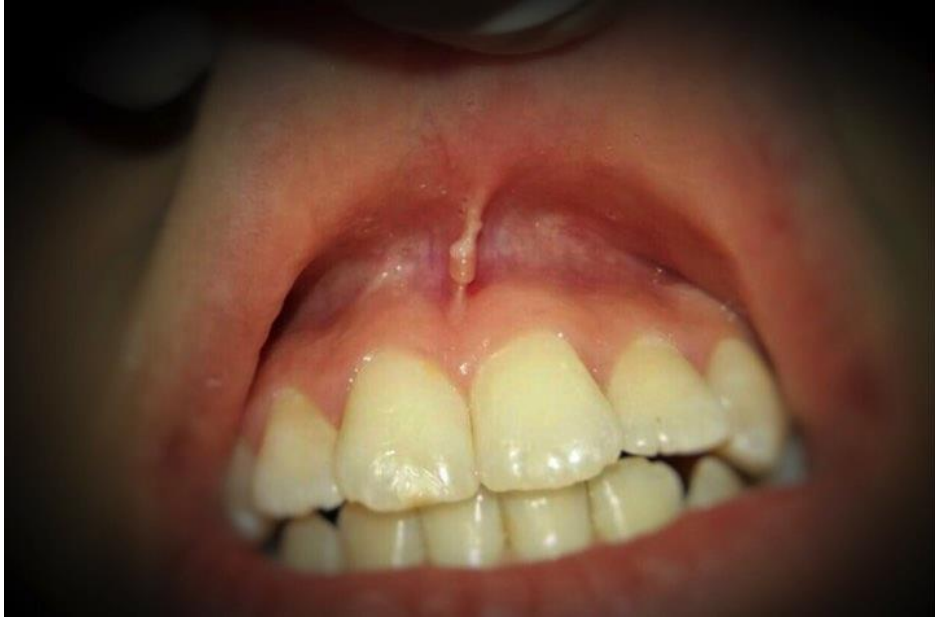


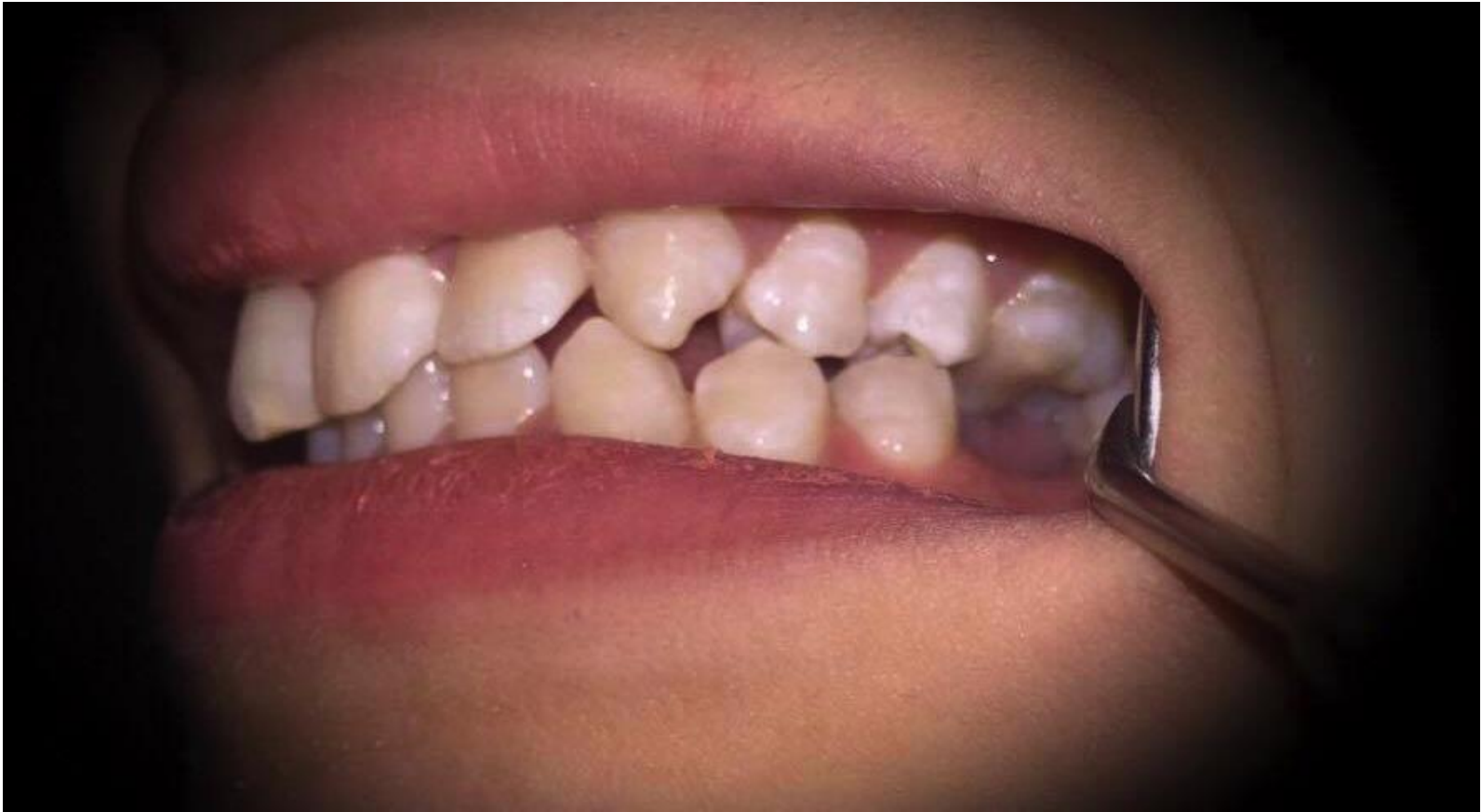


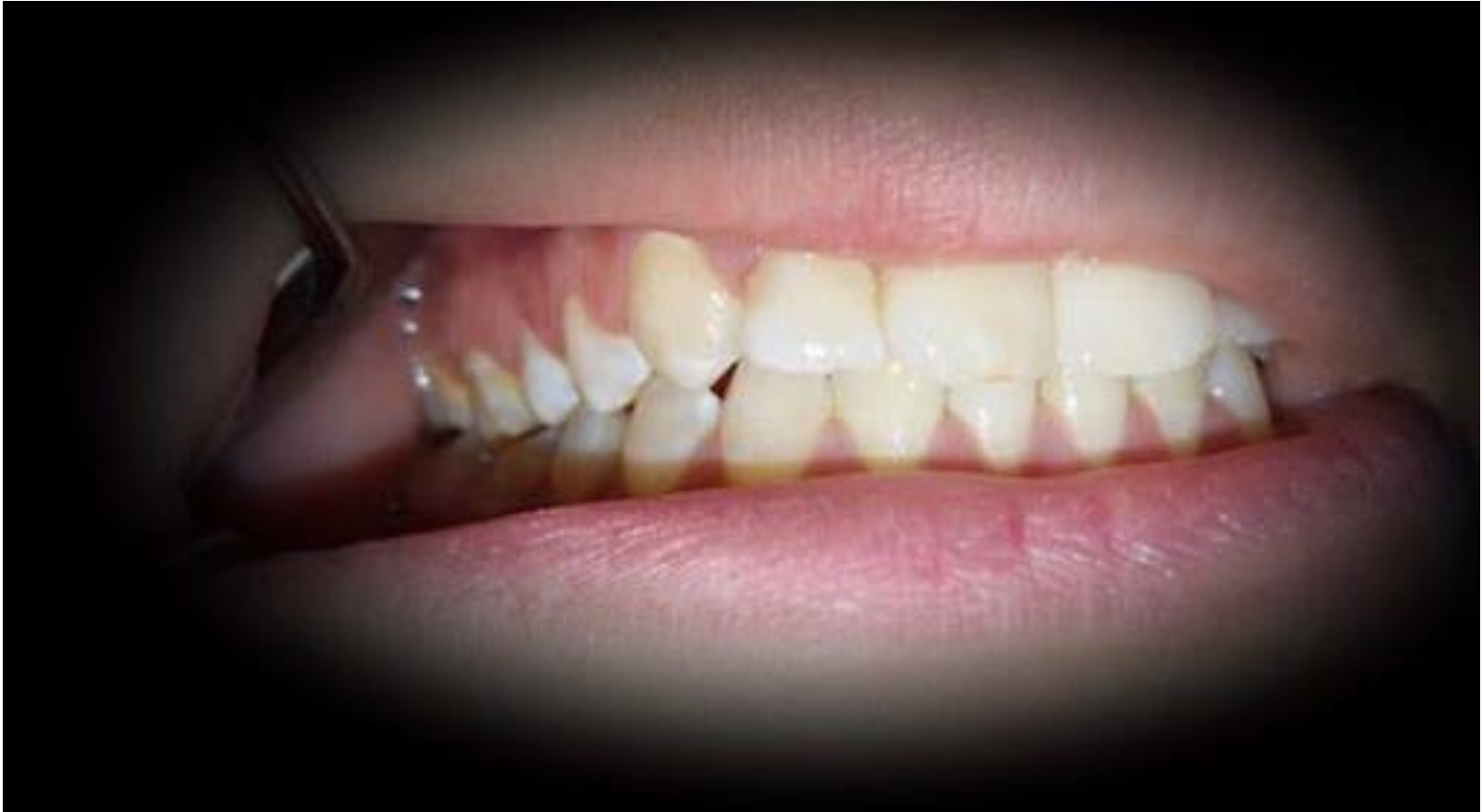


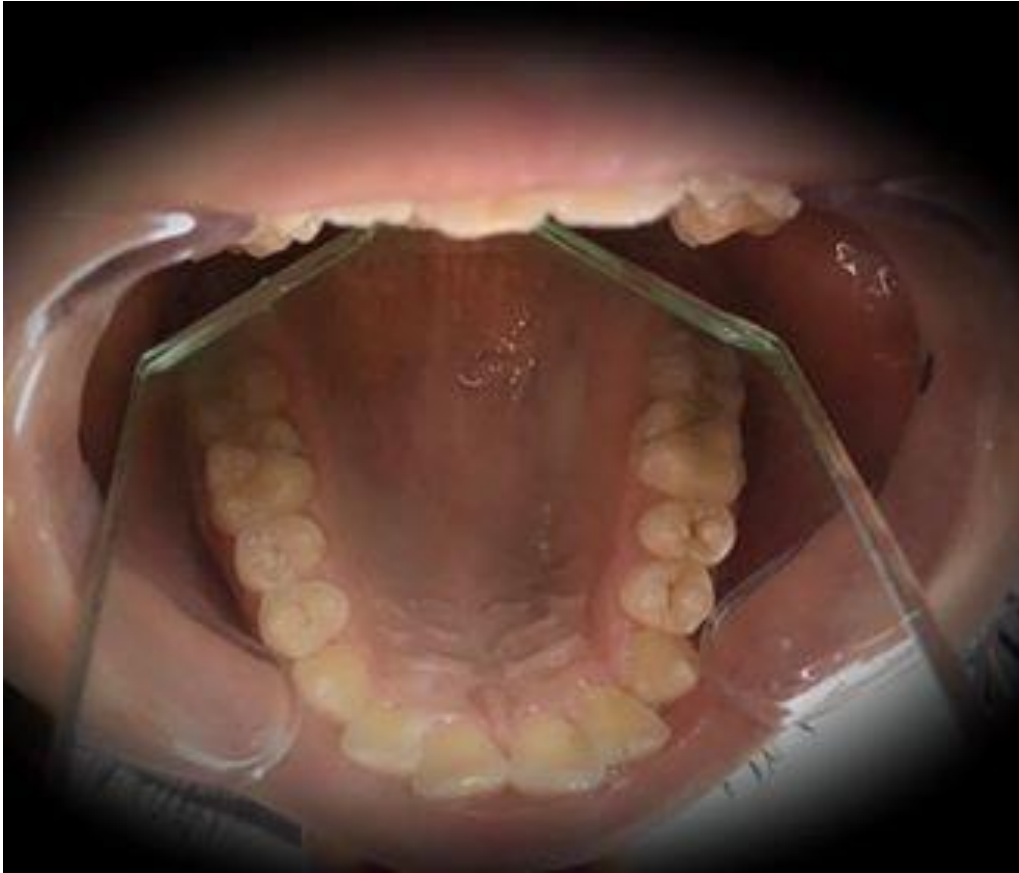


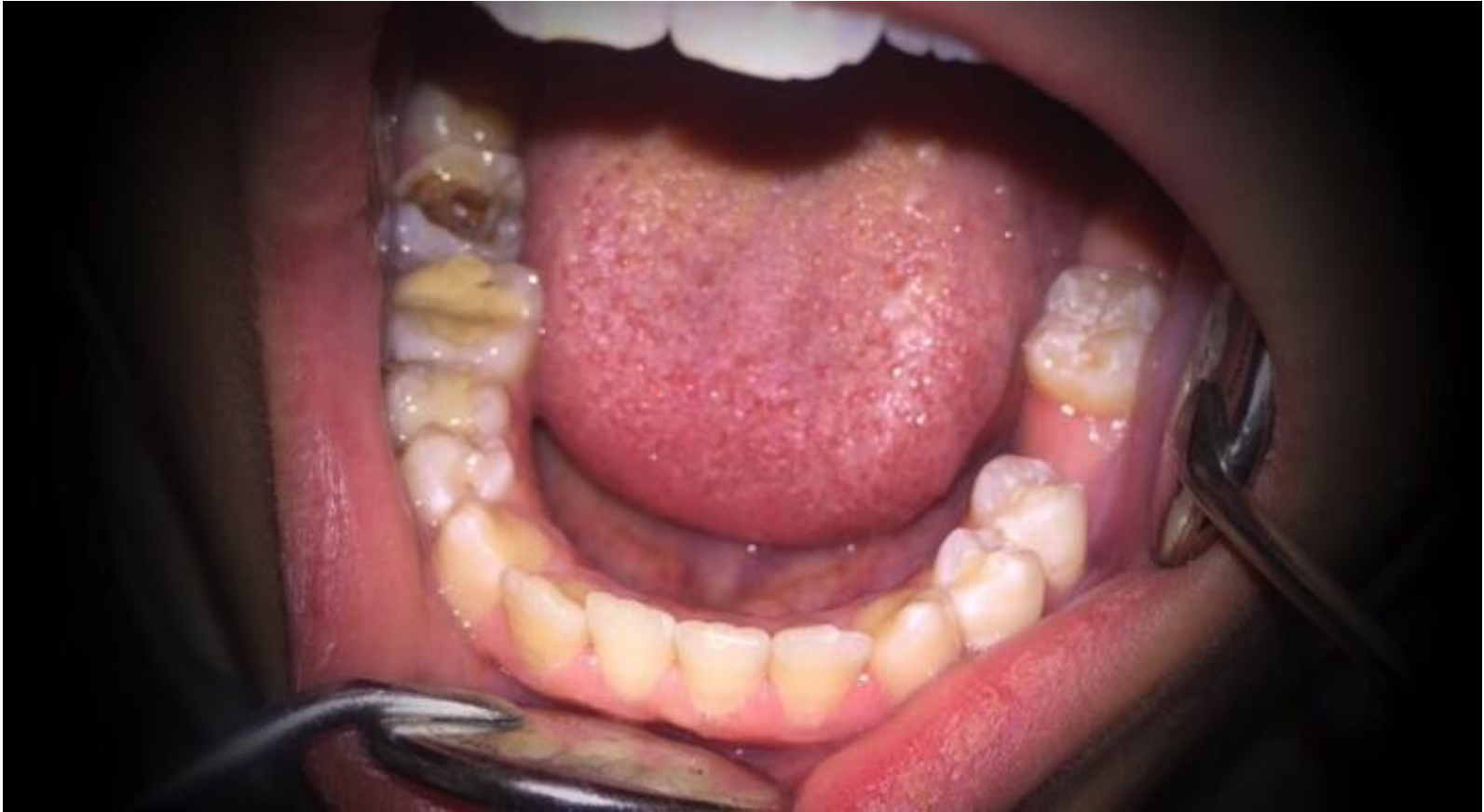




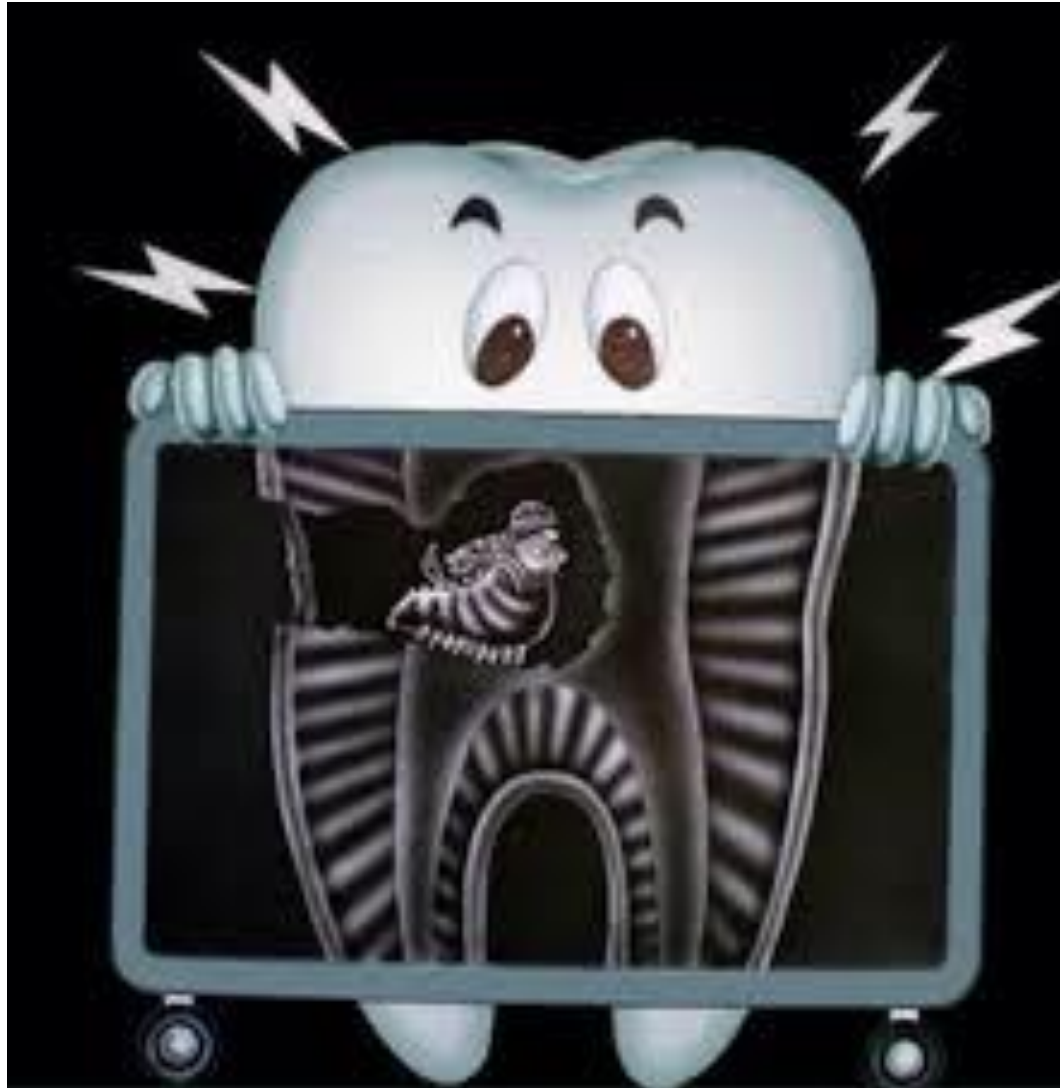




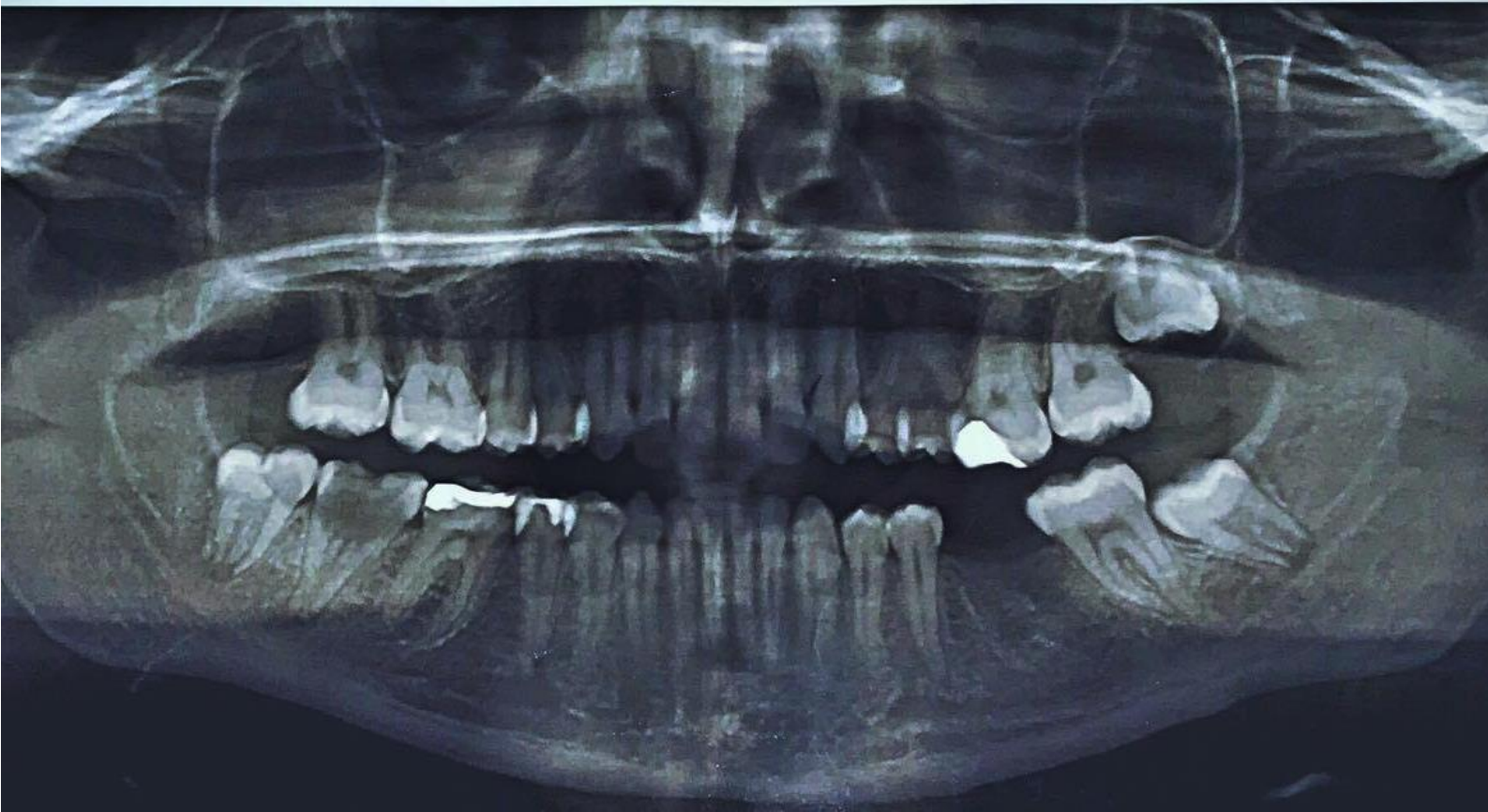
+ Extra oral radiograph

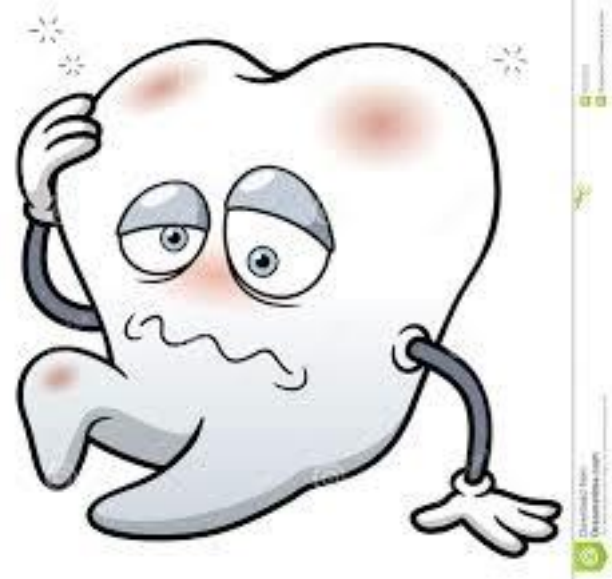


+ Extra Oral Orthopantomographic Radiograph





- The patient is **unidirectional** group function occlusion .
- **Class III** with no modification according to Kennedy classification .



+ Treatment plan



+ Treatment plan



Phase I therapy :

- ◆ Patient motivation.
- ◆ Oral hygiene instructions.
- ◆ Scaling.
- ◆ Fluoride application / Fluoride varnish *



Floss



Brush



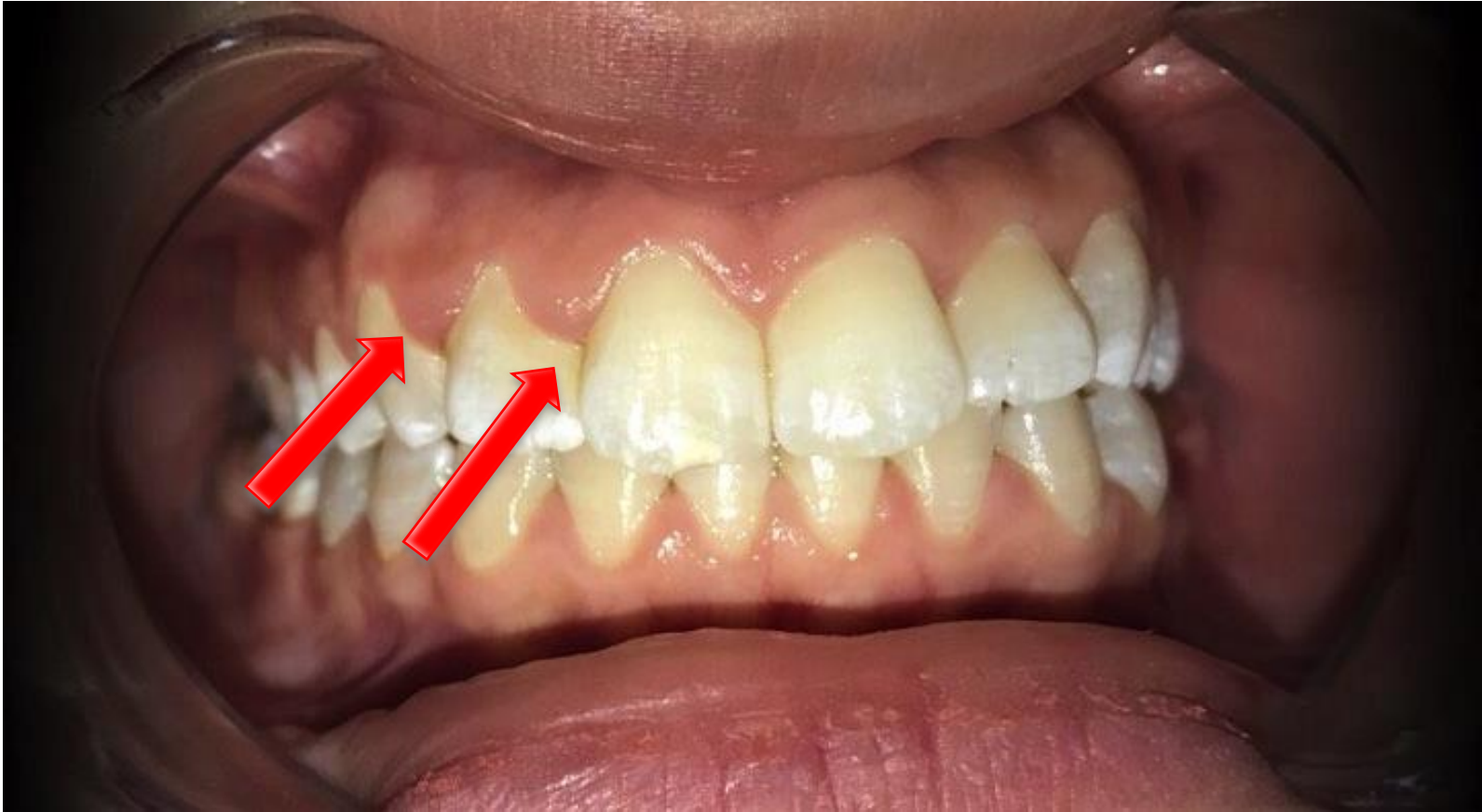Rinse

Reevaluation of phase I therapy .

+ Diet sheet

نوع الوجبة	الماكولات والمشروبات	الساعة	اليوم
نظور Snack غداء	فطوران قهوة مع كوب ماء نصف خبز بلالين والبيض مع كوب حليب وشاي مكرونة مع سلاطة + عسل + كوب ماء + شاي مع كوب حليب وكوب ماء	7:00 صباحاً 11:00 3:30 ظهراً	الاربعاء
Snack عشاء	كوب قهوة مع شربان بالسايف مع كوب ماء عشاء أرز + دجاج وطبخ وعسل مع كوب شاي	6:30 مساءً 8:30 ليلاً	
فطور snack غداء	فطوران قهوة مع كوب حليب نصف خبز بلالين والبيض مع كوب حليب وشاي أرز مع سلاطة + لحم + كوب شاي وعسل	7:00 صباحاً 10:00 3:00 ظهراً	الخميس
Snack عشاء	فطوران قهوة مع كابت وكوب ماء خبز حليب مع كوب شاي وكوب ماء	5:30 مساءً 11:30 ليلاً	
فطور غداء	نصف خبز مع كوب حليب وشاي مع فطوران قهوة كفتيس بالحم وسلاطة وبقلاصتين مع كوب عسوت حريشا وكوب شاي	9:00 صباحاً 2:00 ظهراً	الجمعة
snack عشاء	فطوران قهوة مع كوب ماء وكوب عصير تفاح خبز ودجاج وعسل	6:00 مساءً 11:00 ليلاً	

+ Phase I



+ Treatment plan



Phase II therapy :

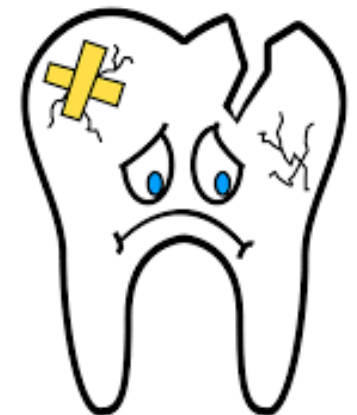- Extraction of



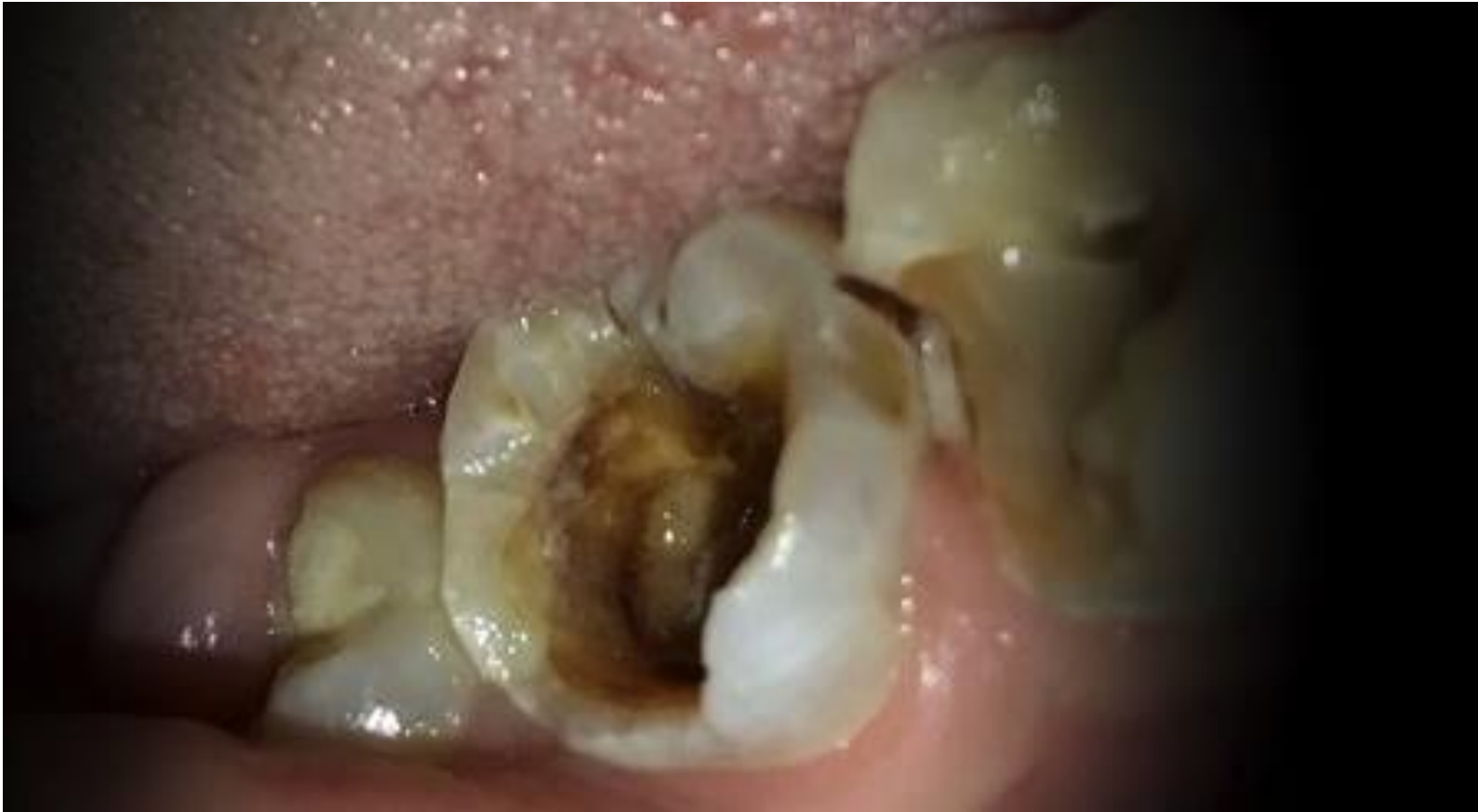Because the offending tooth is **non-restorable** badly broken down tooth , that is tender to vertical percussion .

Diagnosed as :

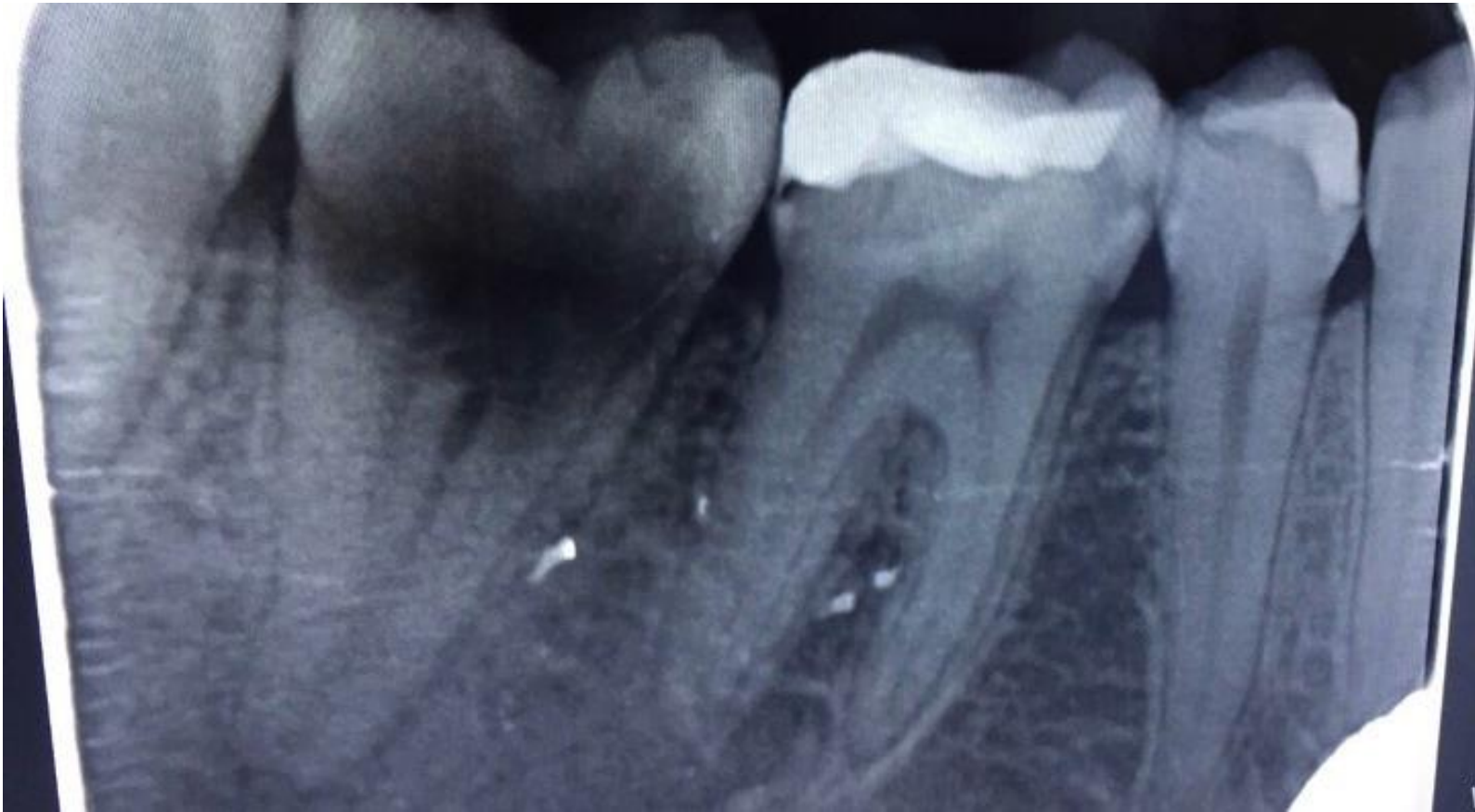Chronic periapical periodontitis .



+ Lower right 2nd molar



+ Intraoral Periapical Radiograph



+ Treatment plan



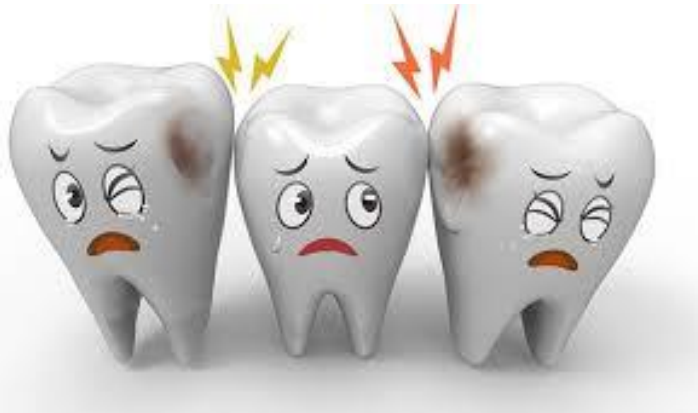Phase III therapy :

- Restoration of decayed


7 6	2	4 5 6 7
6 5		

- Replacement of missing

7		6



+ Different treatment options

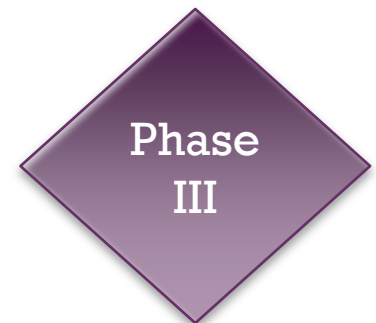

Restorations choices :

■ Composite	★	67	2	4 5 6 7
■ Amalgam		5		
■ GIC				
■ Onlay / inlay	★	6		

Replacement choices :

■ Removable partial denture				
■ Replacement of missing conventional fixed – fixed FPD			6	with tooth supported
■ Implant				
■ Transplantation	★	8		



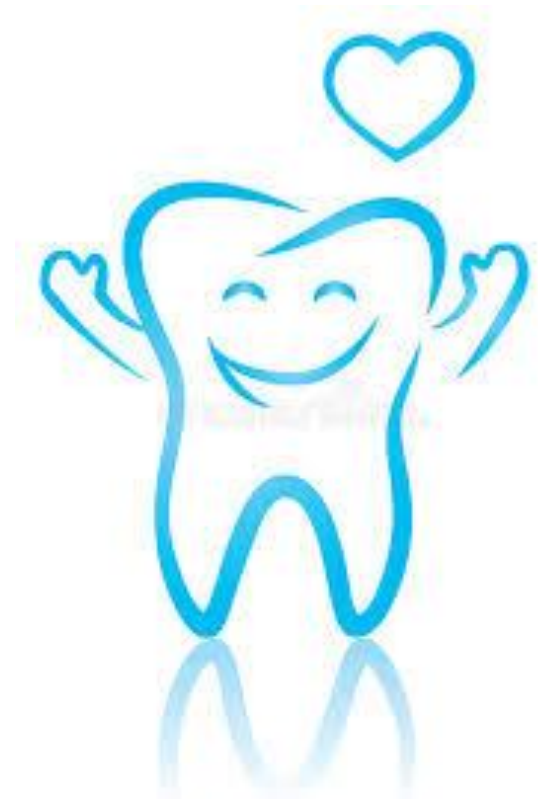+ Phase IV

FOLLOW UP

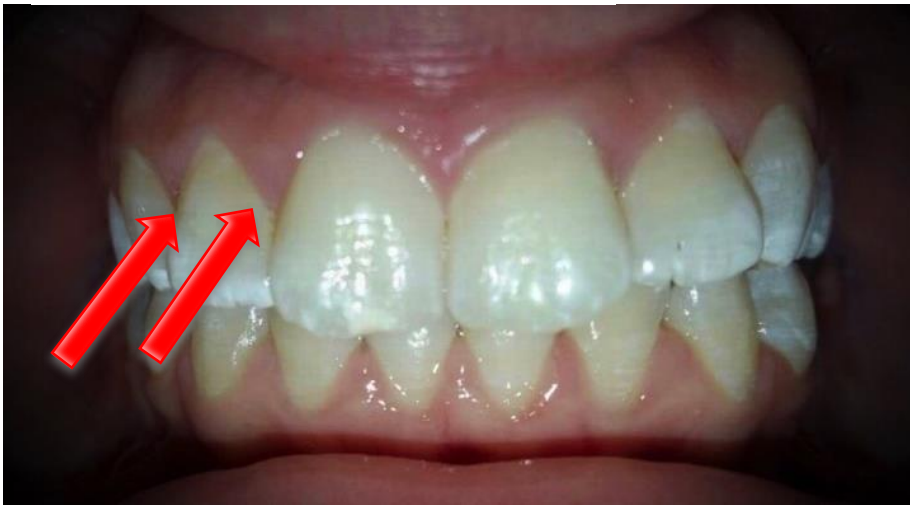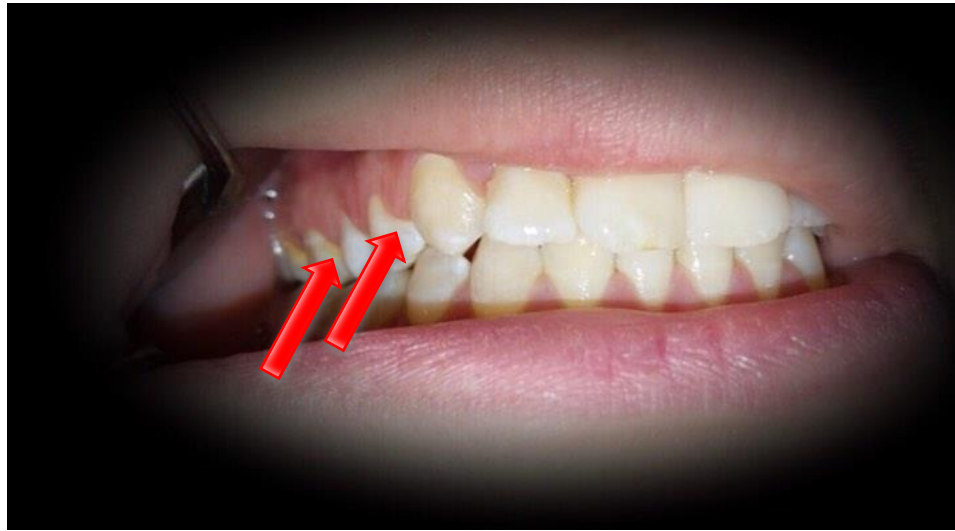



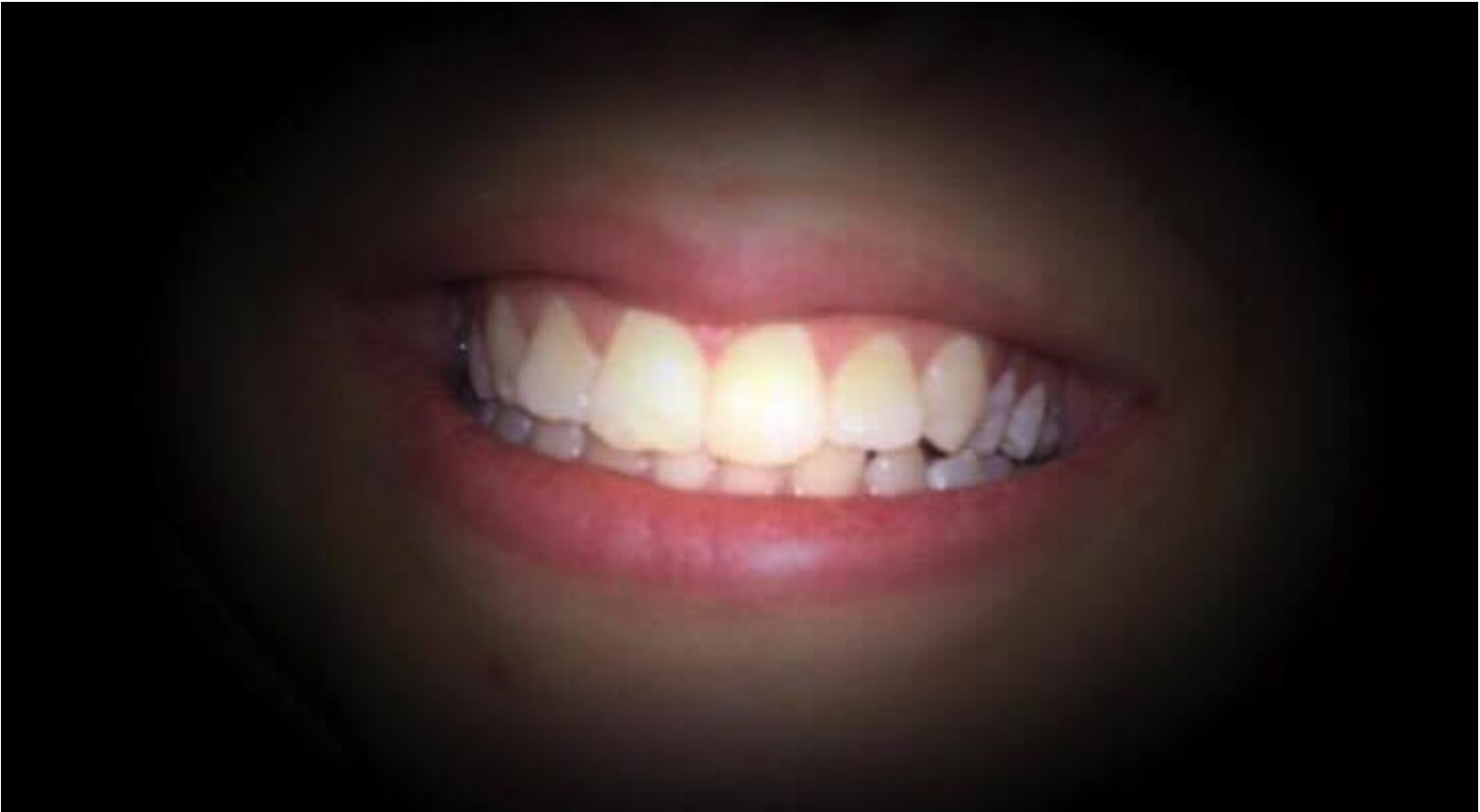+ Reevaluation of Phase I therapy

- P.t was satisfied , the **bleeding on brushing** problem was resolved .
- No plaque or calculus present.
- Pocket within normal depth.



+ Before and after





+ Phase II therapy



- This phase of treatment was shifted to be done after **phase III**.

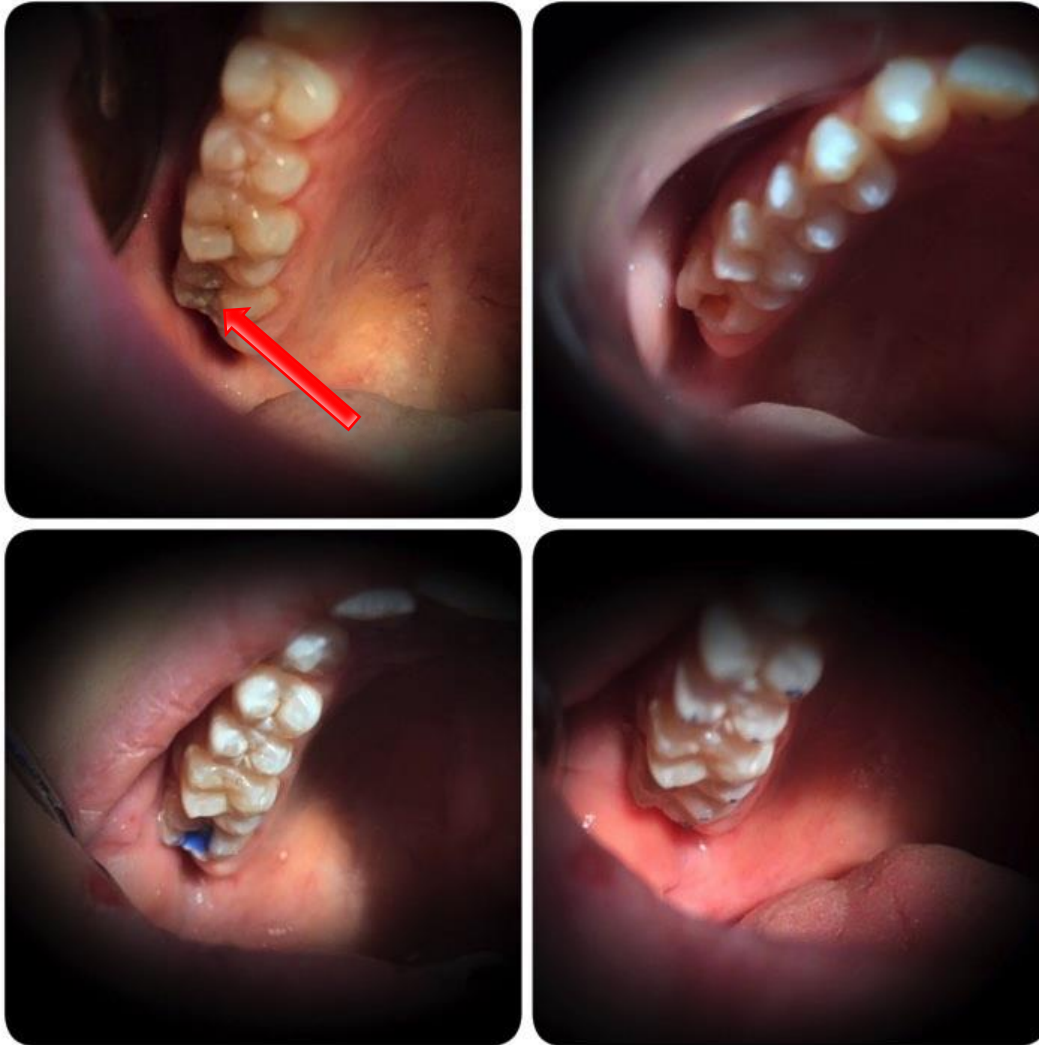


+ Phase III – part 1

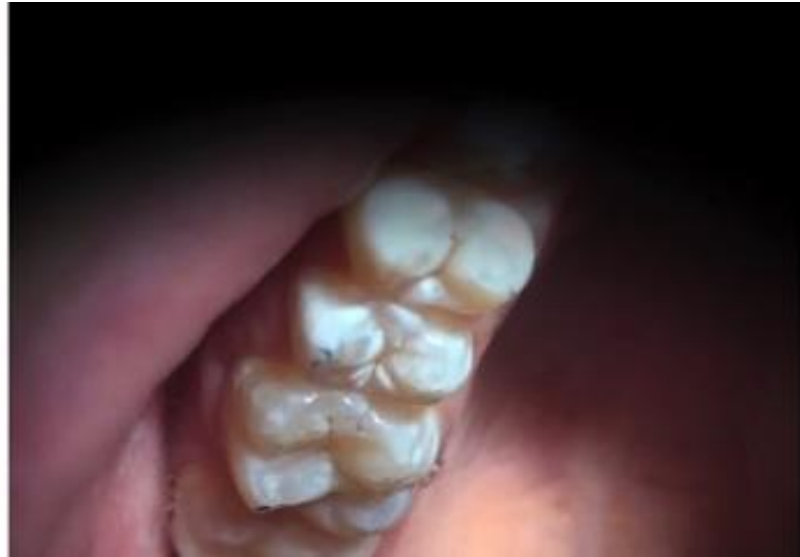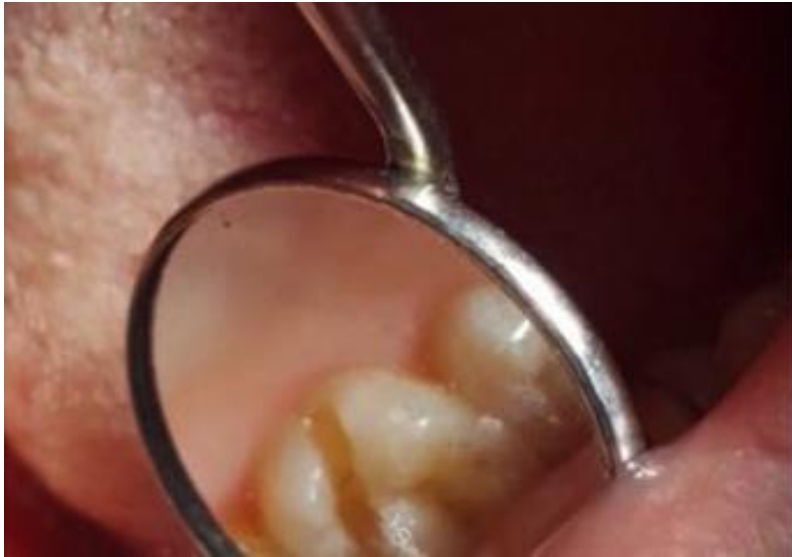- **Restoration of carious teeth .**



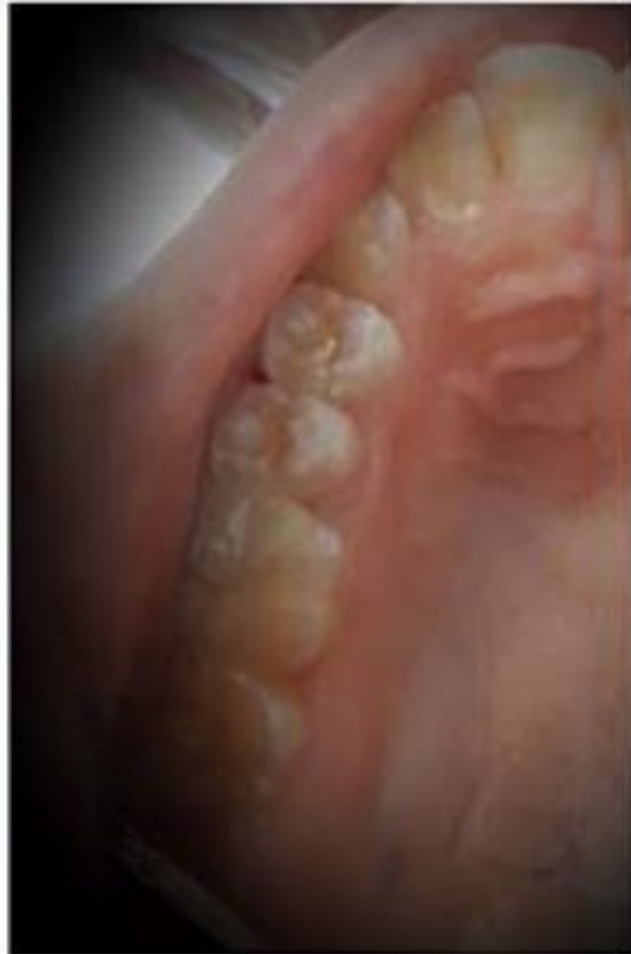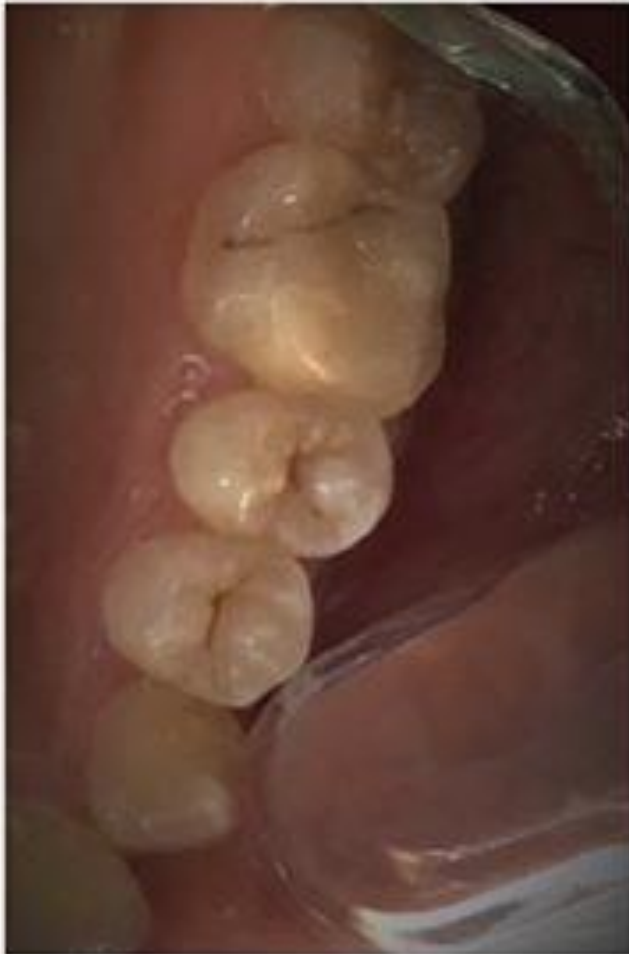+ Upper right 2nd molar



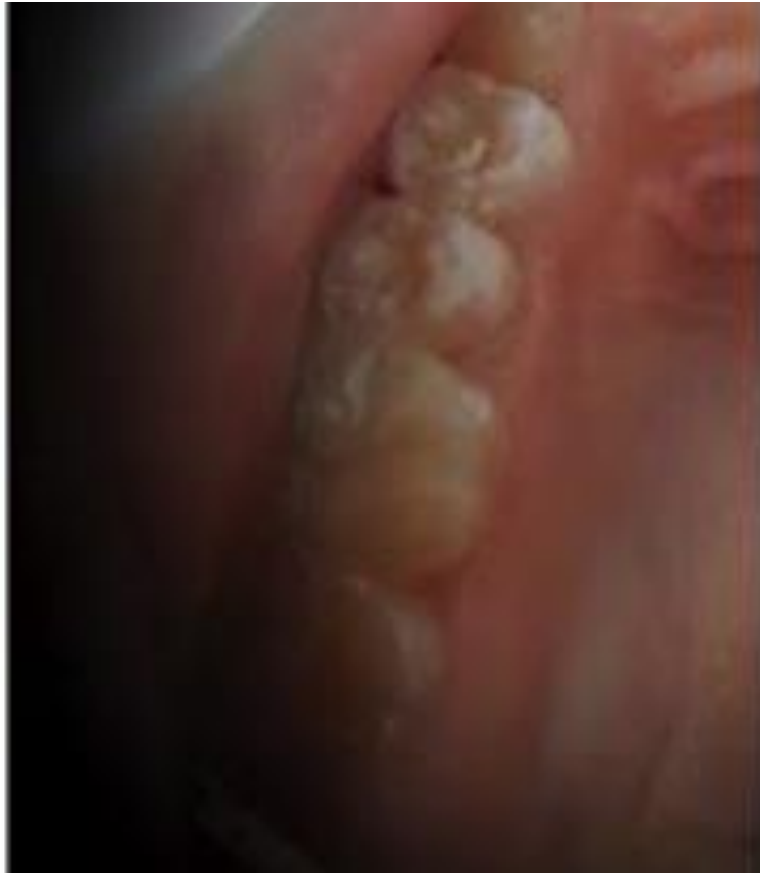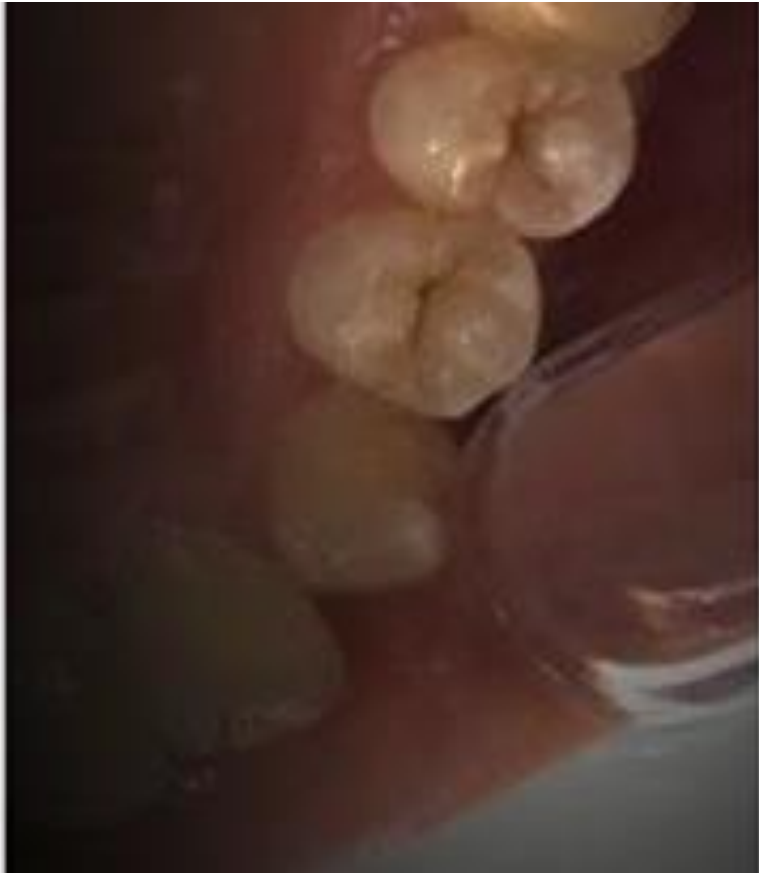+ Upper right 1st molar



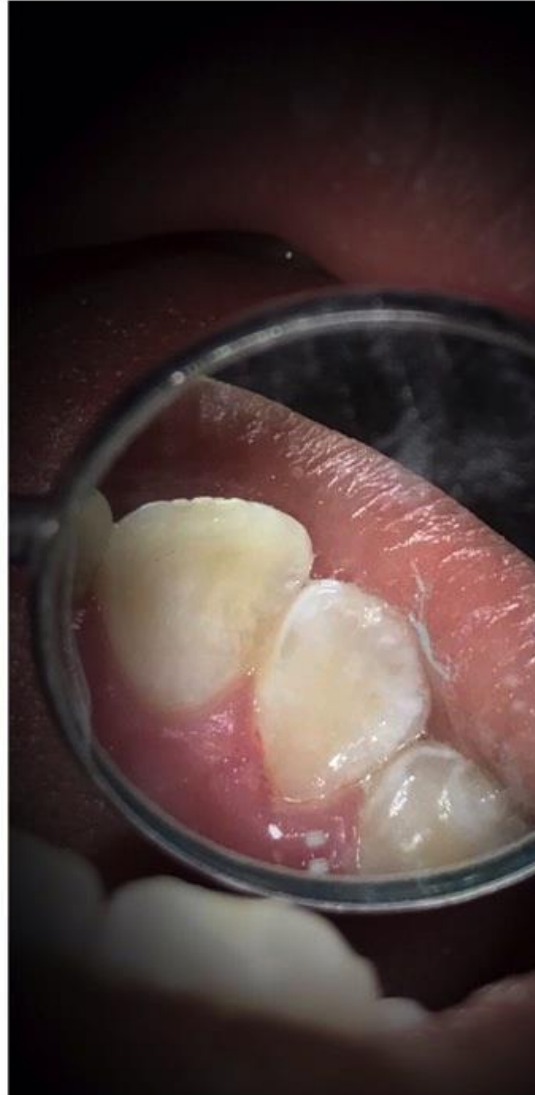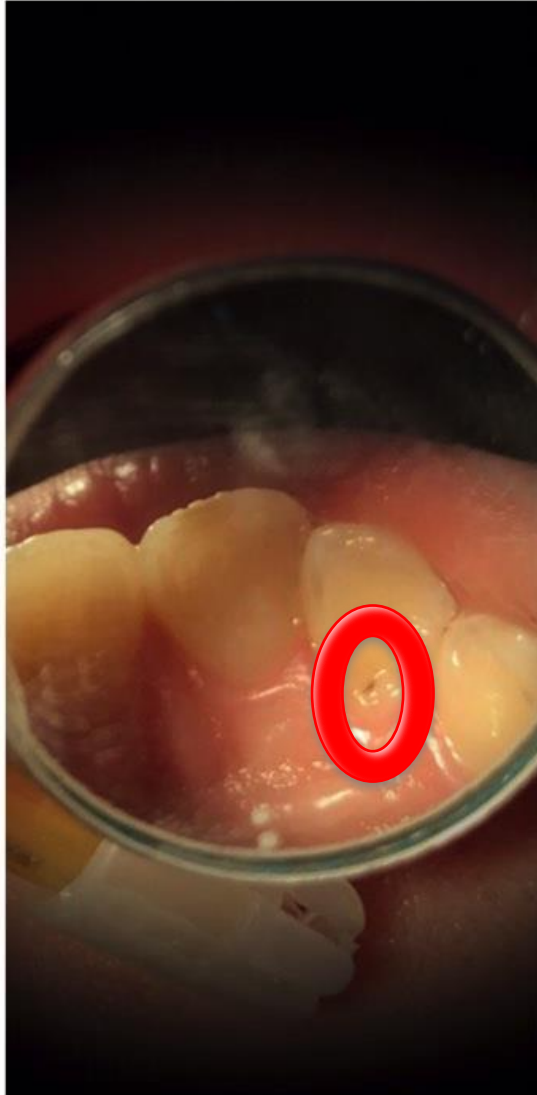+ Upper left 1st molar



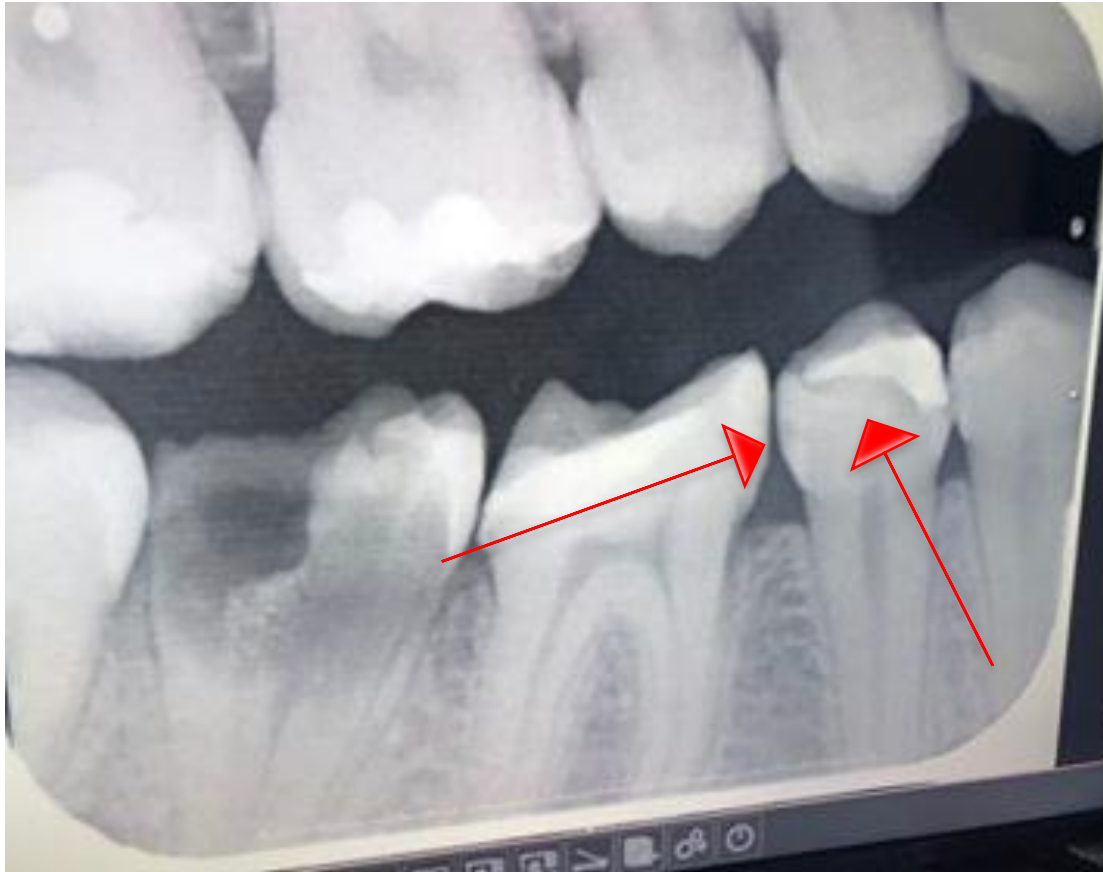+ Upper left 1st & 2nd premolars



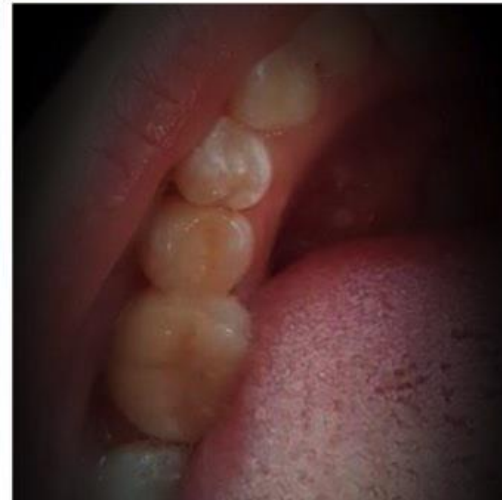
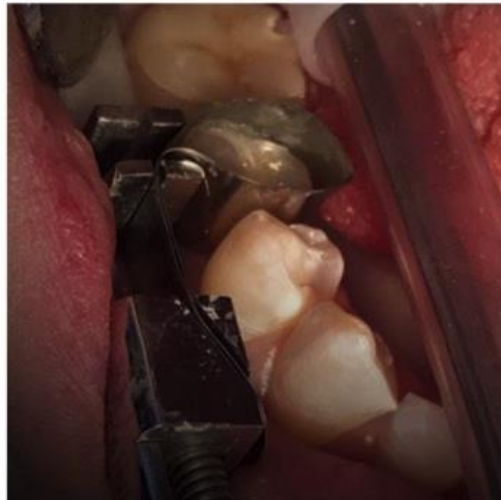
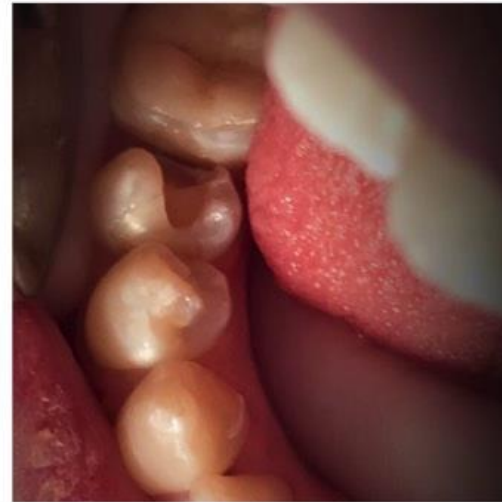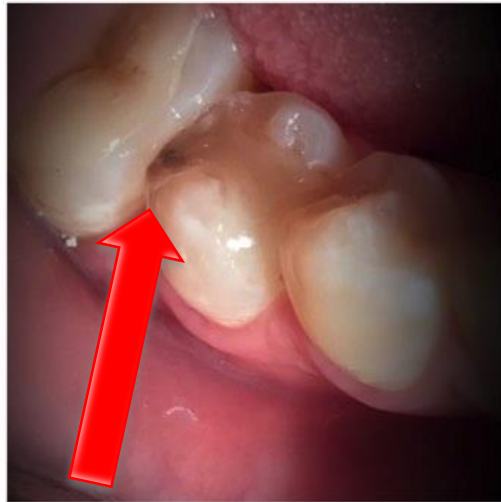+ Upper right lateral incisor



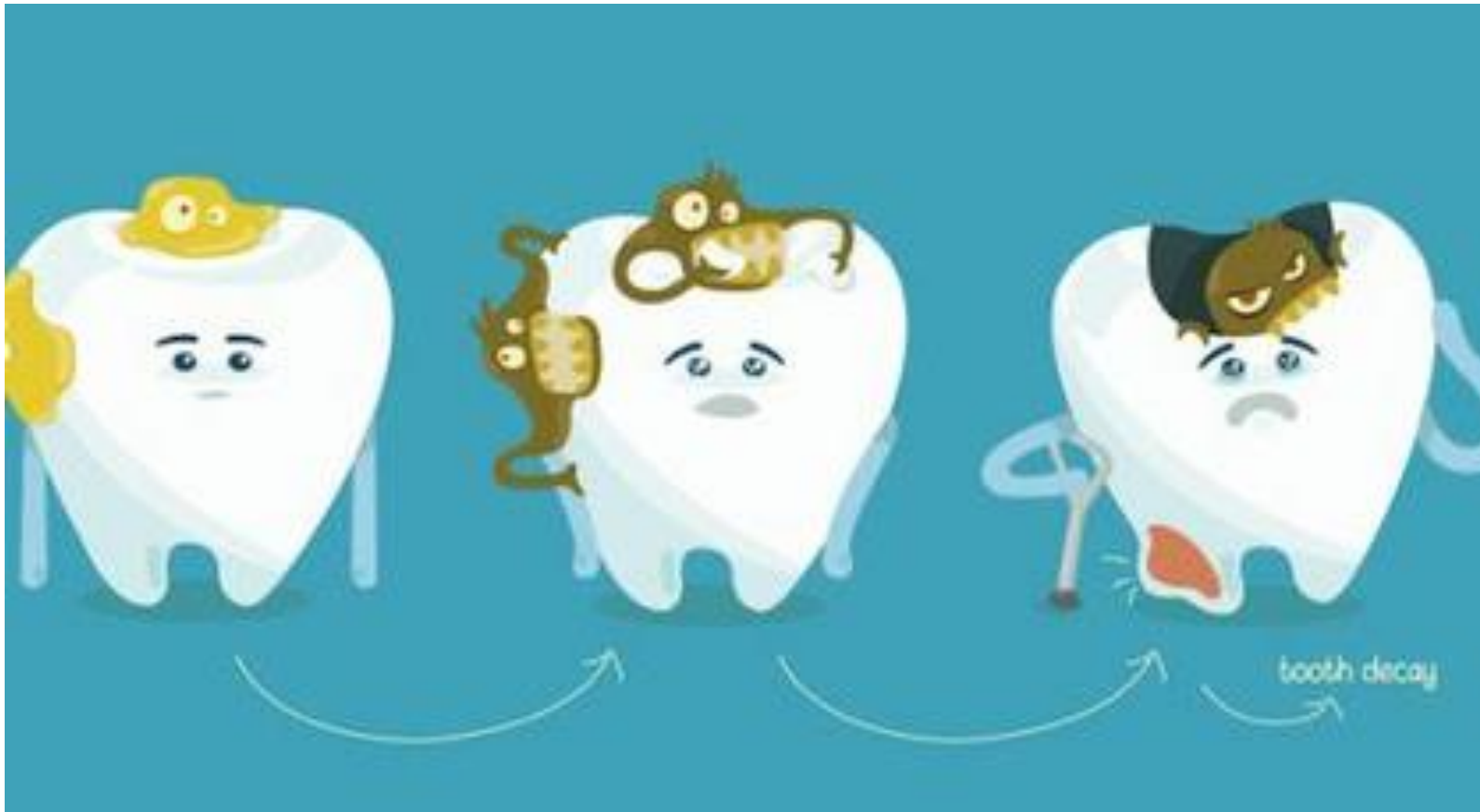+ Lower right 2nd premolar



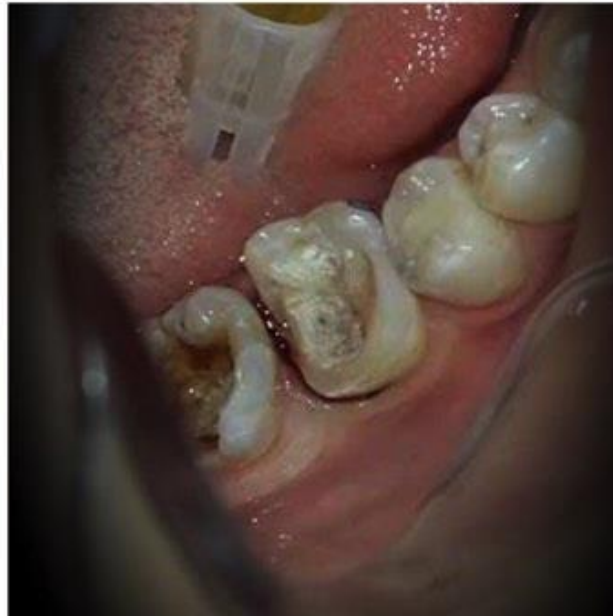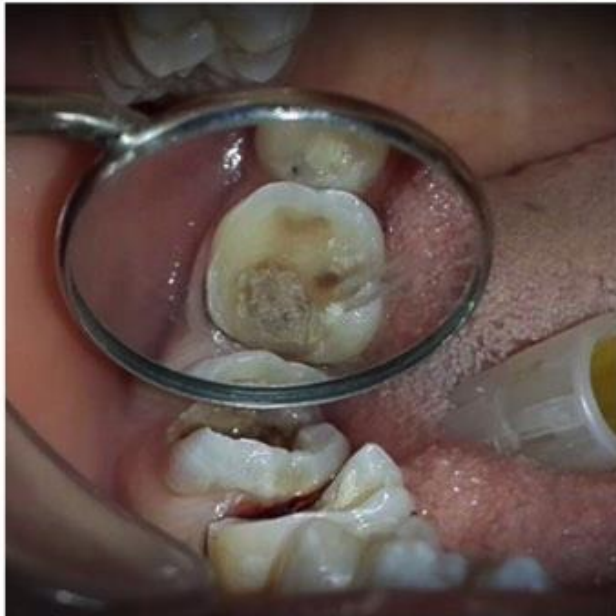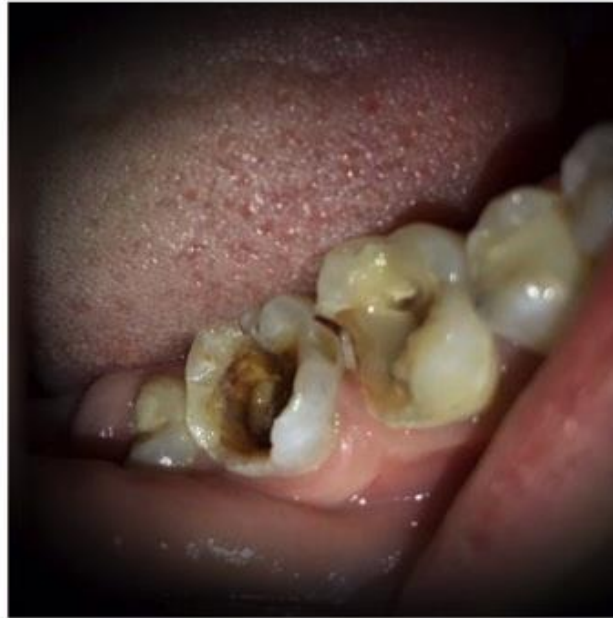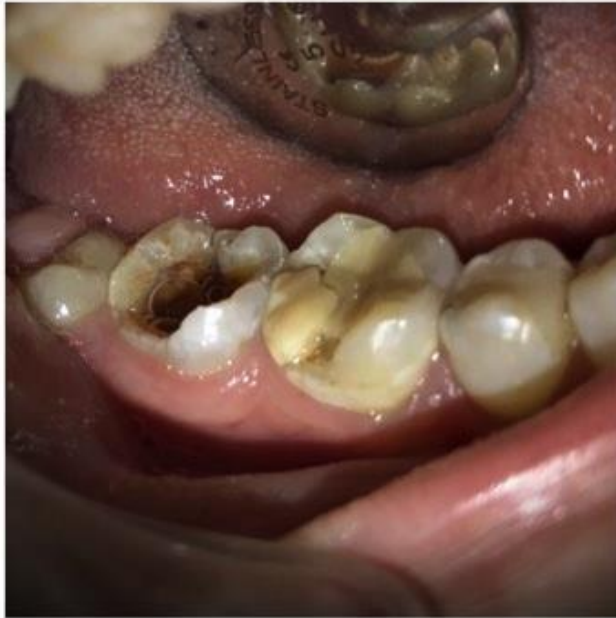+ Lower right 2nd premolar



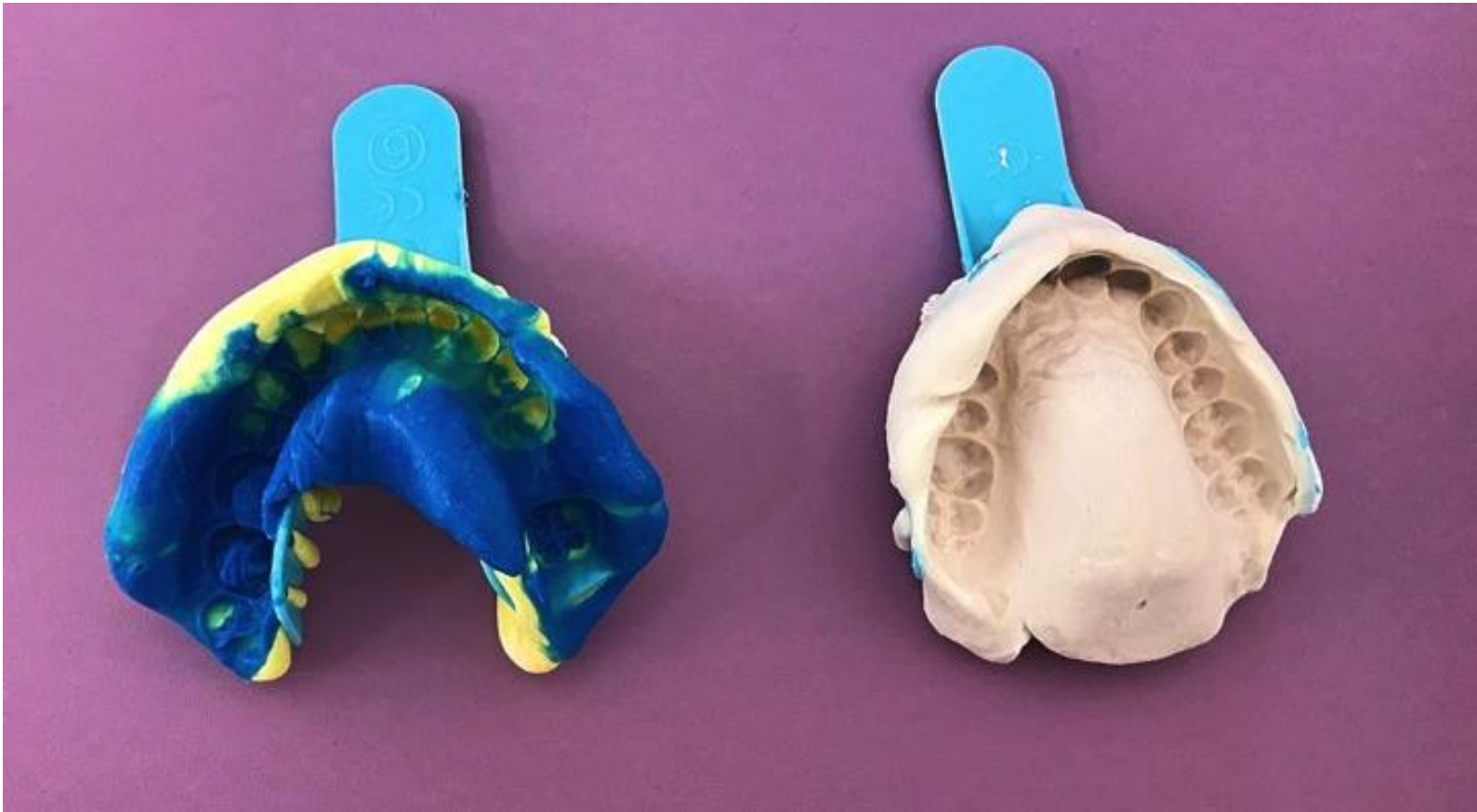+ Phase III – part 2 (indirect restoration)

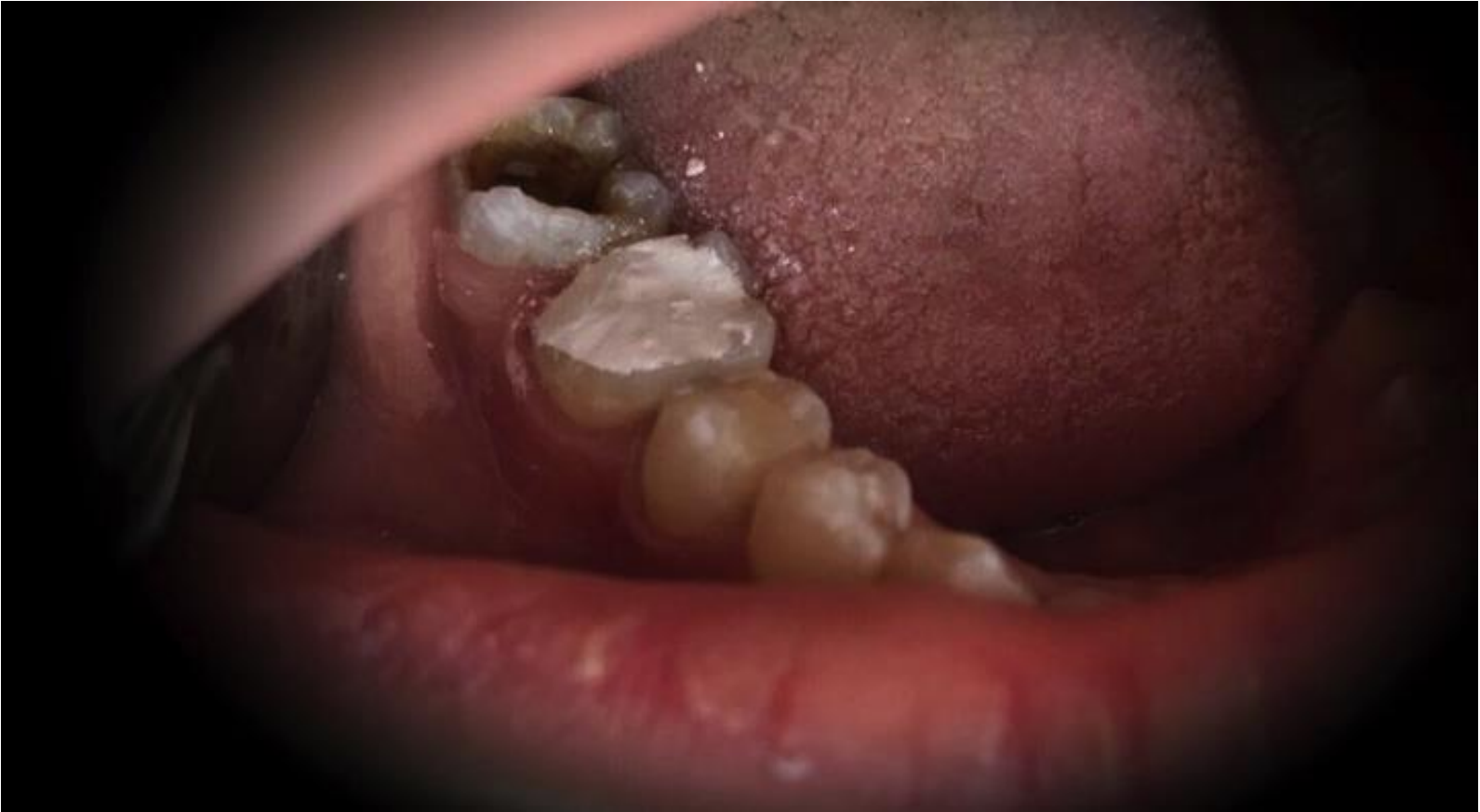


+ Lower right 1st molar – onlay preparation

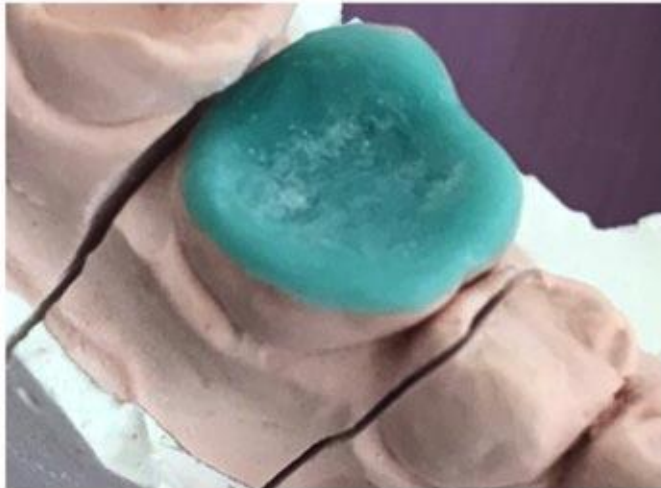
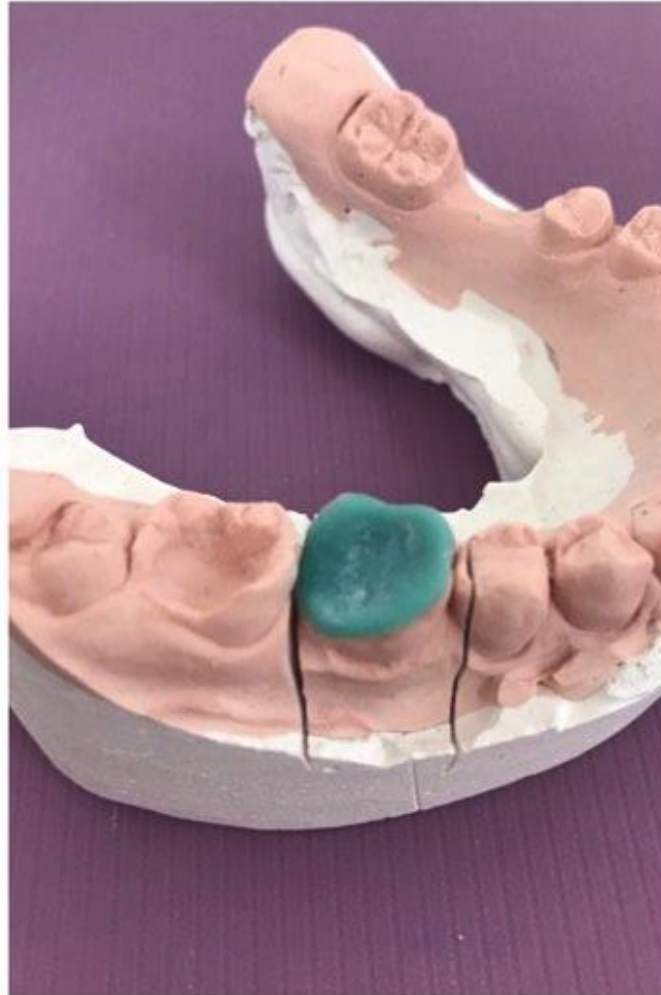
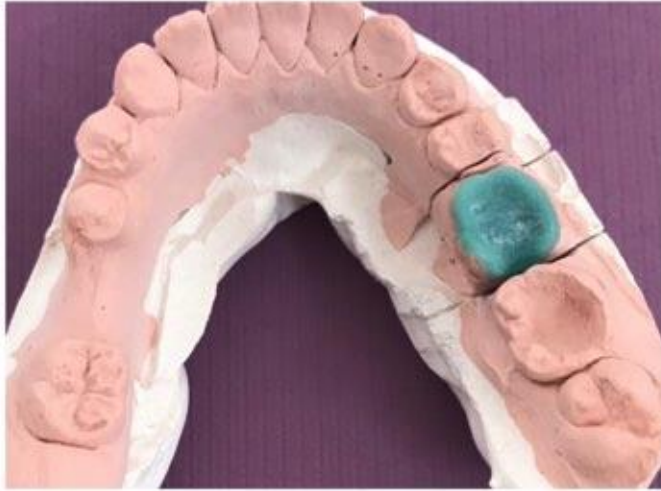+ Impression

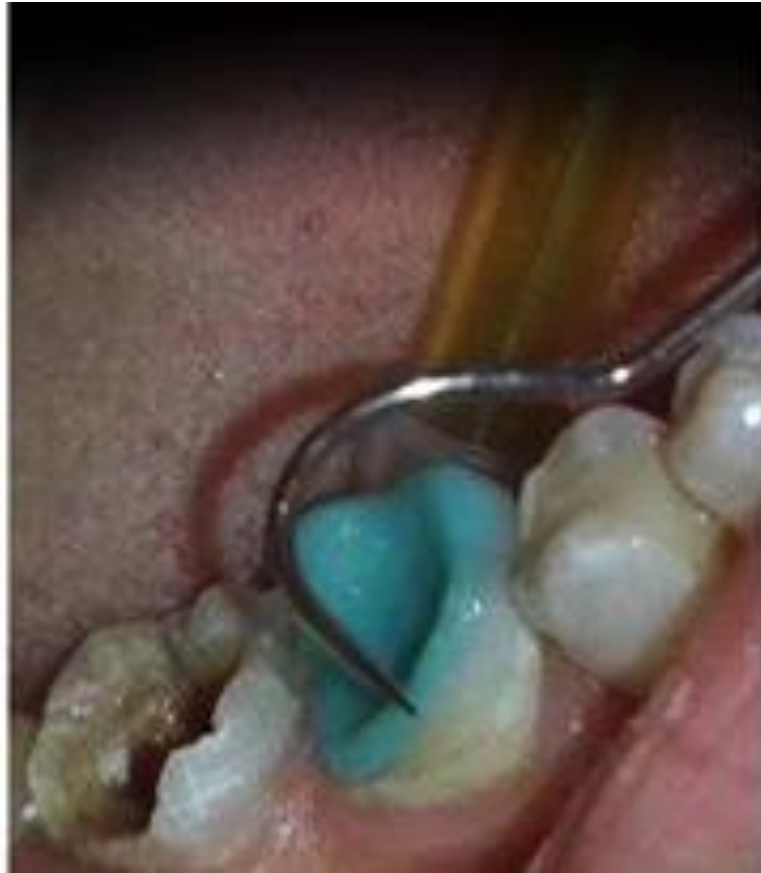
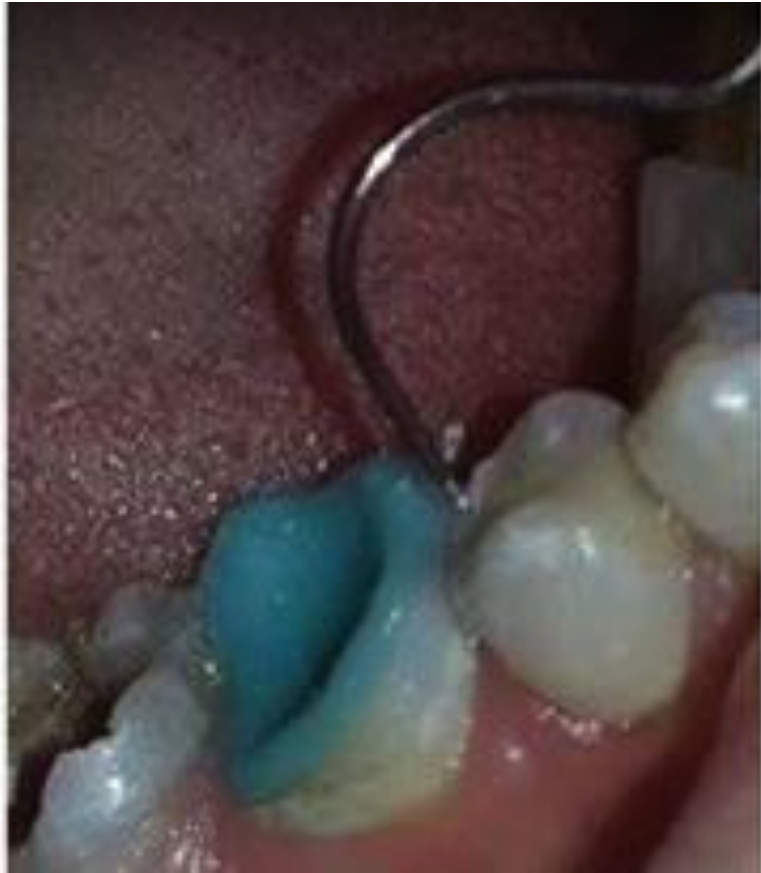


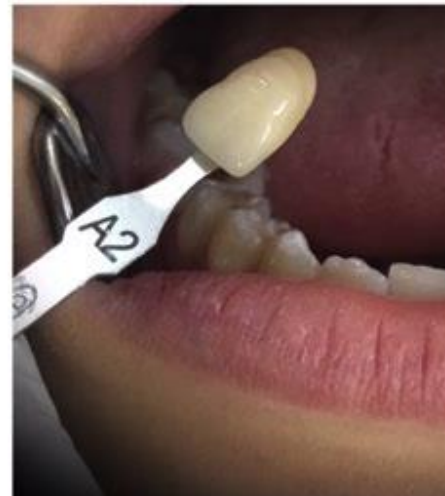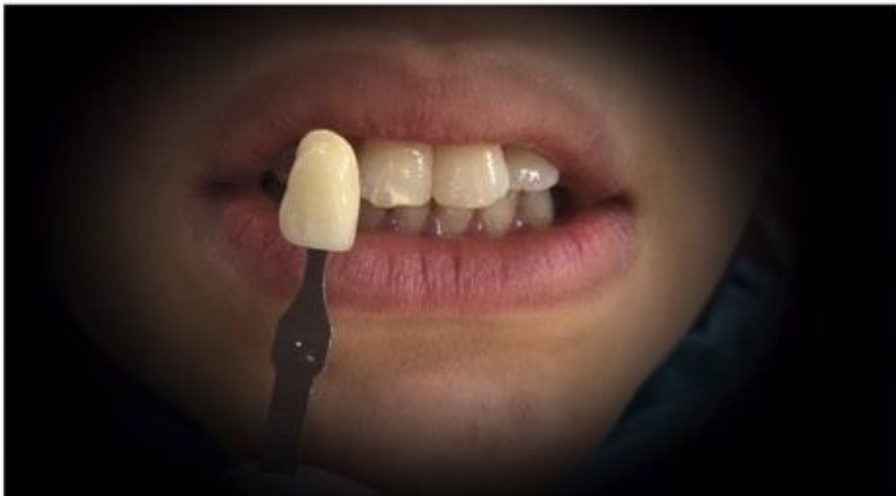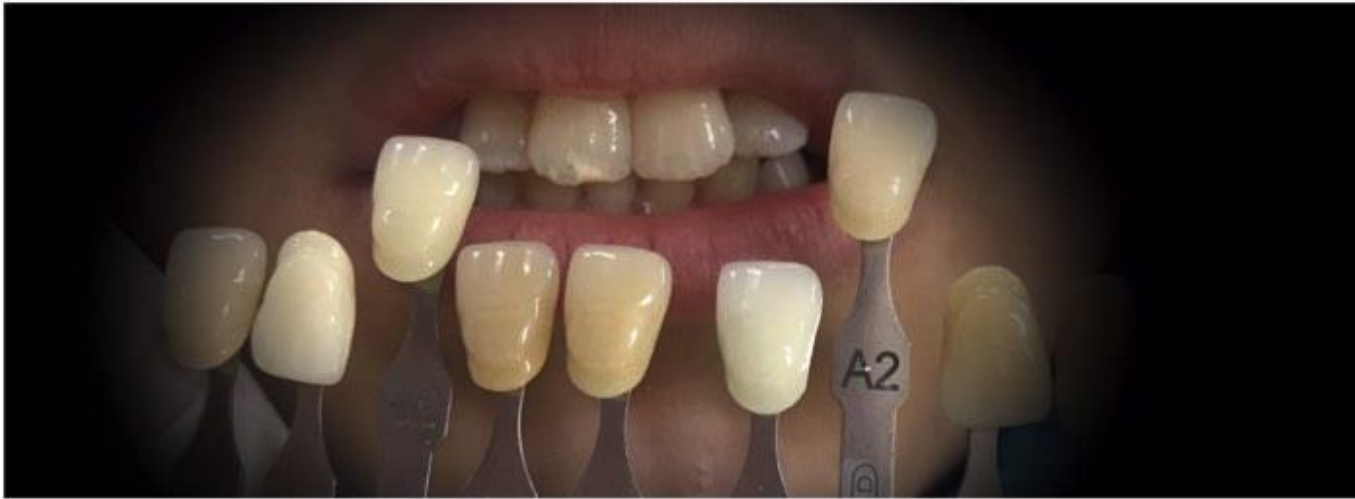+ composite try-in



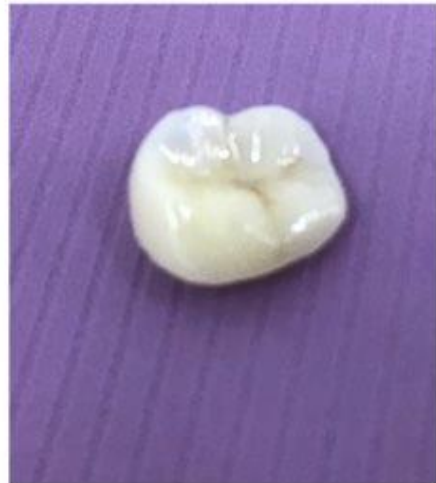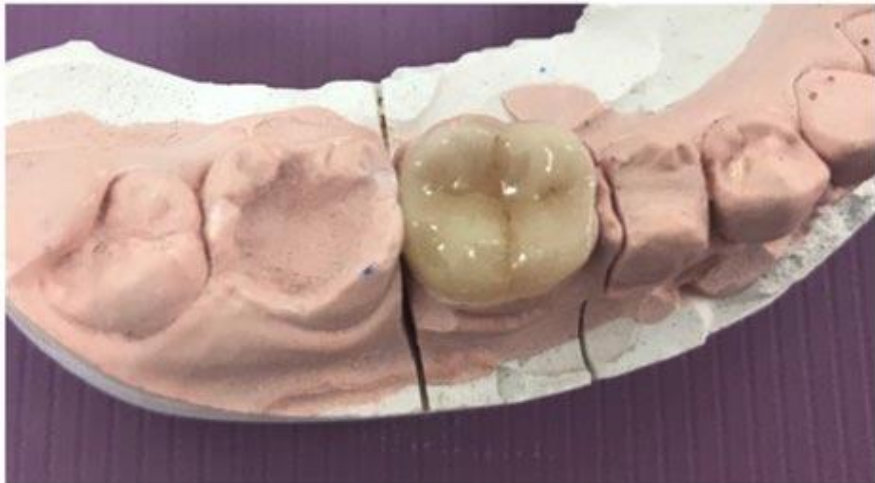
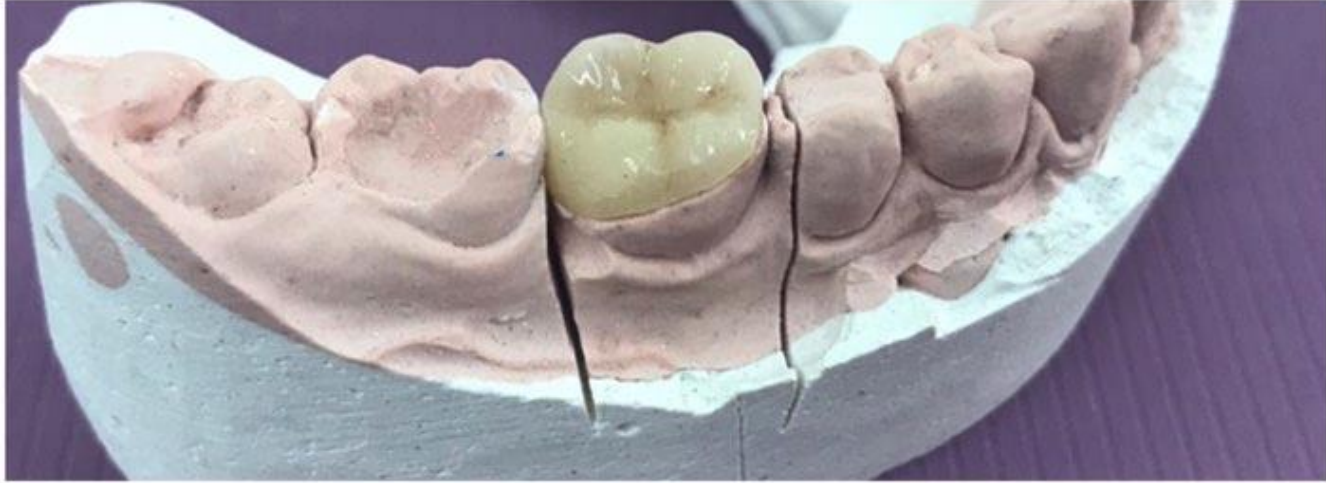
+ Acrylic try-in



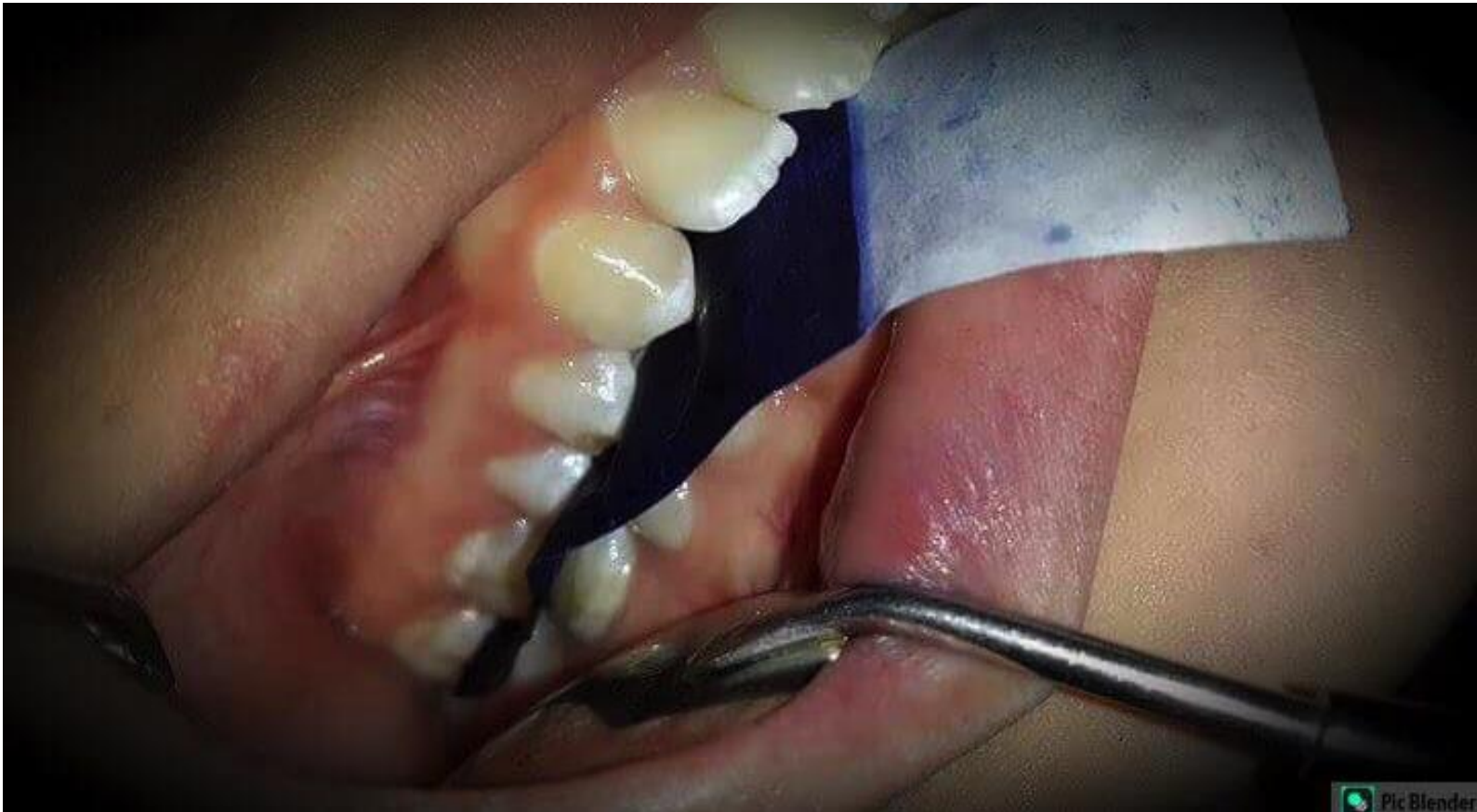+ Shade selection



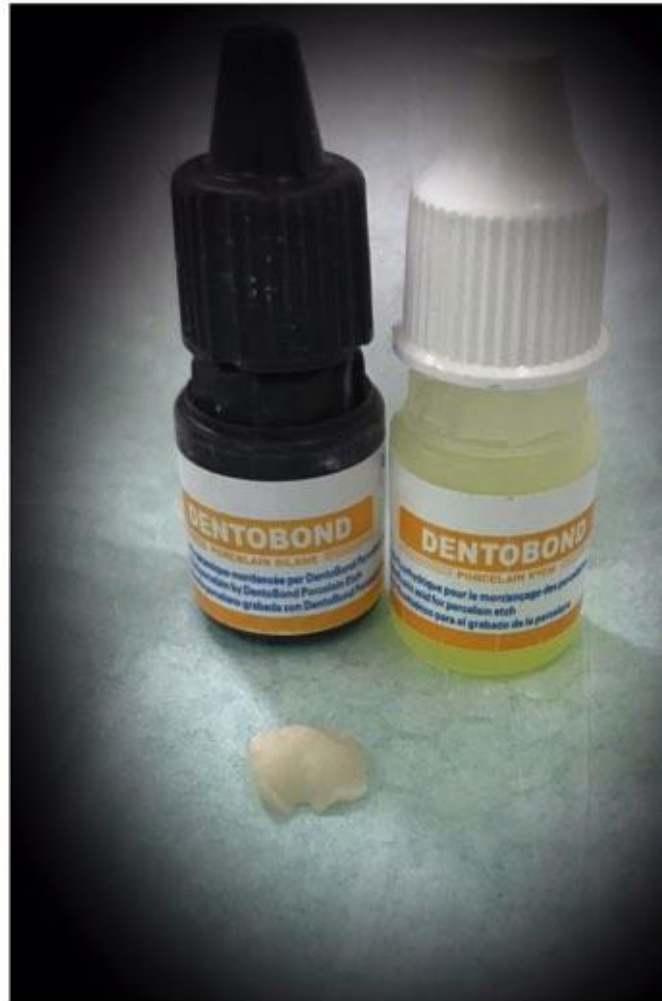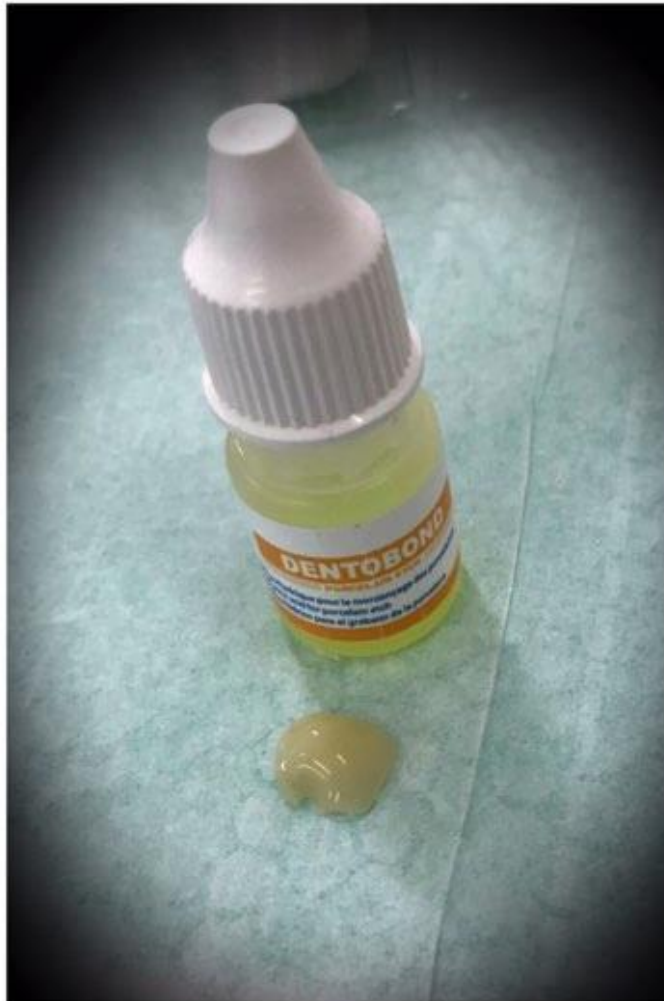+ E-max onlay



+ Occlusal adjustment



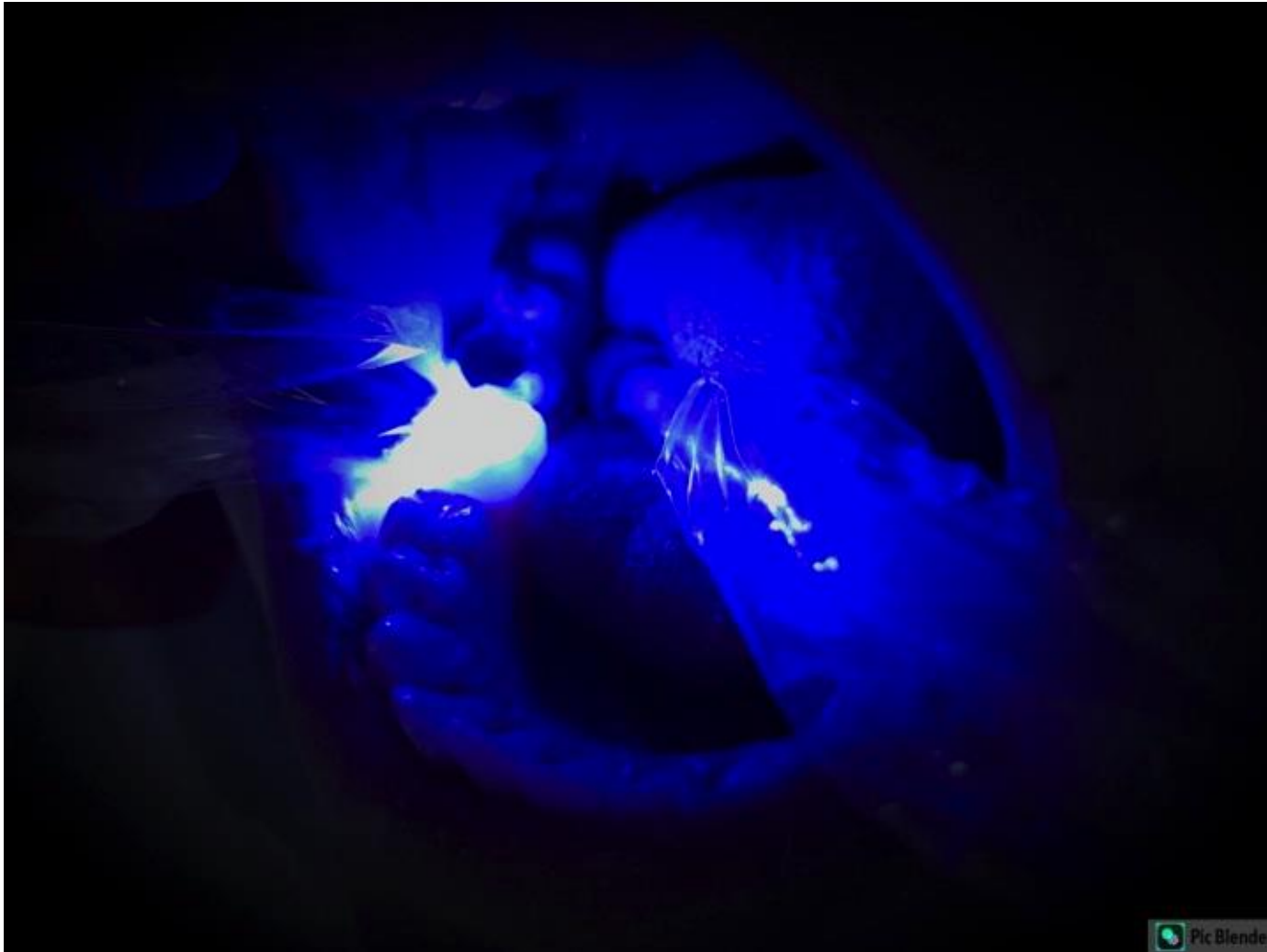
+ Onlay surface treatment

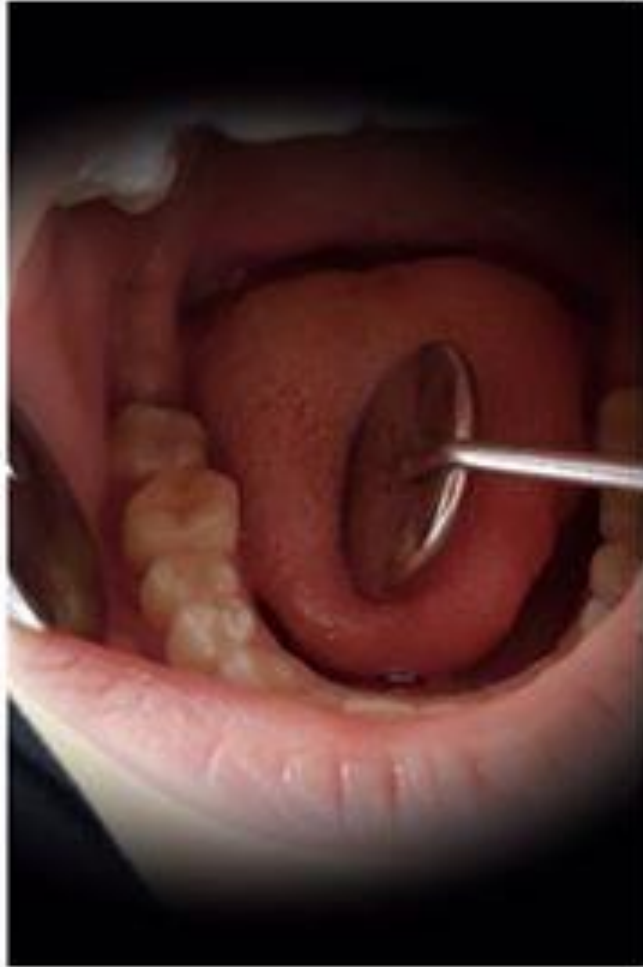
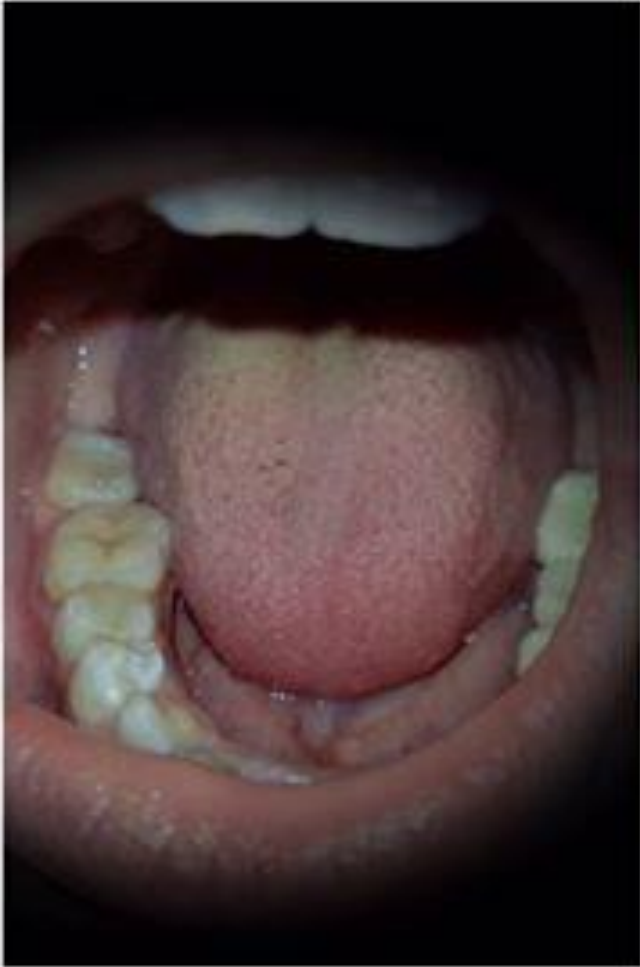

+ Self etching , self adhesive resin cement

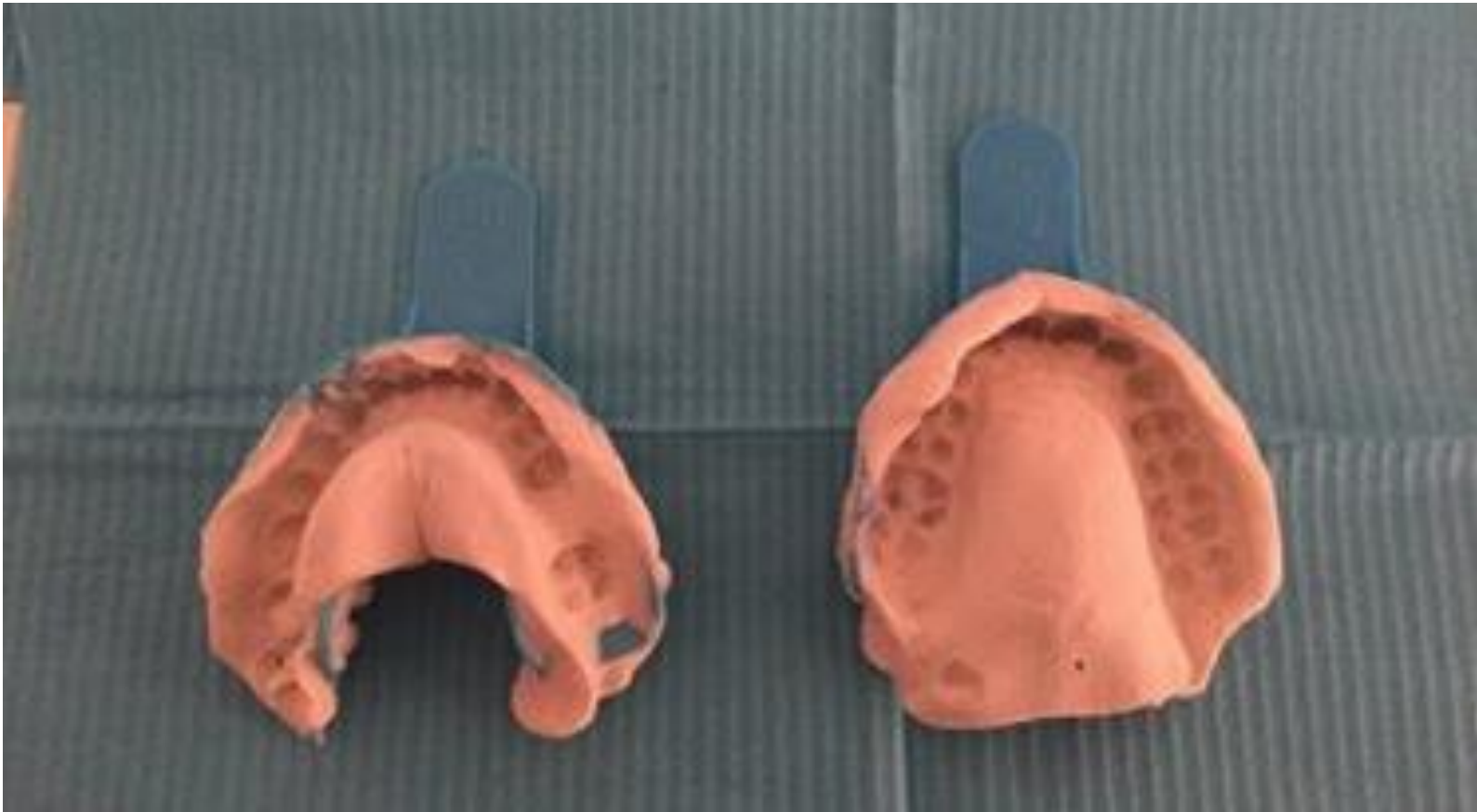


+ Cementation dual

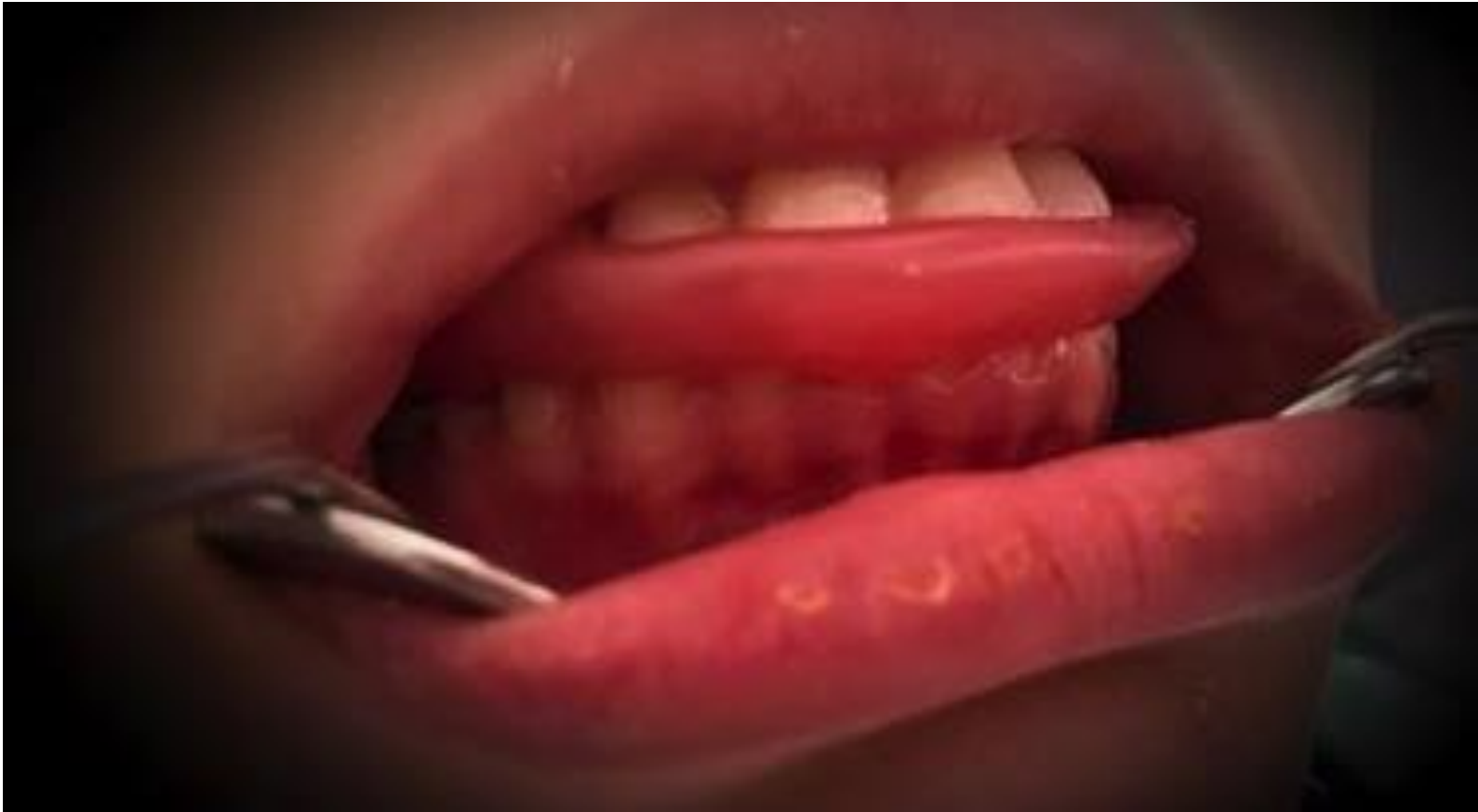



+ Primary impression



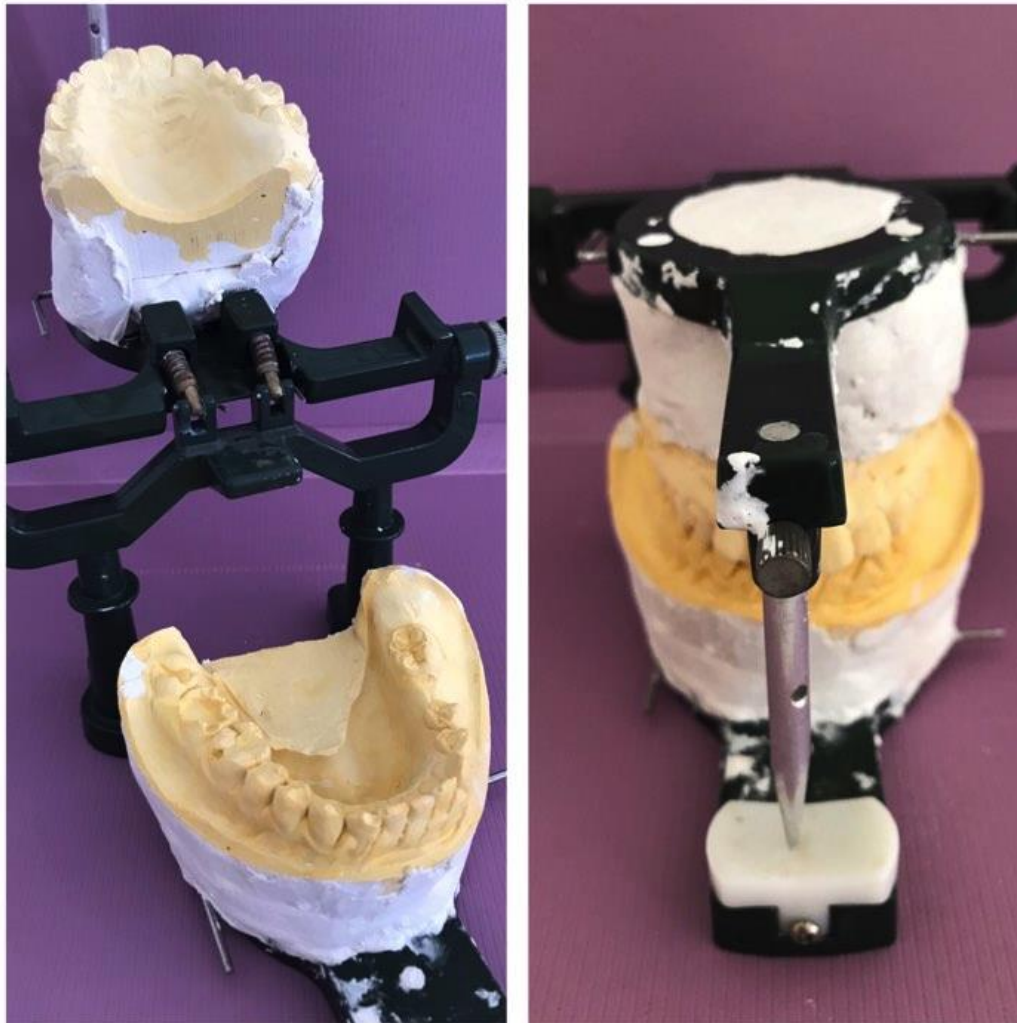+ Bite registration



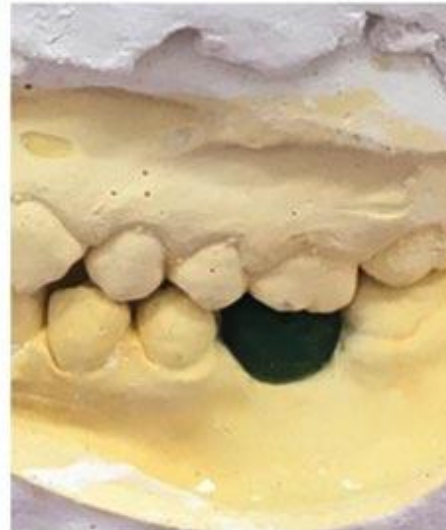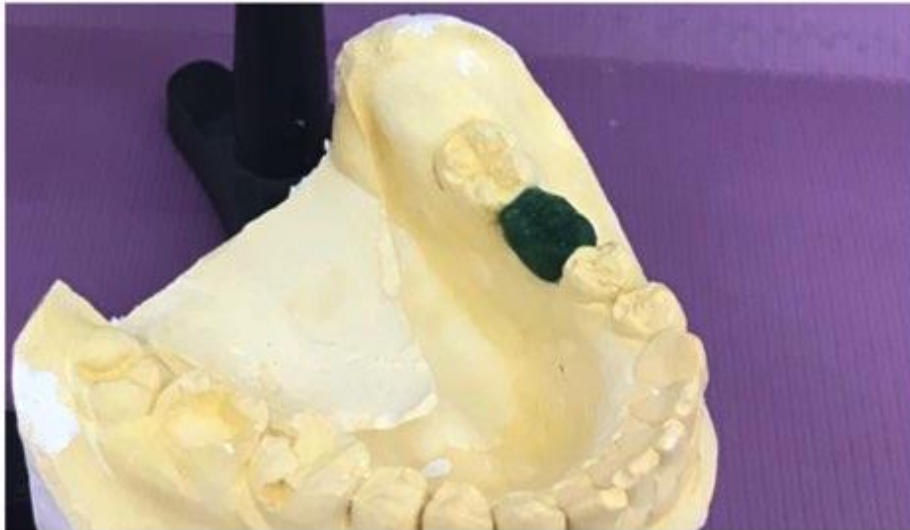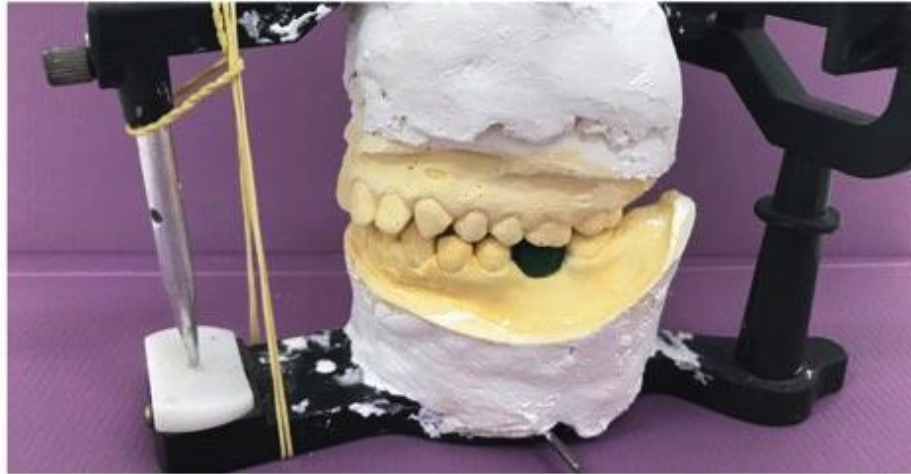
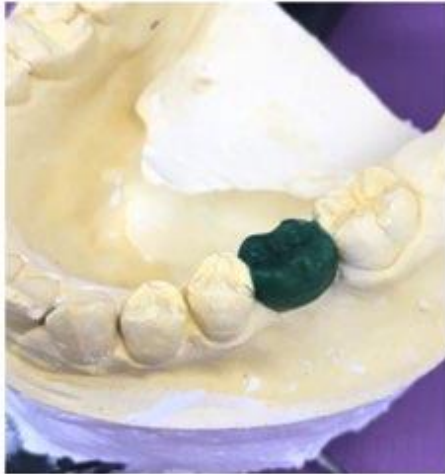+ Diagnostic casts mounted on an articulator



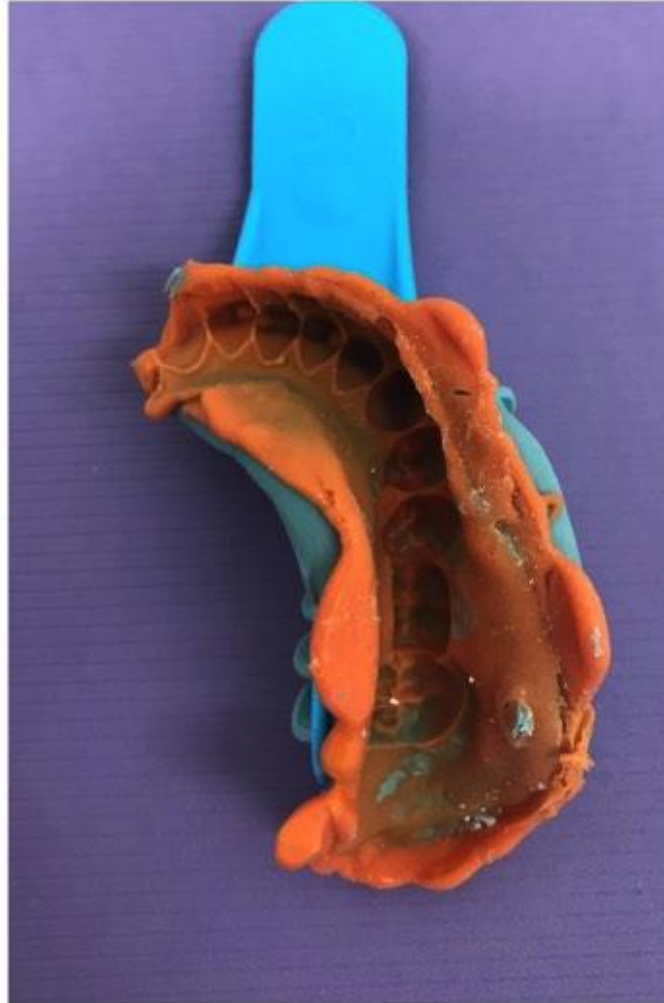
+ Diagnostic casts mounted on an articulator



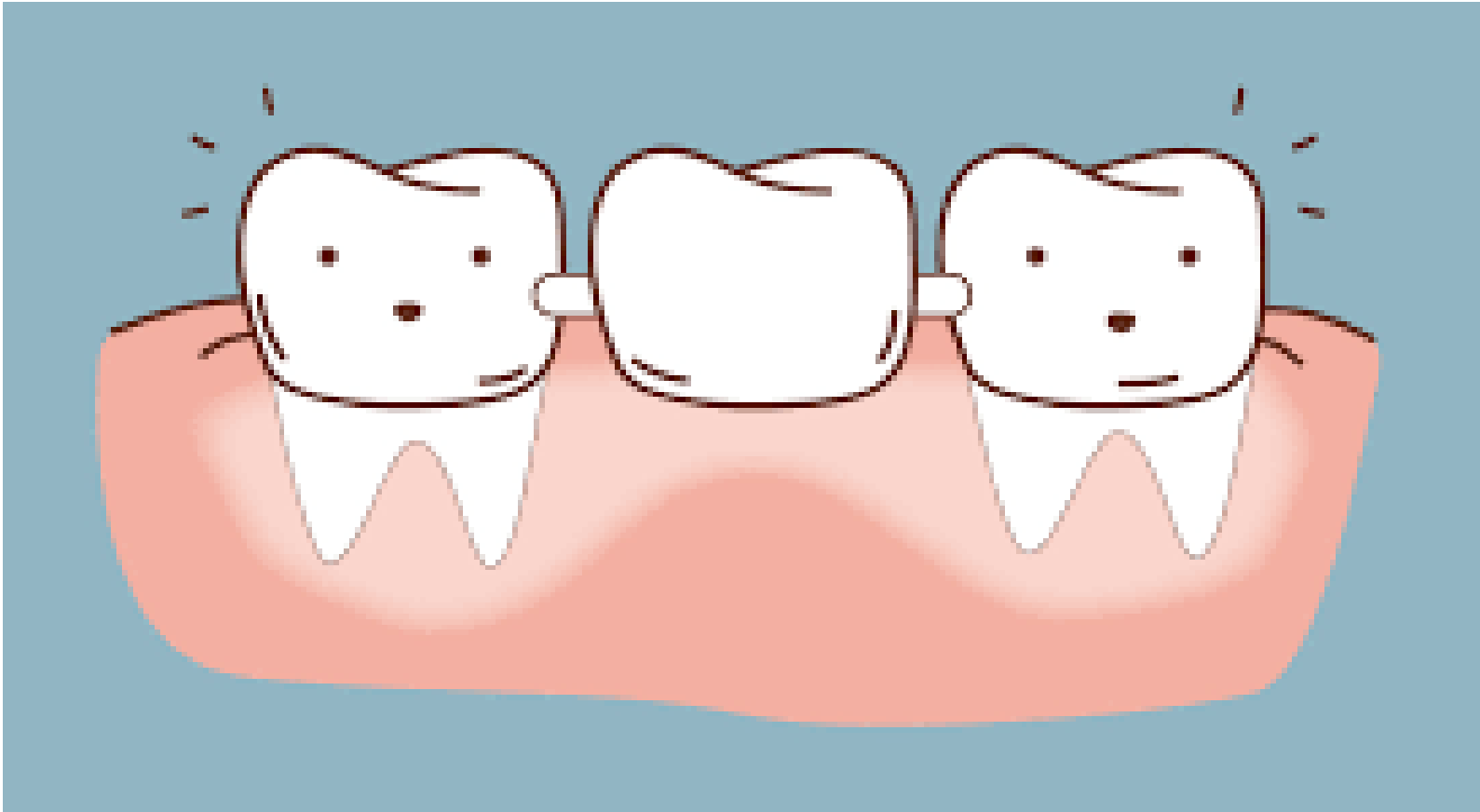
+ Wax -up



+ Index taking for the purpose of provisional bridge fabrication



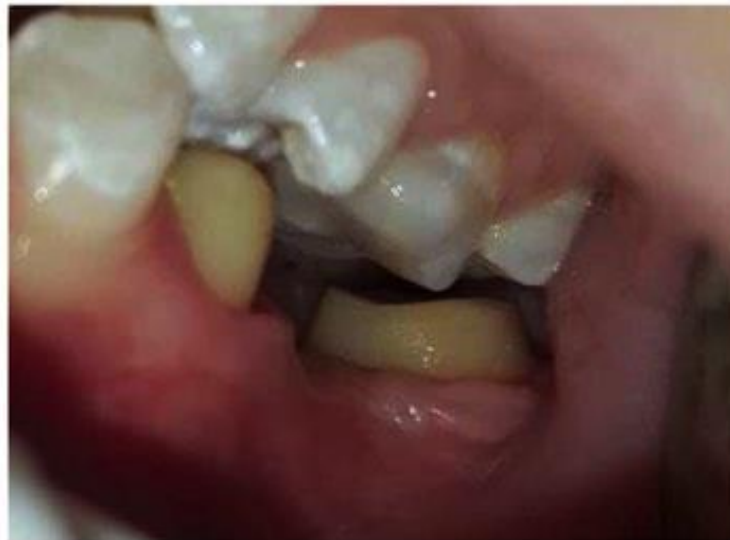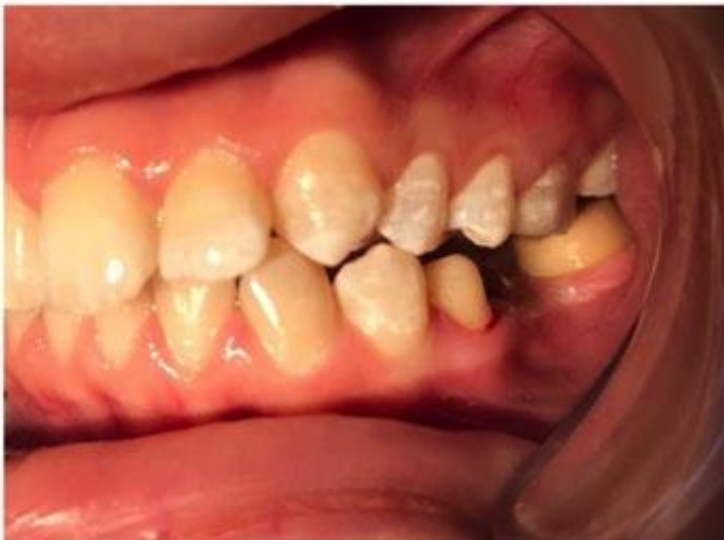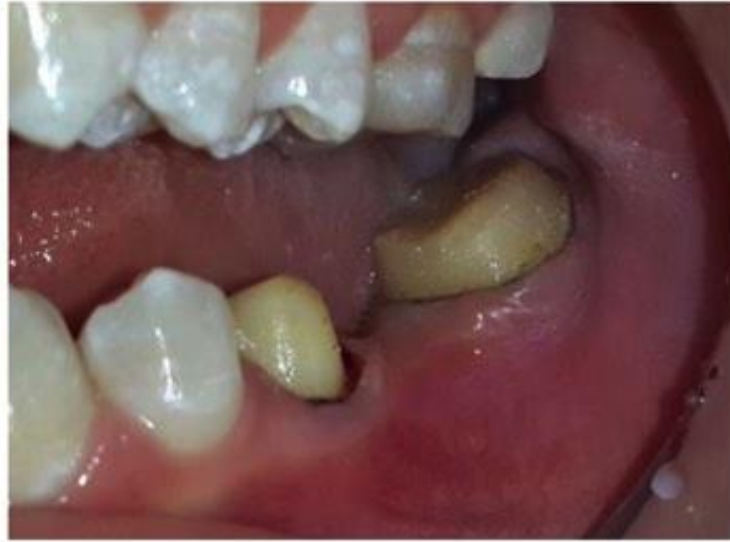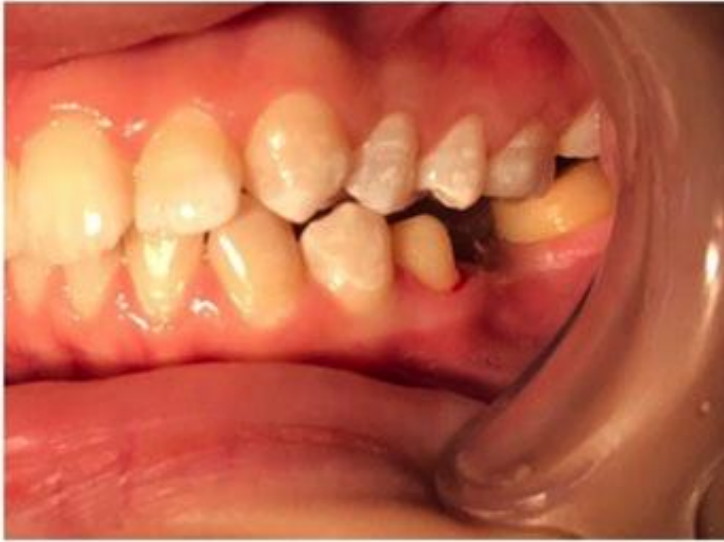- + Phase III part 3 – replacement of missing lower left 2nd molar by PFM bridge



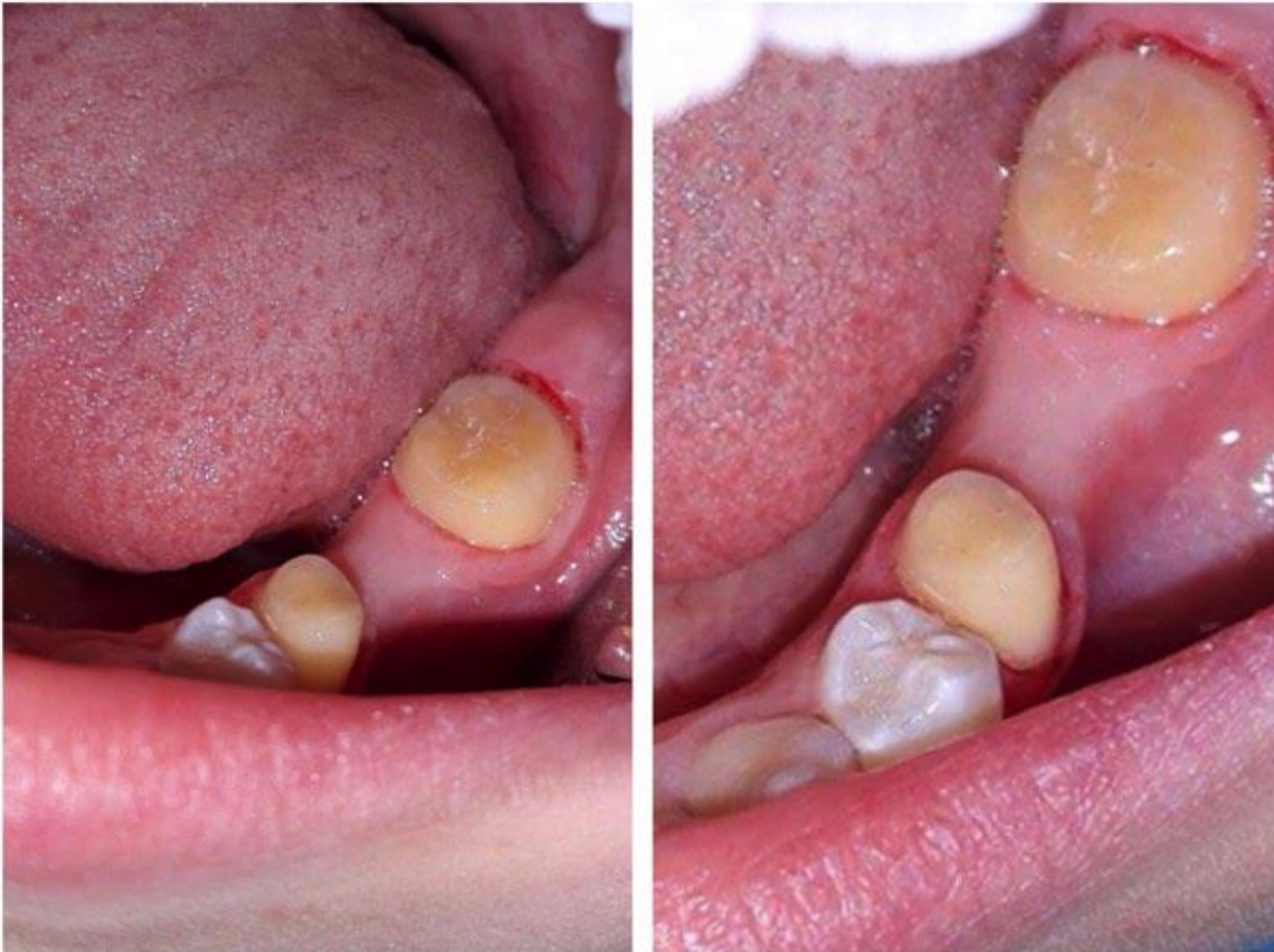+ Bridge preparation of L 5X7



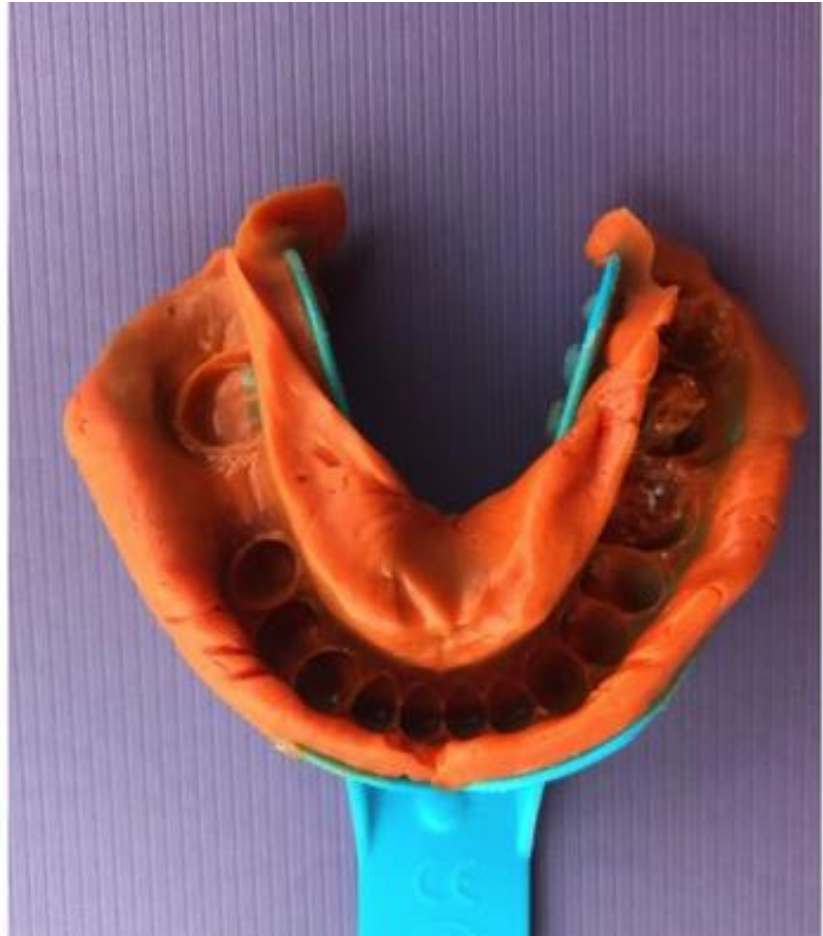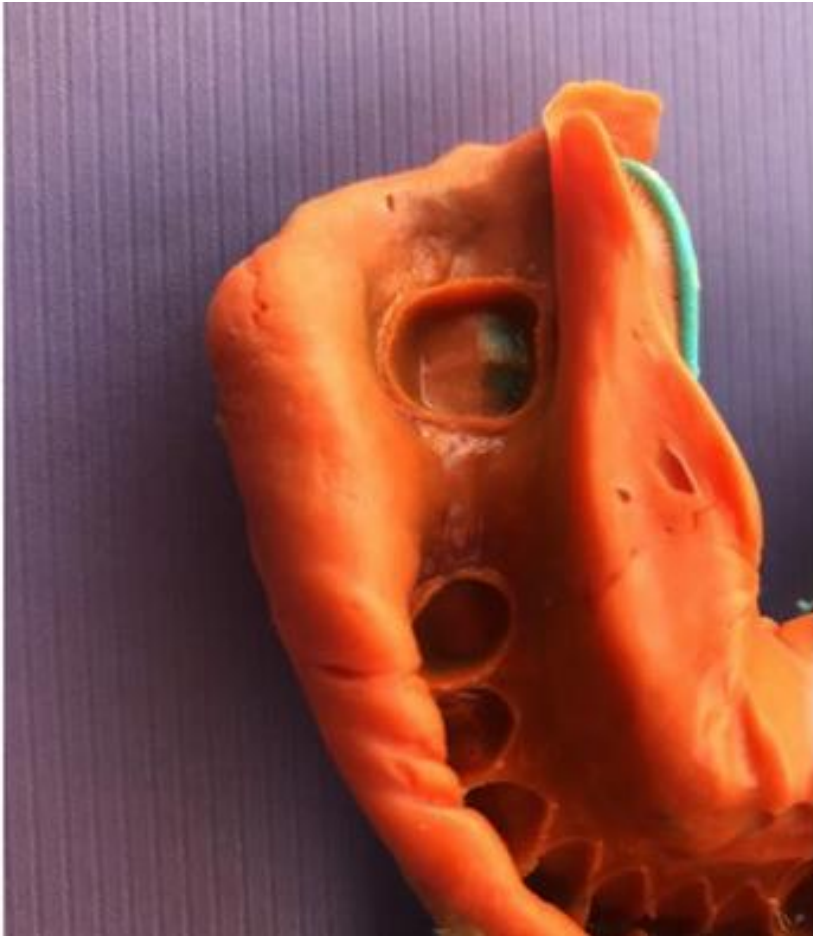+ Preparation of the abutment teeth



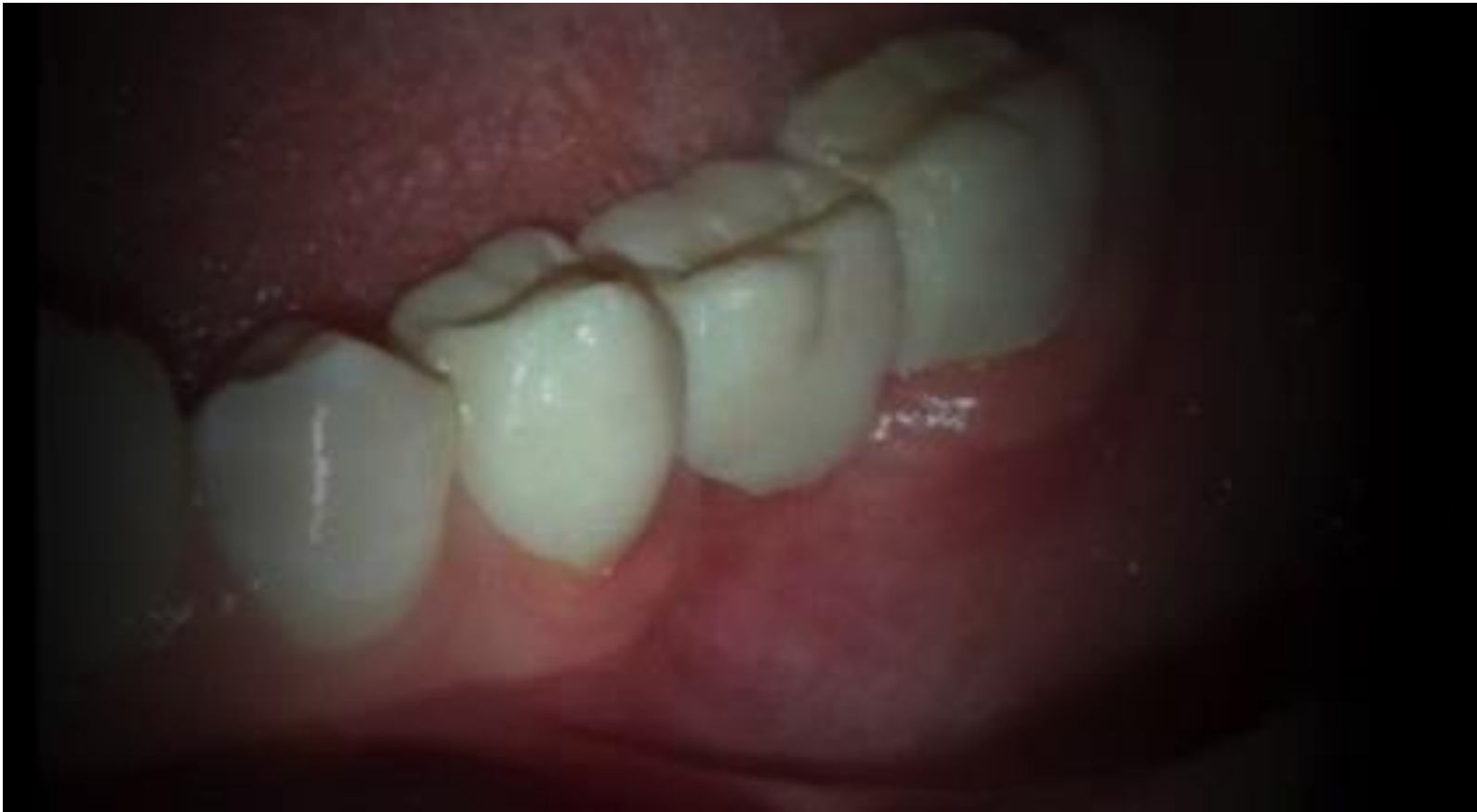+ Gingival retraction before final impression making



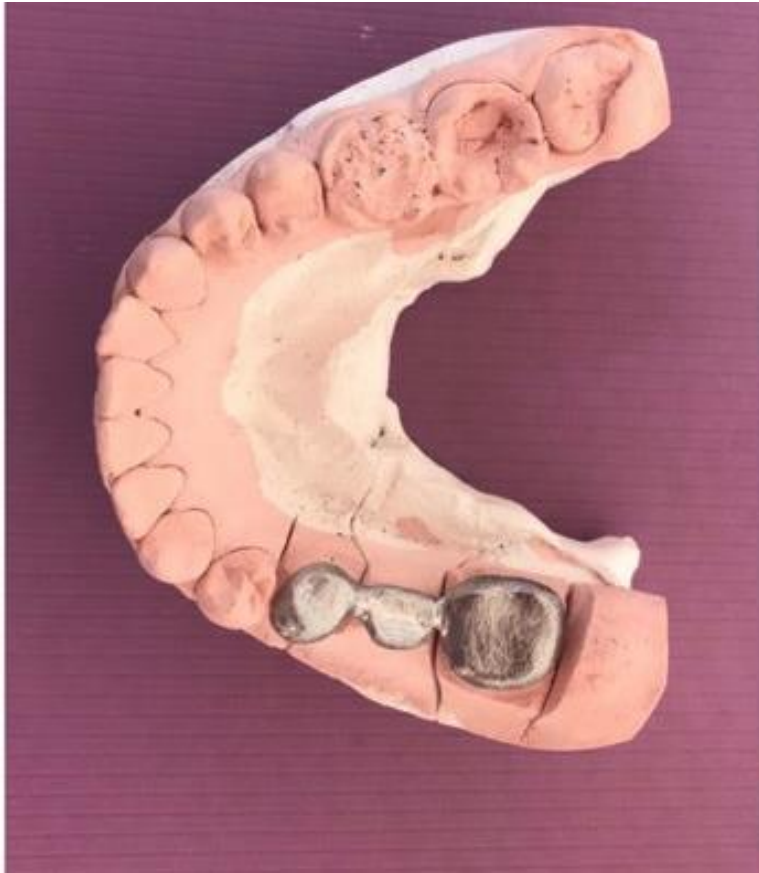
+ Final impression



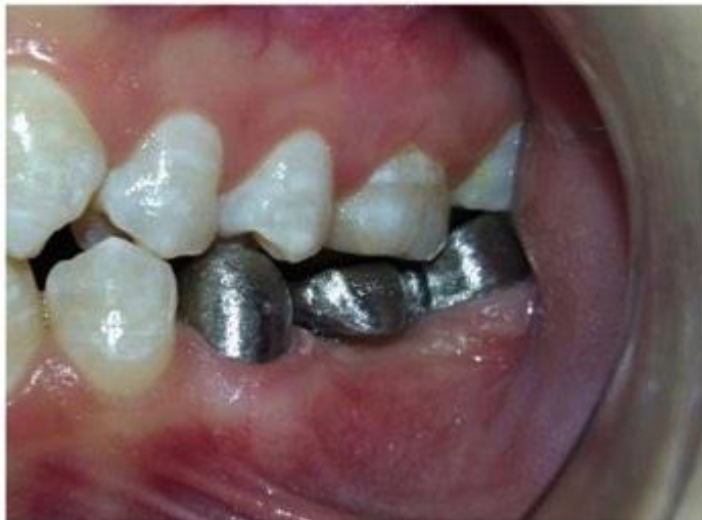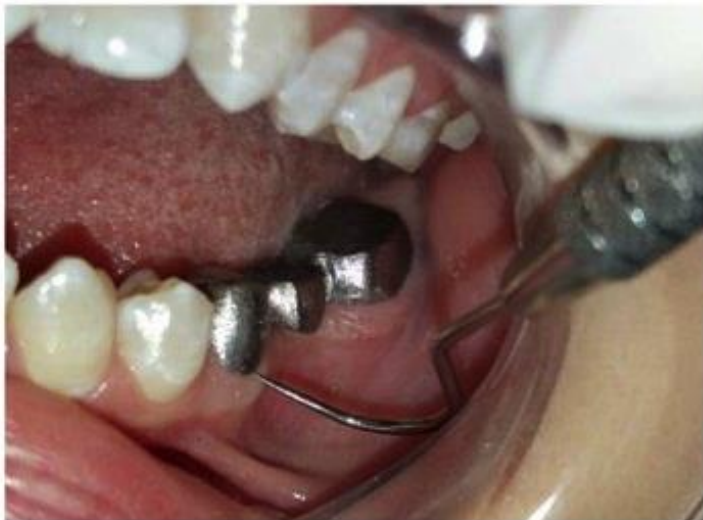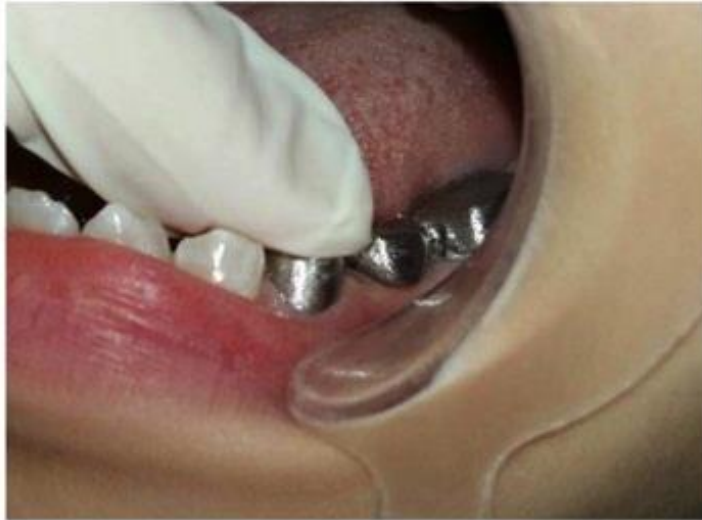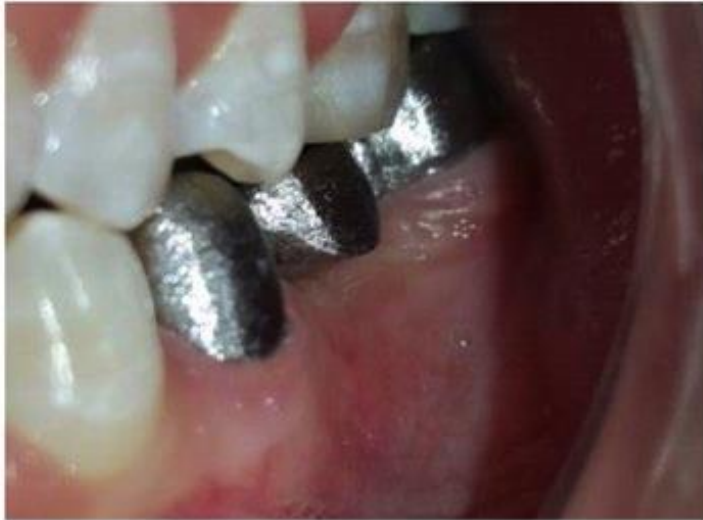+ Temporary Bridge



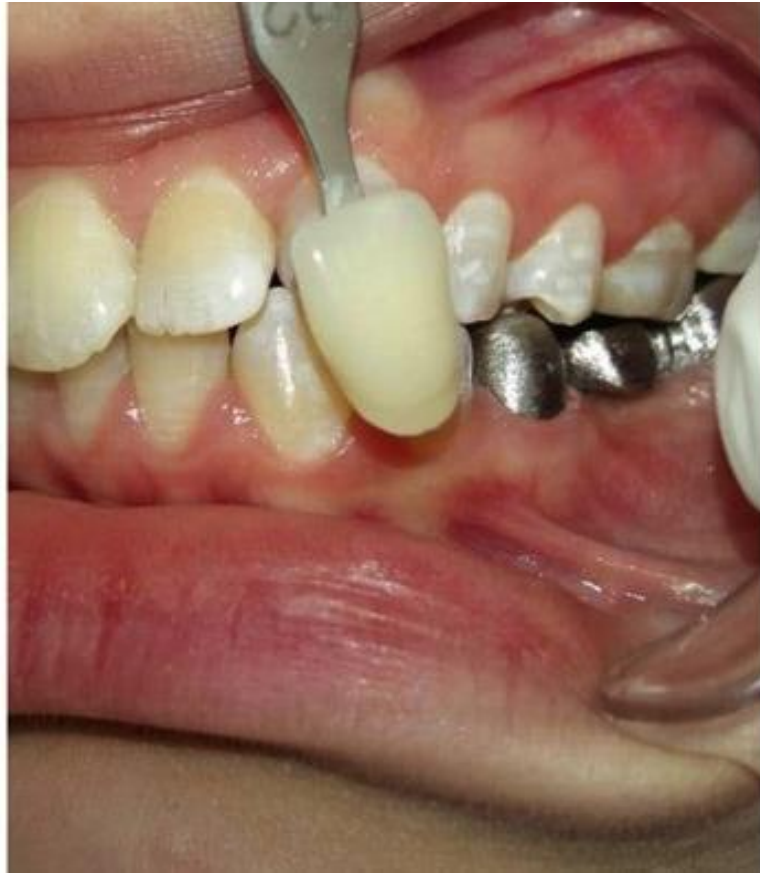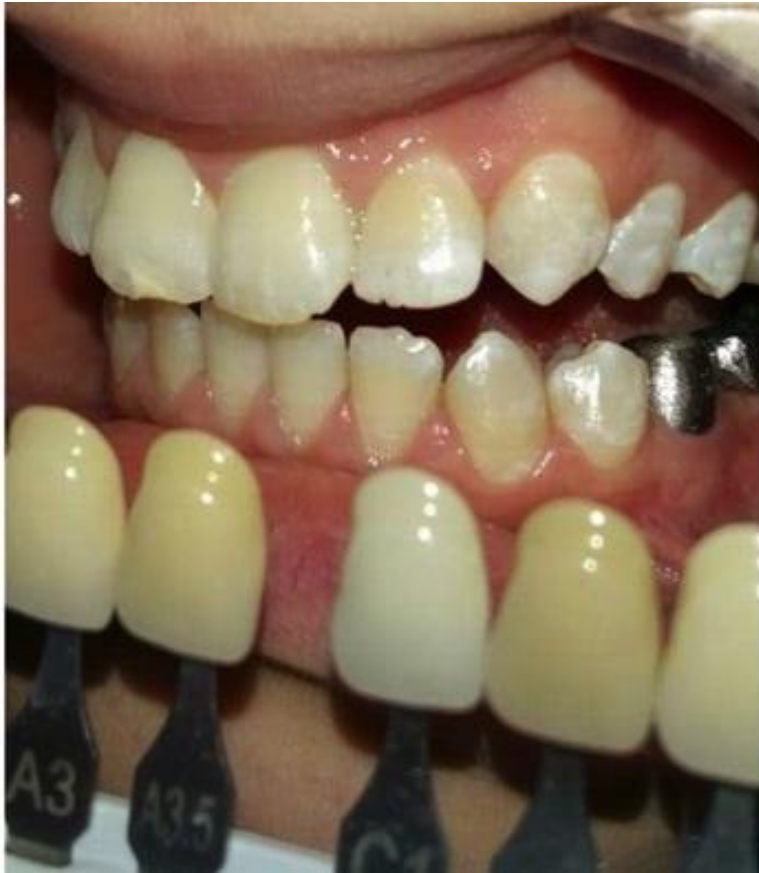+ Metal frame work



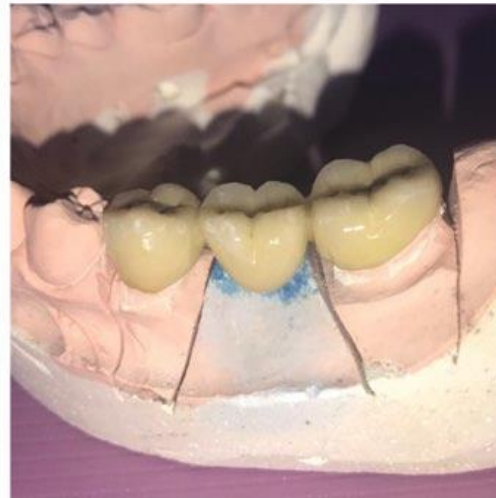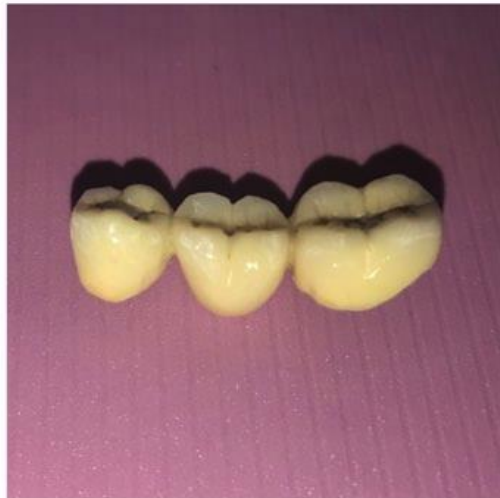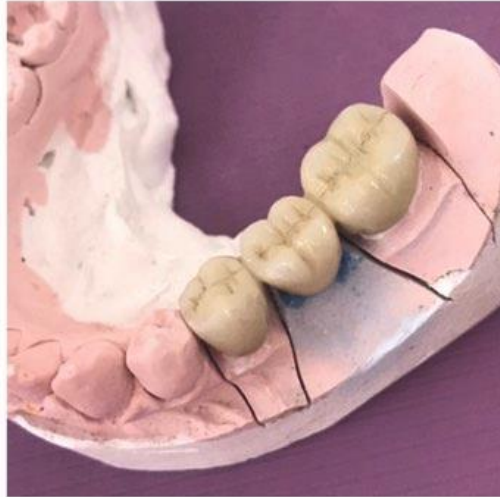
+ Checking and verification of metal framework



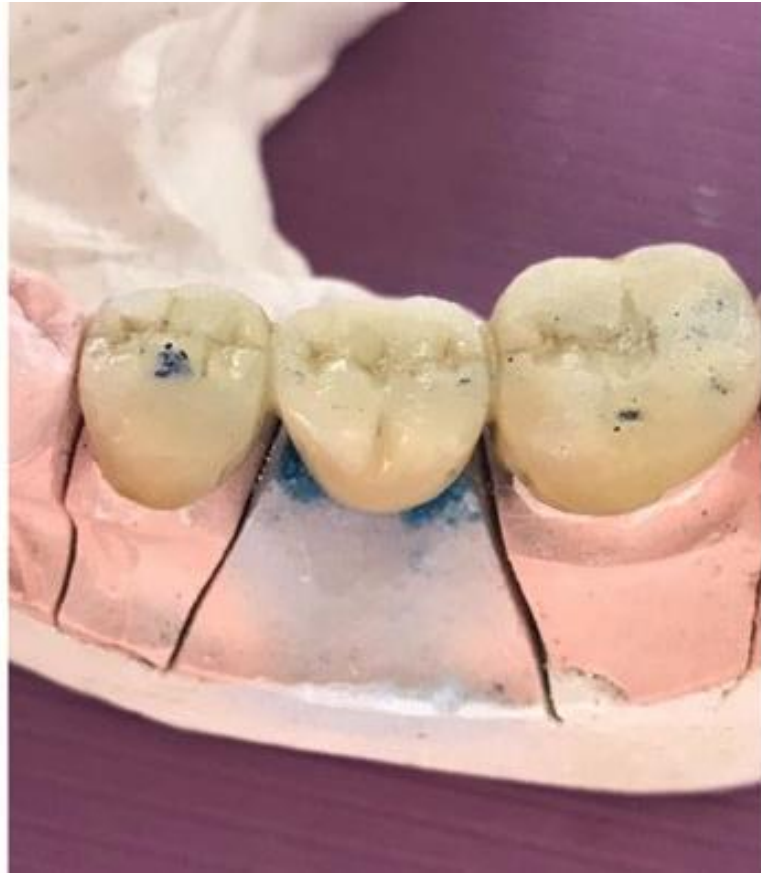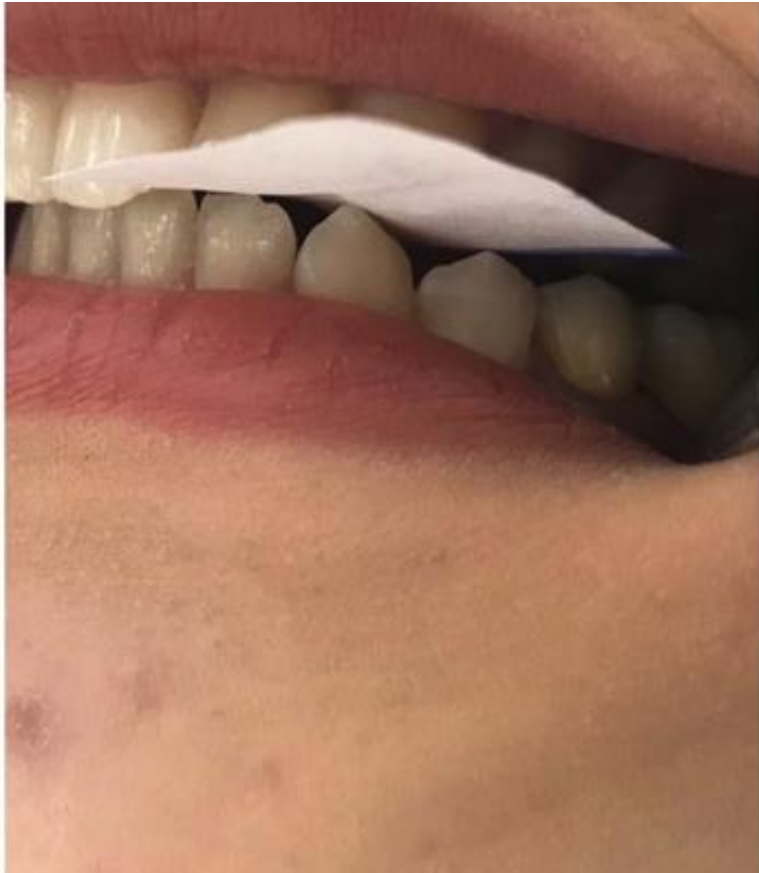+ Shade selection



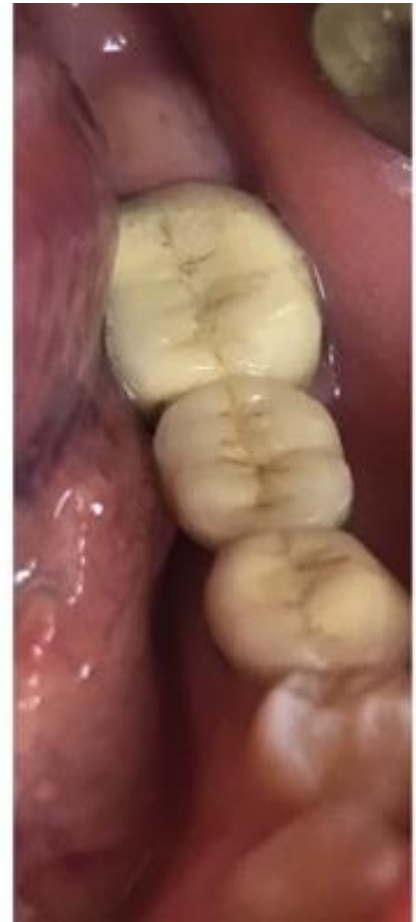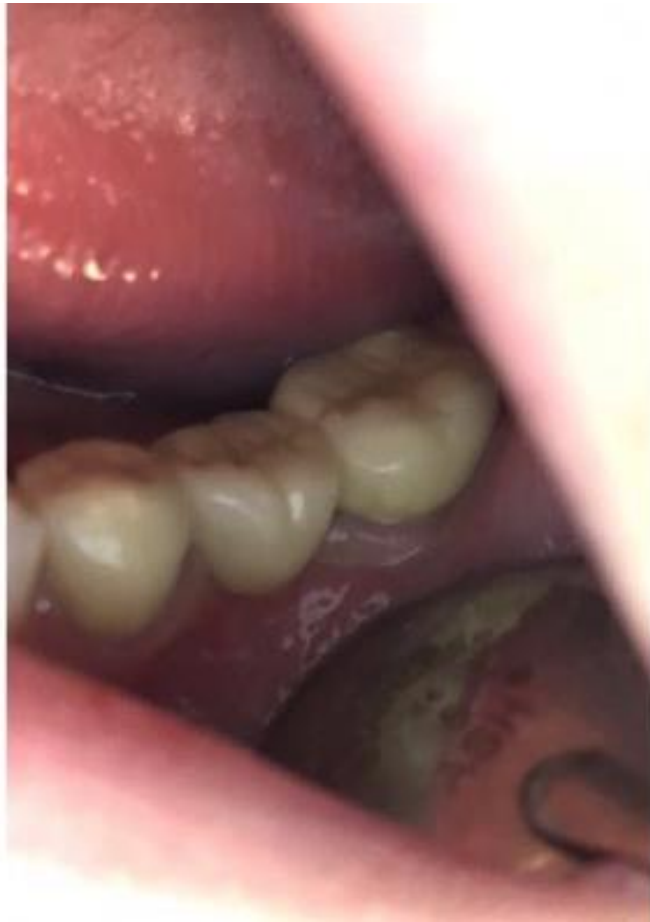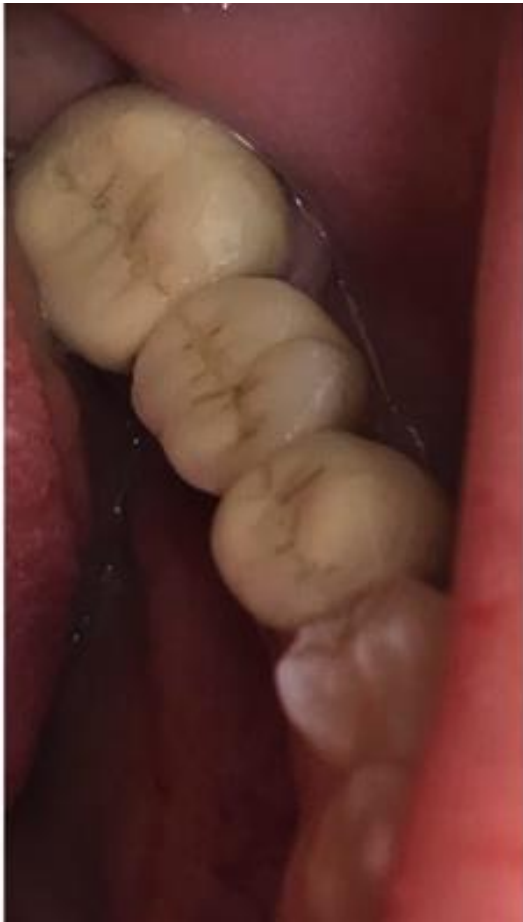+ PFM bridge with modified ridge lap pontic design



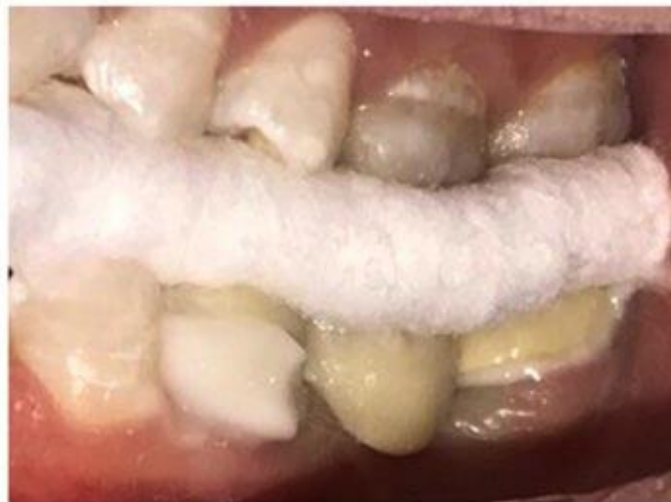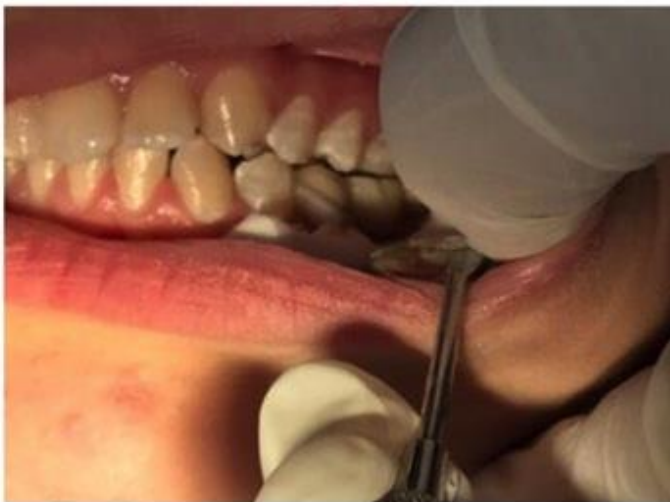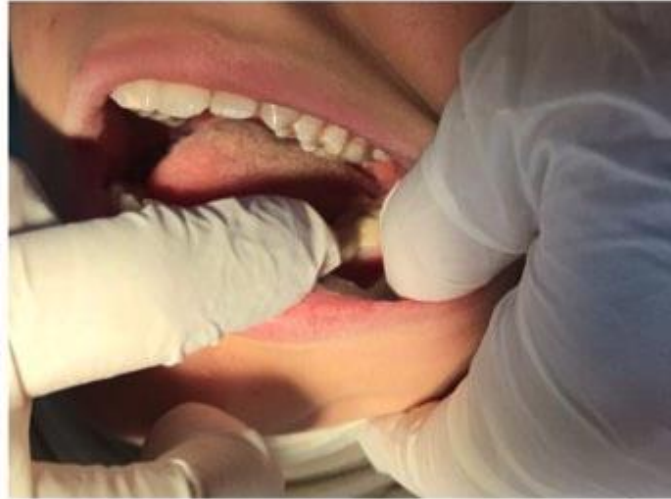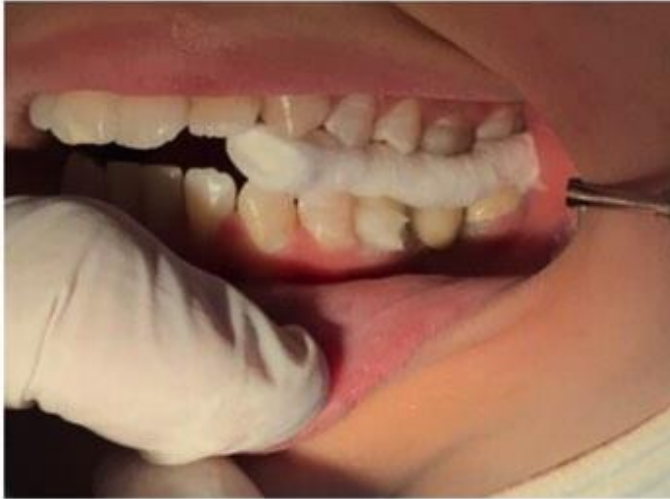+ Occlusal adjustment followed by reglazing



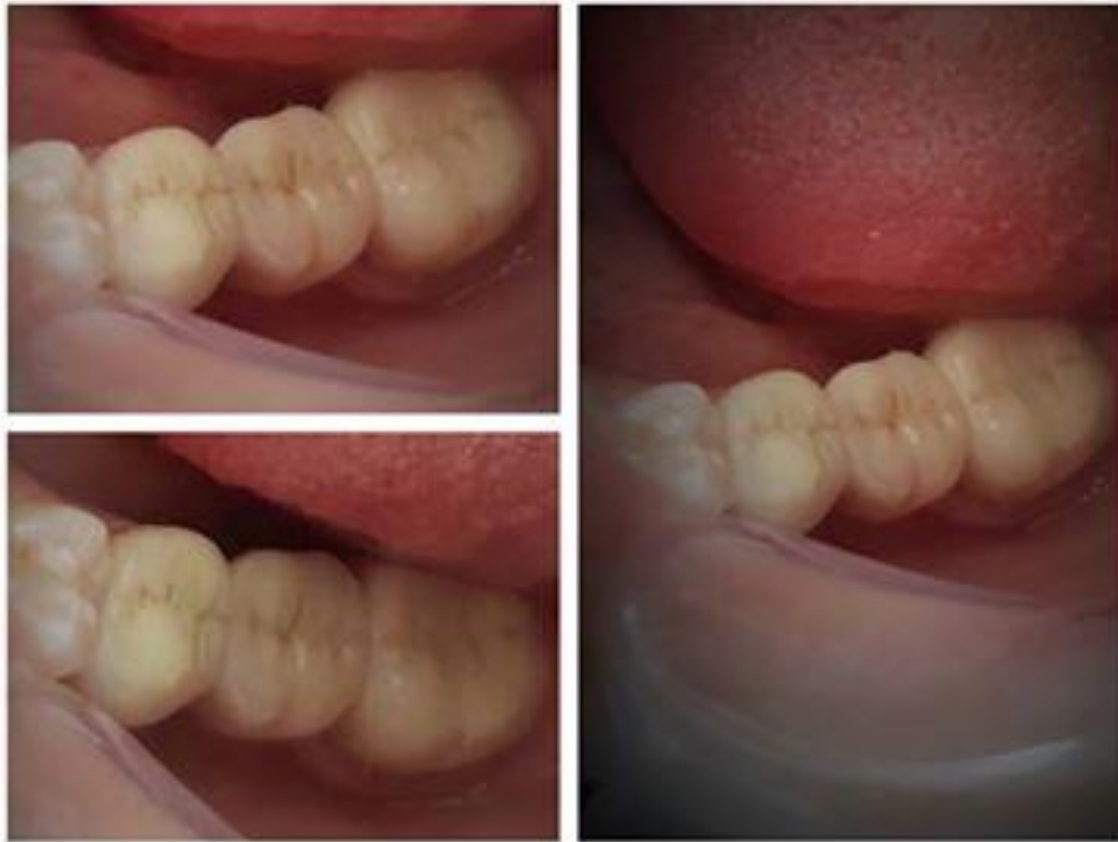+ trial cementation



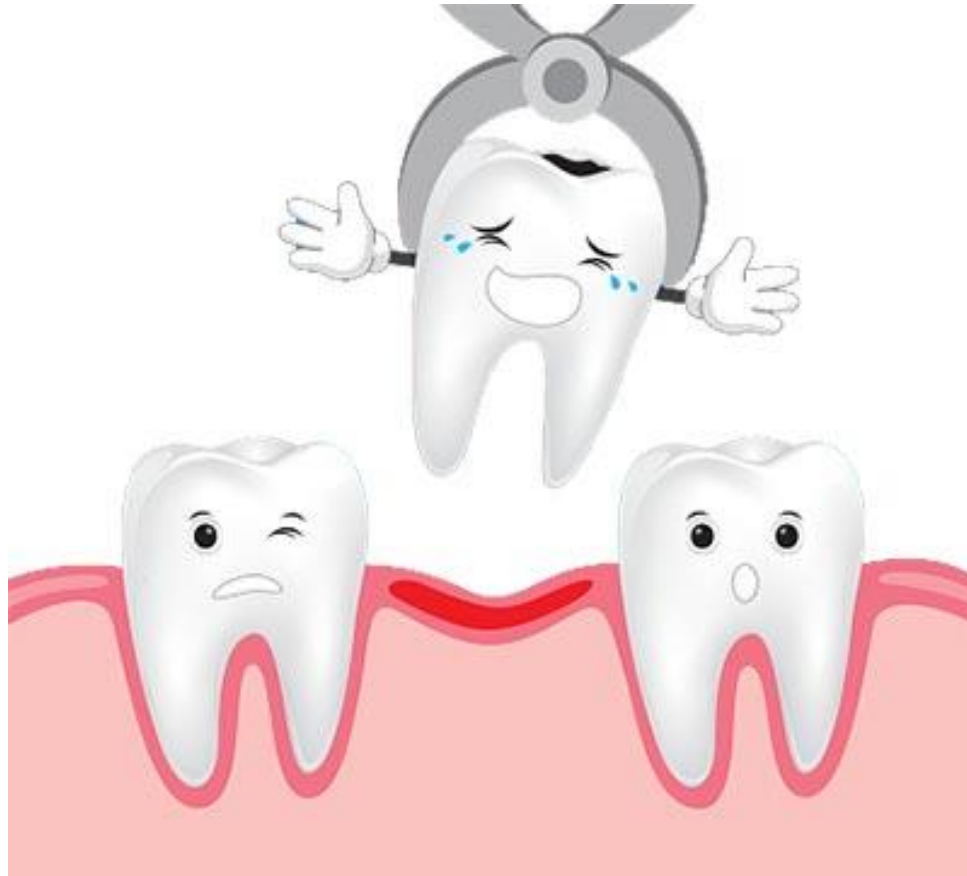+ Final cementation of the PFM bridge by using GIC



+ Reevaluation of phase III

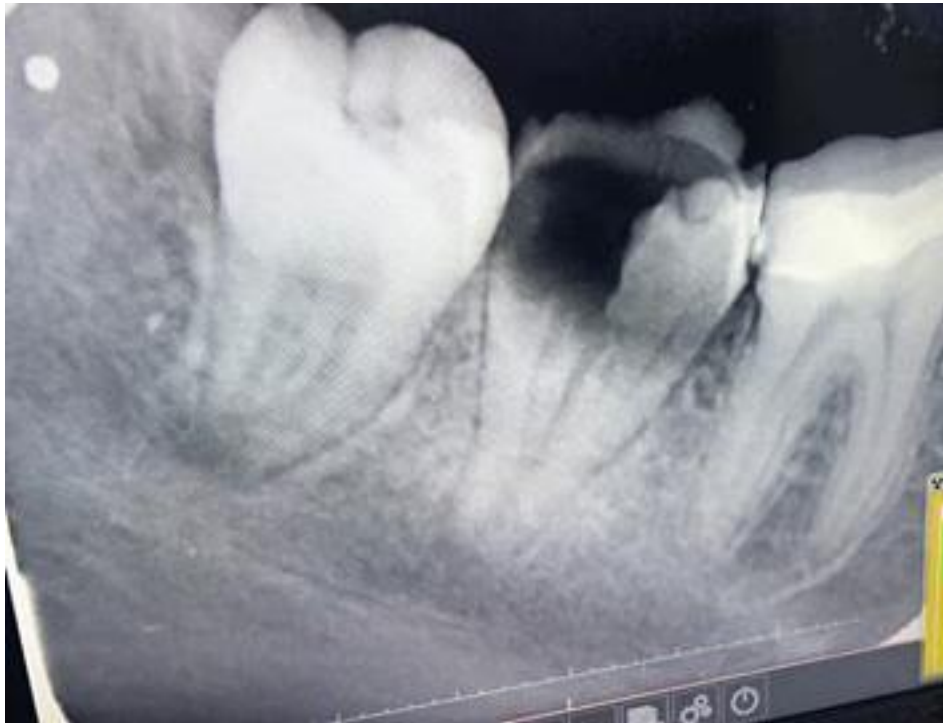

+ Phase II ...

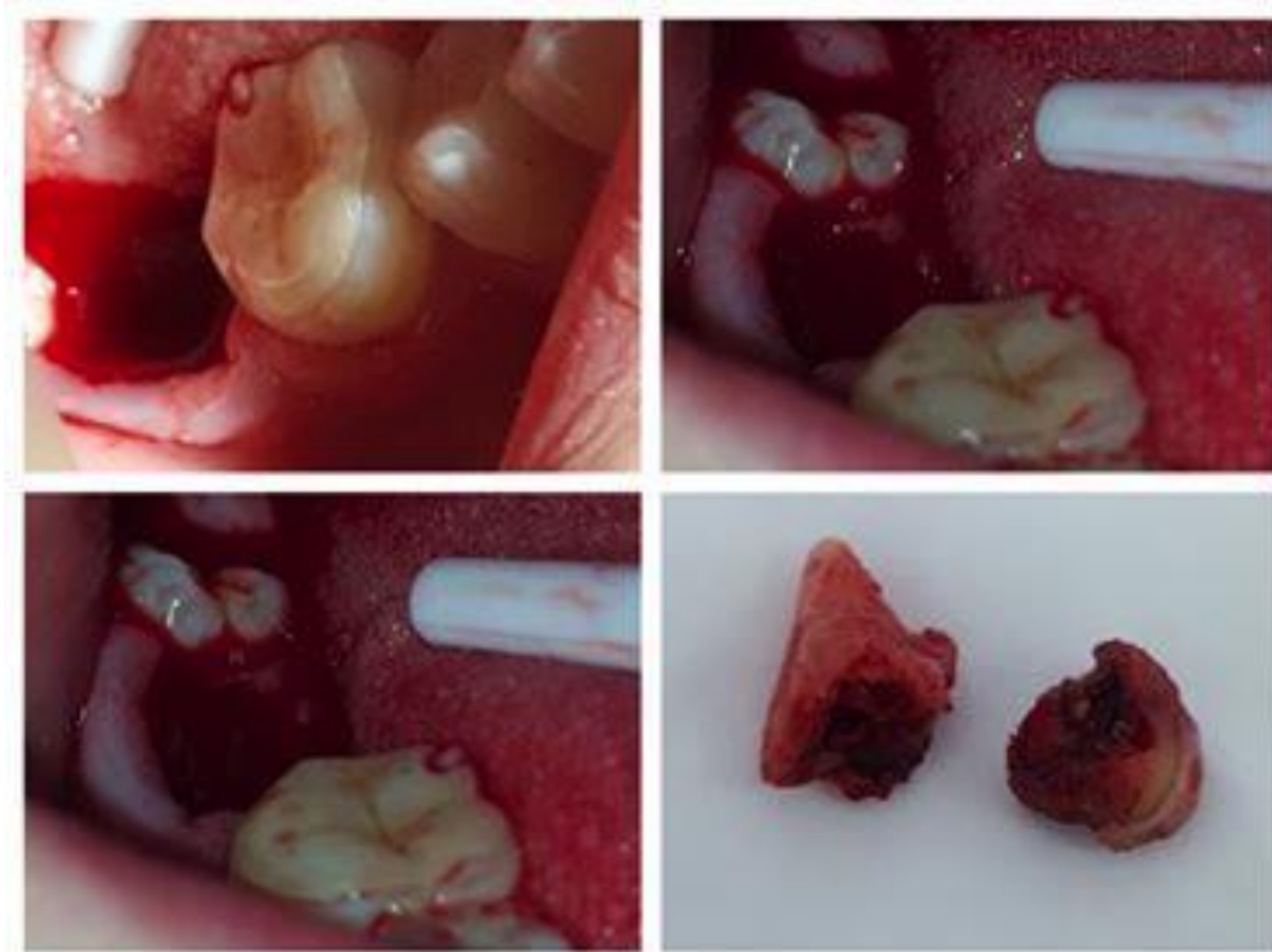



+ transplantation

- Extraction of lower right 3rd molar to replace the lower right 2nd molar.

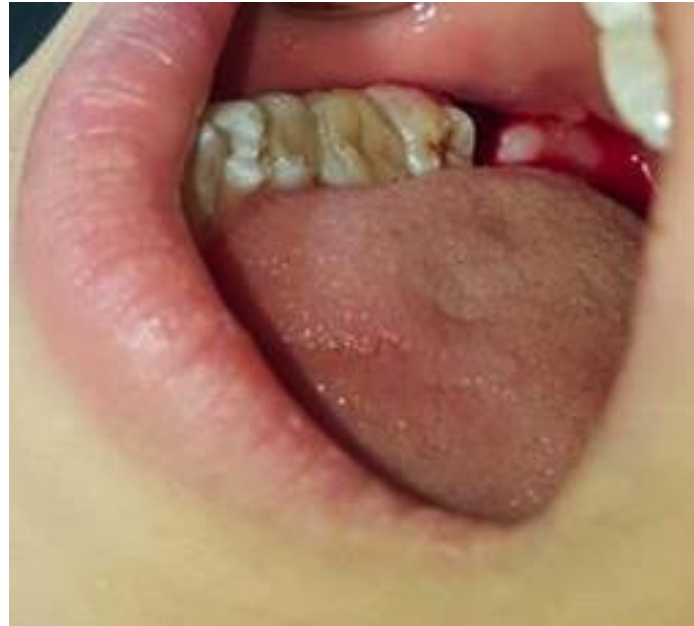
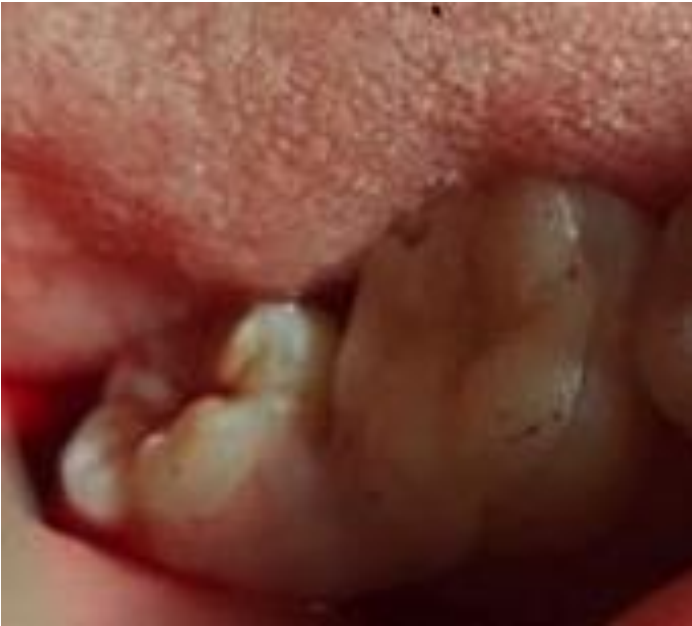
+ surgery – extraction of lower right 2nd molar

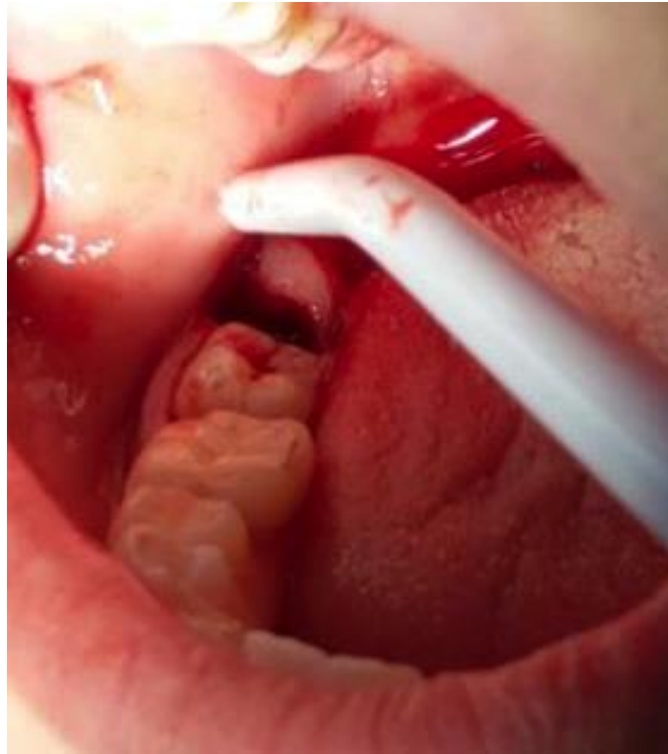



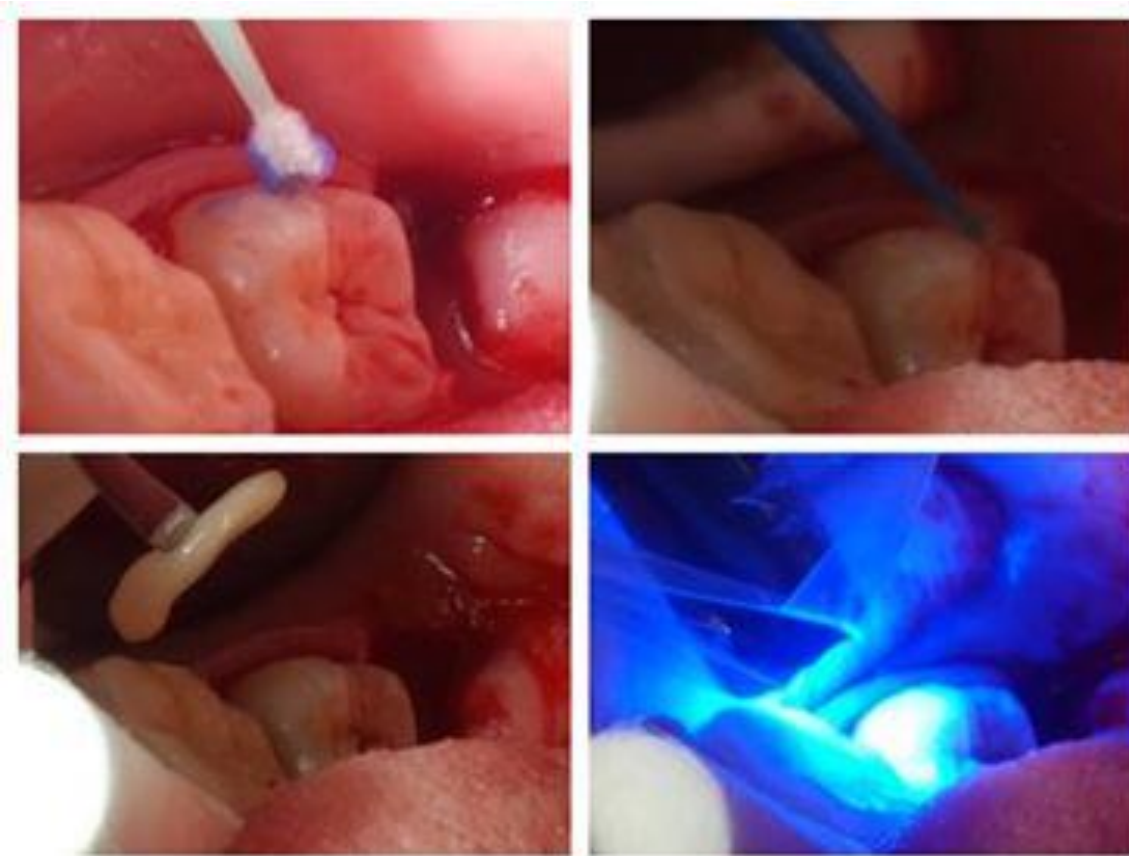
- + Extraction of the lower right 3rd molar and transplant it in the lower right 2nd molar socket



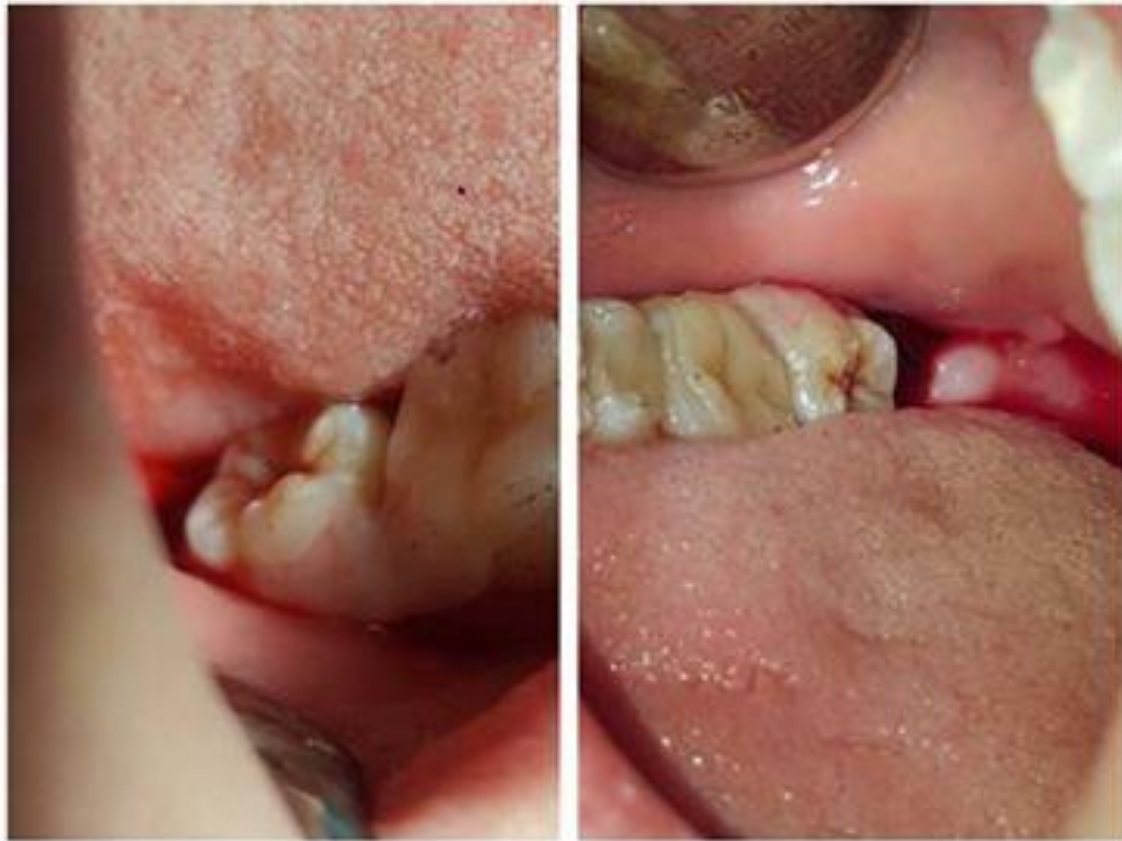- + Extraction of the lower right 3rd molar and transplant it in the lower right 2nd molar socket



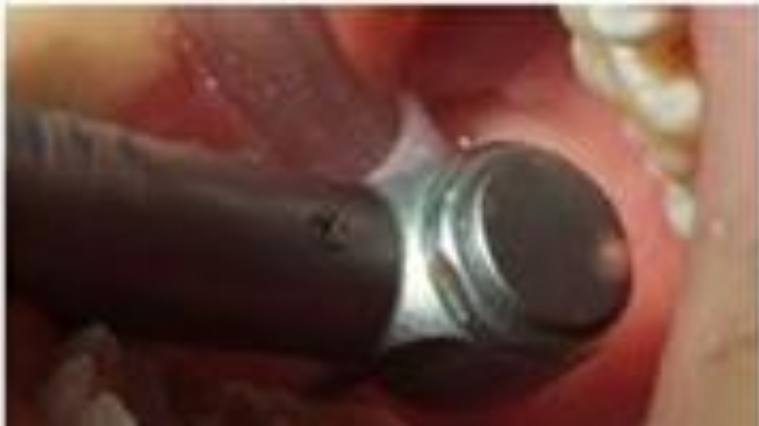
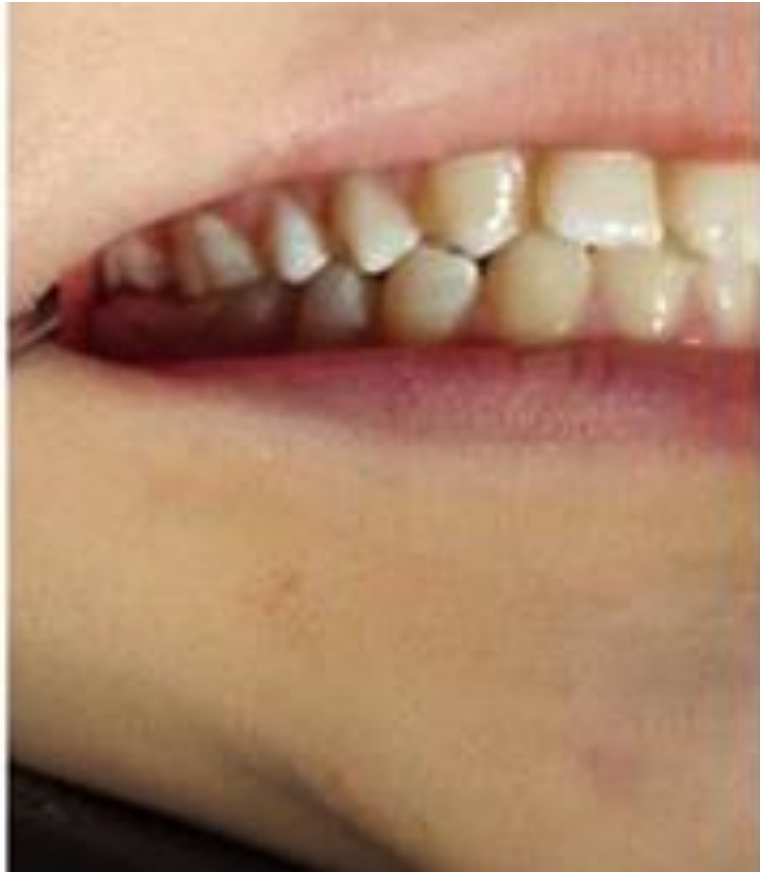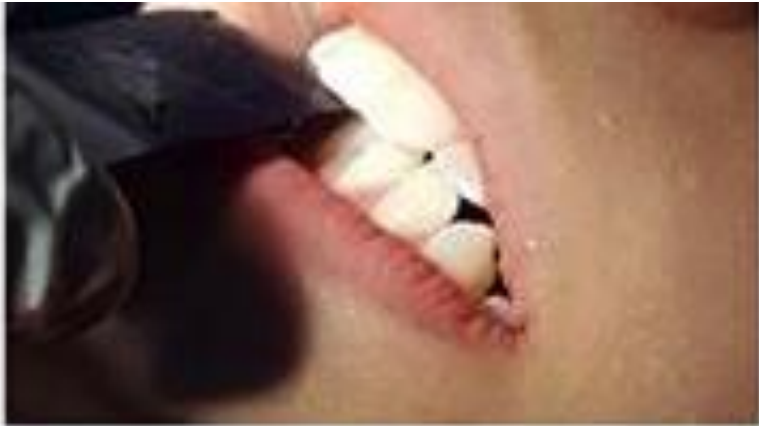+ Splinting with composite



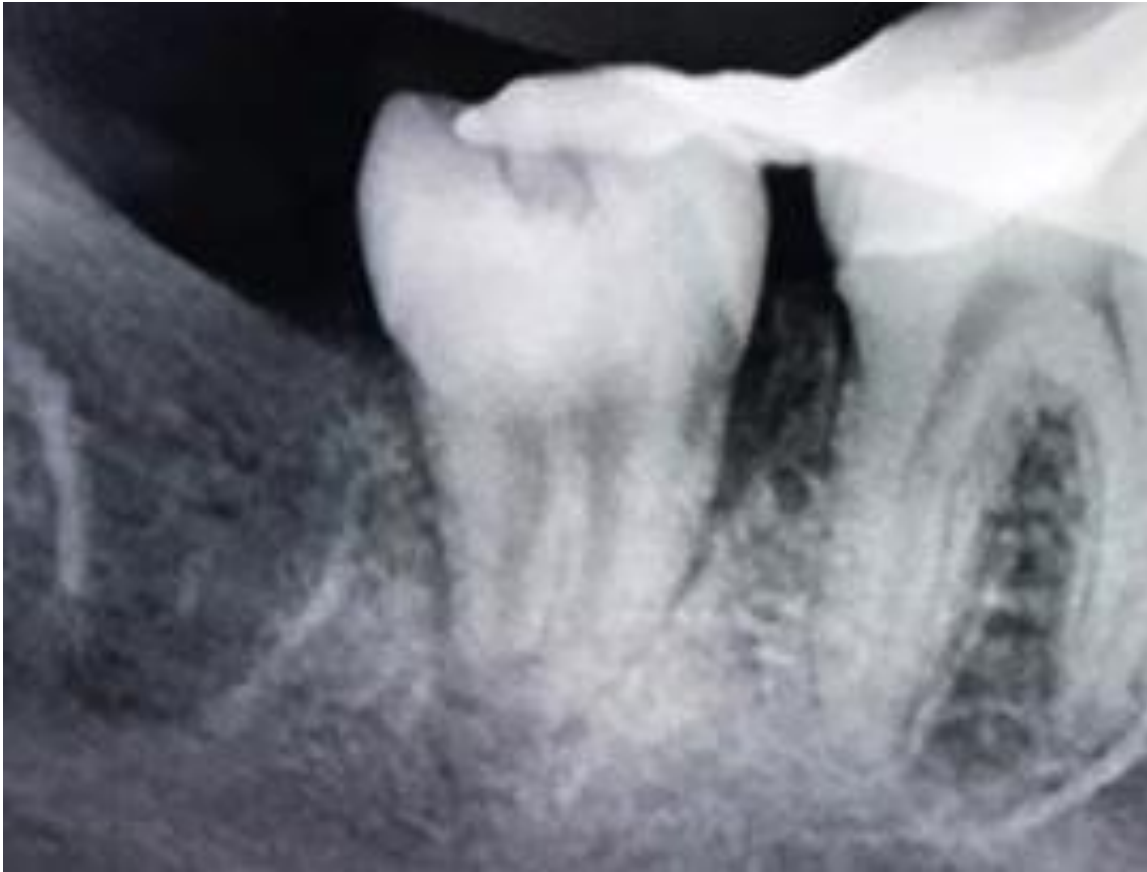
+ Suturing



+ Occlusal adjustment

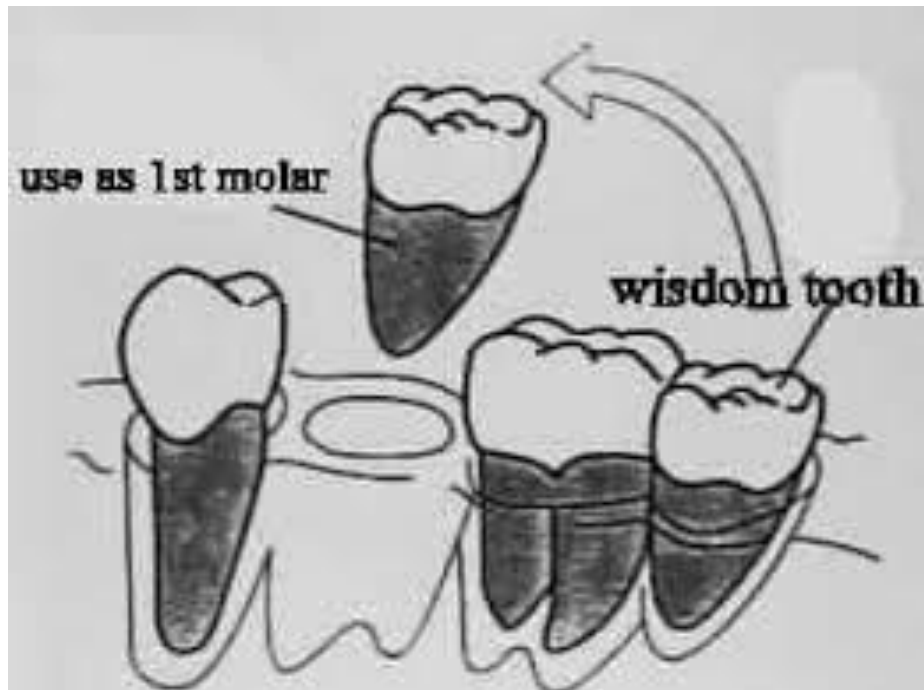


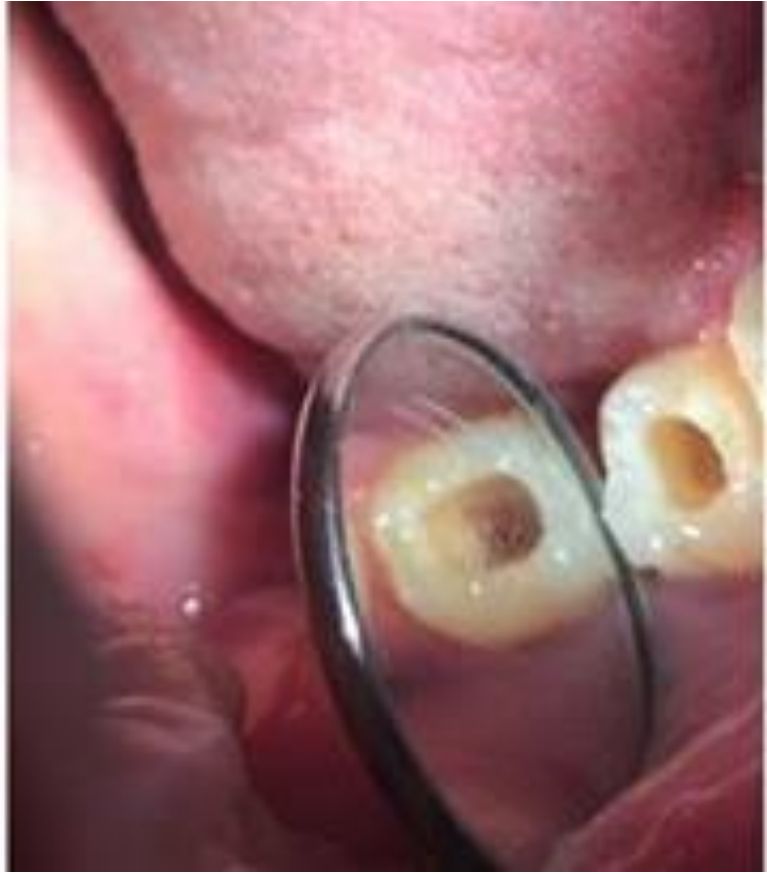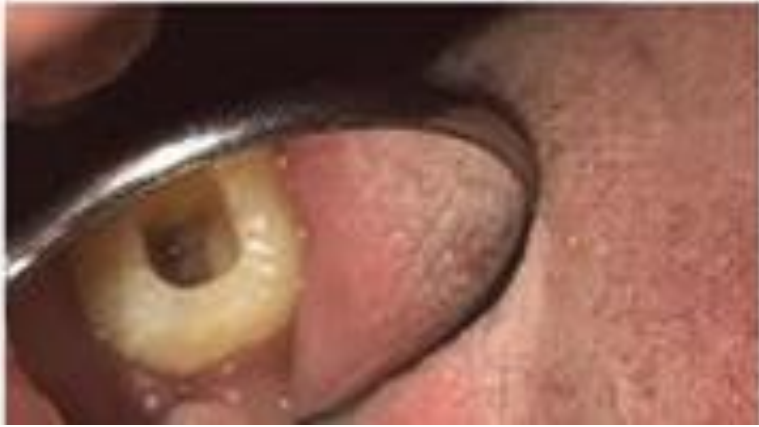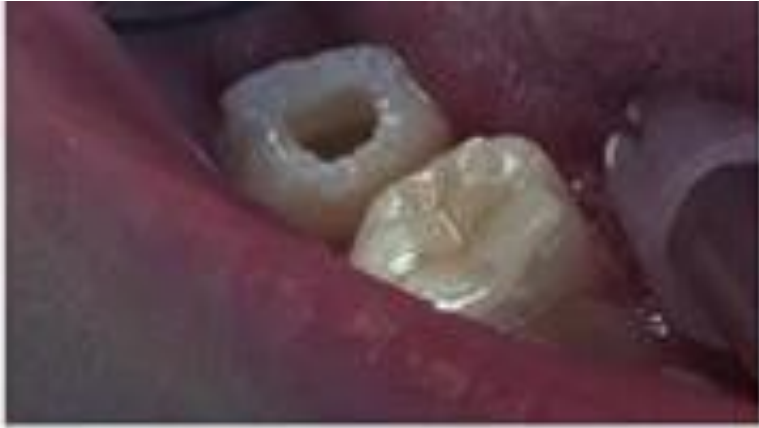+ Post surgical radiograph



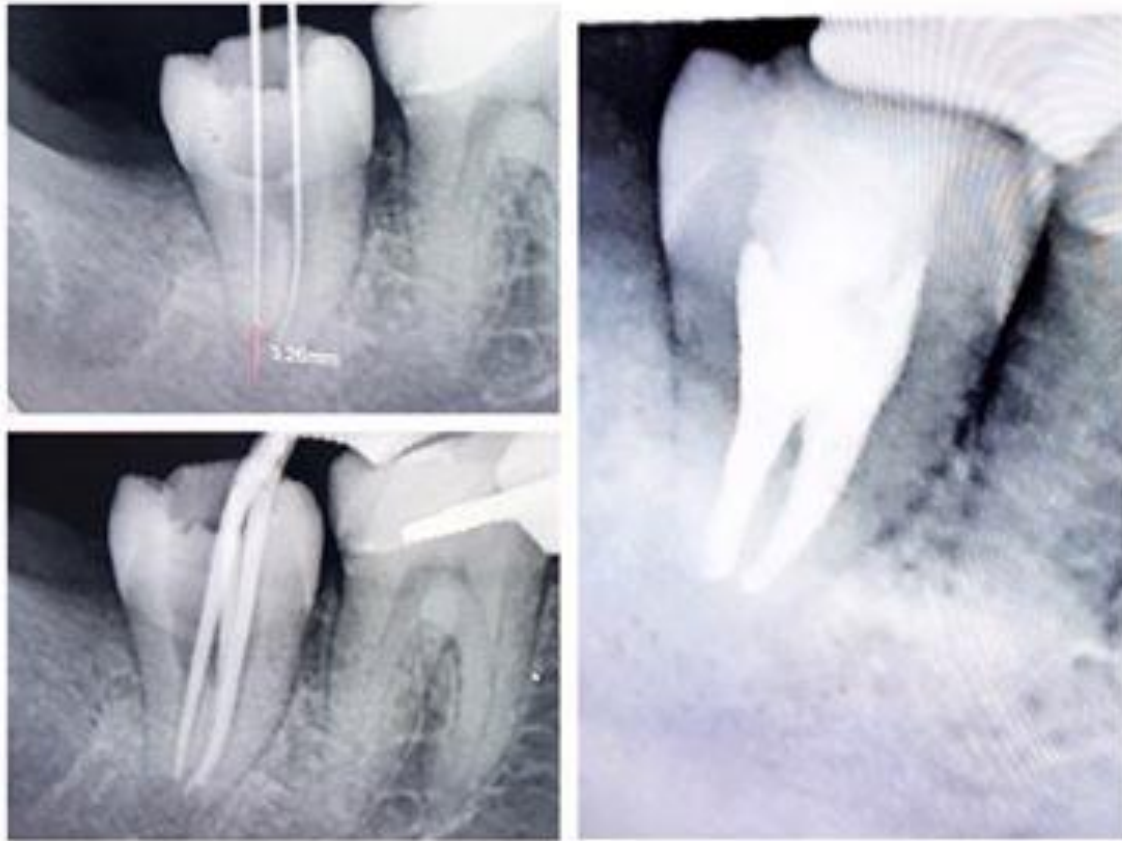+ After three weeks later

- There is **no** pain , neither swelling nor tenderness.
- No mobility .





+ Root canal treatment was done

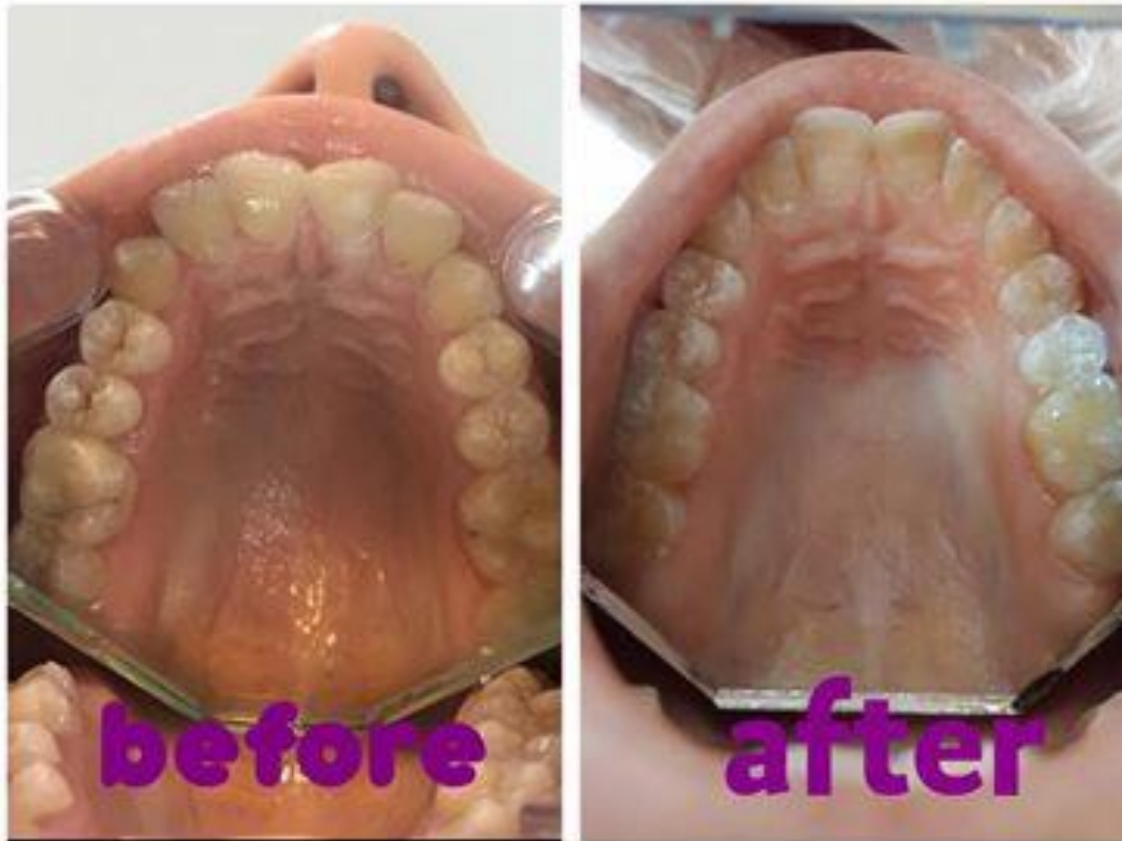

+ Phase IV : reevaluation

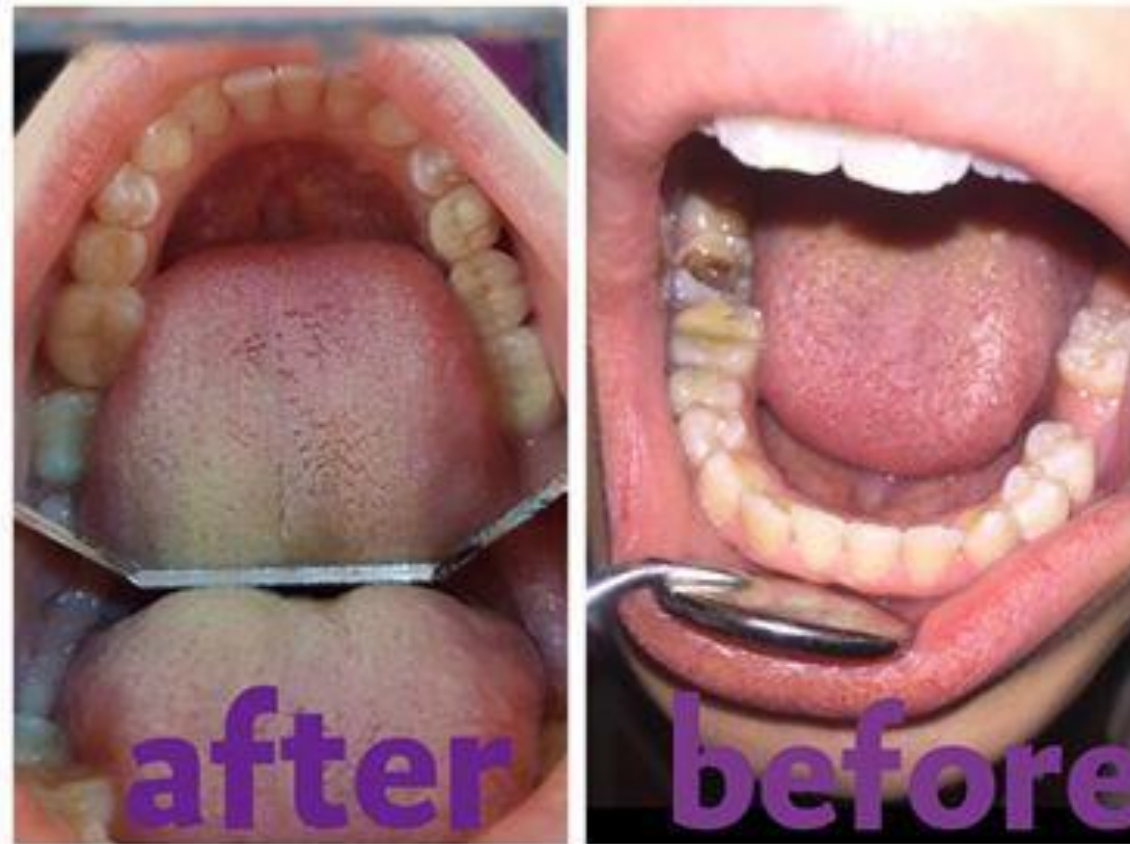- Gingival health within normal , no signs of inflammation or active disease.
- There are No complications related to FPD or the onlay



+ Before and after treatment



+ Before and after treatment





Thank You

